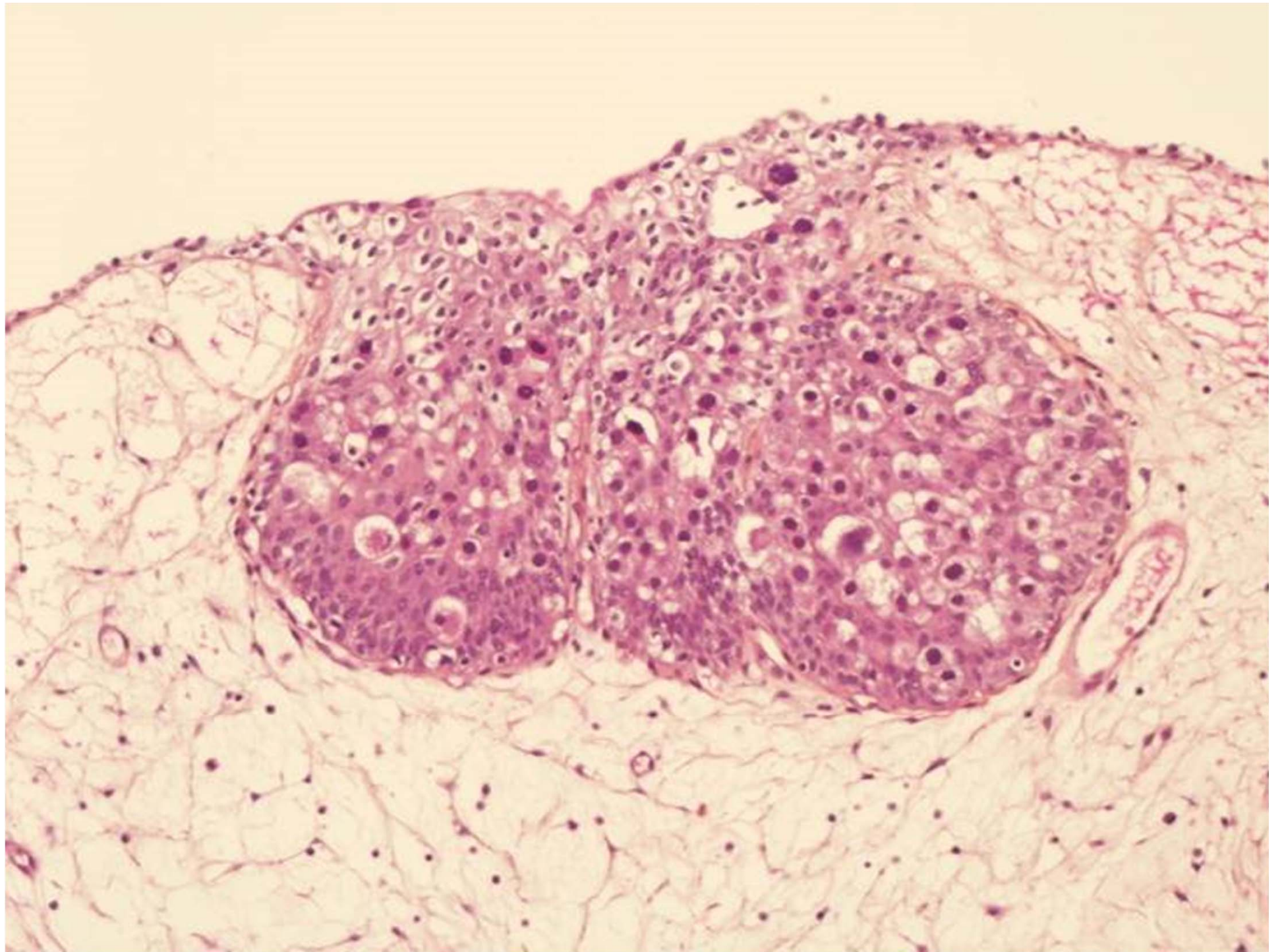
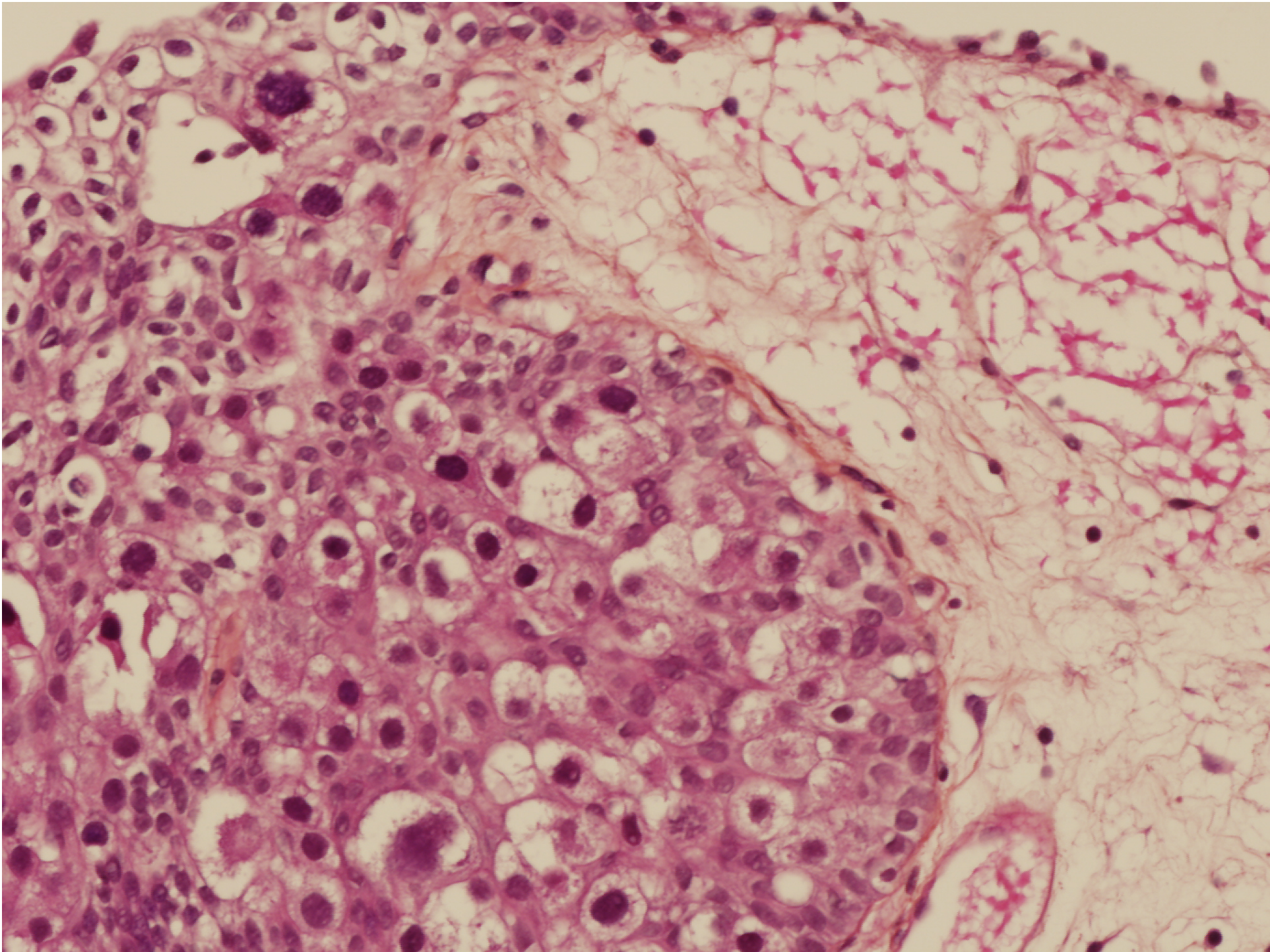
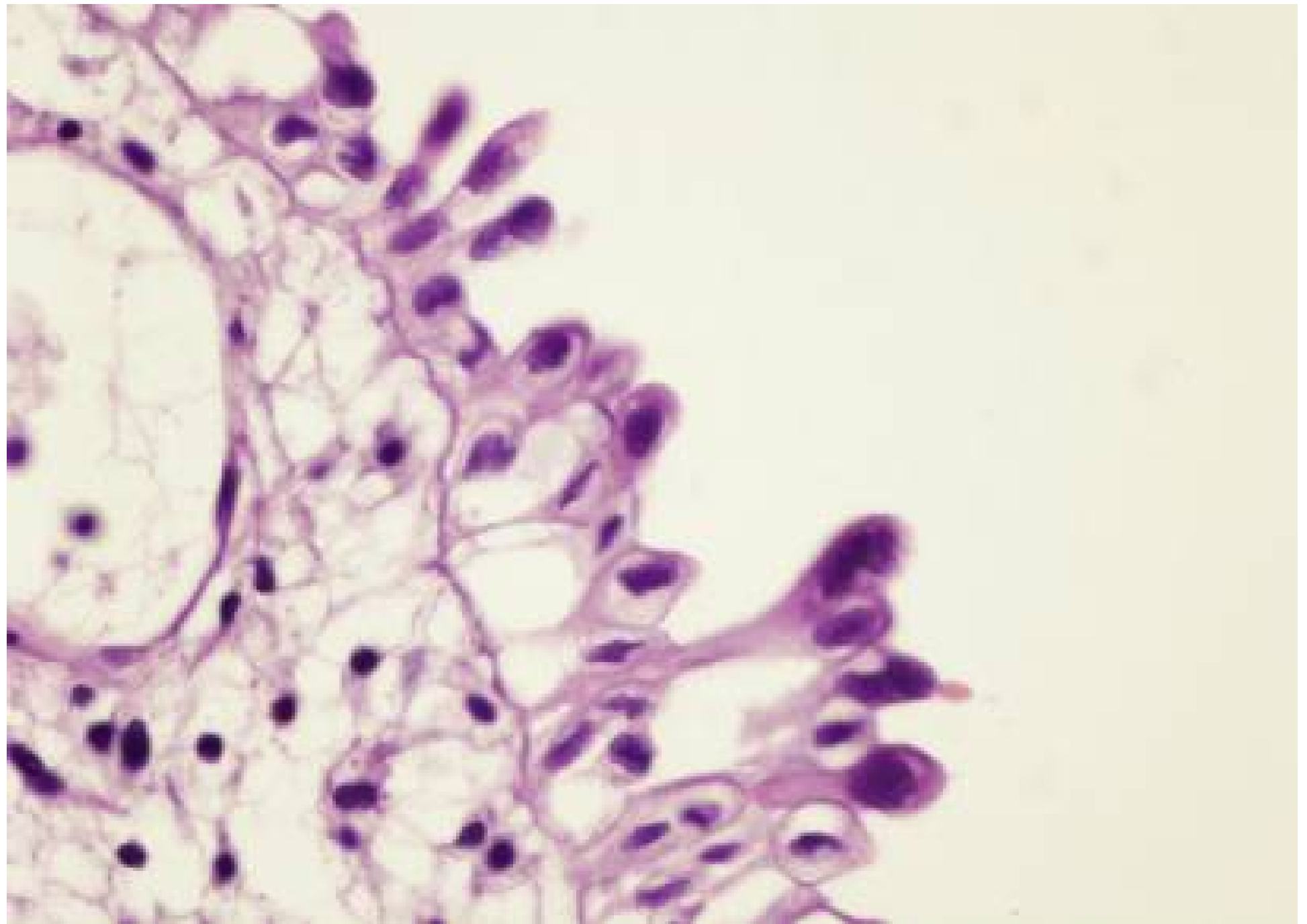


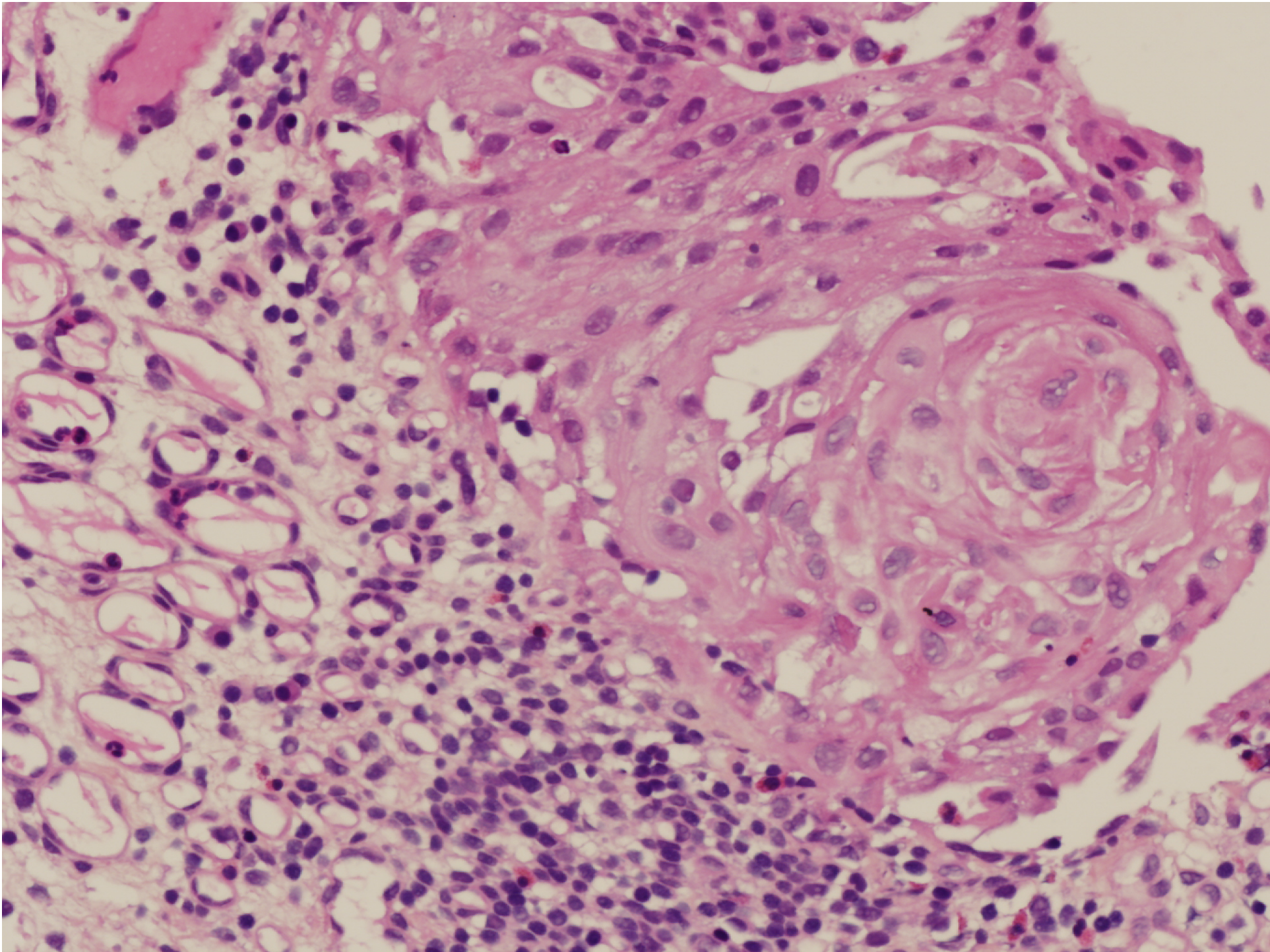
Flat lesions

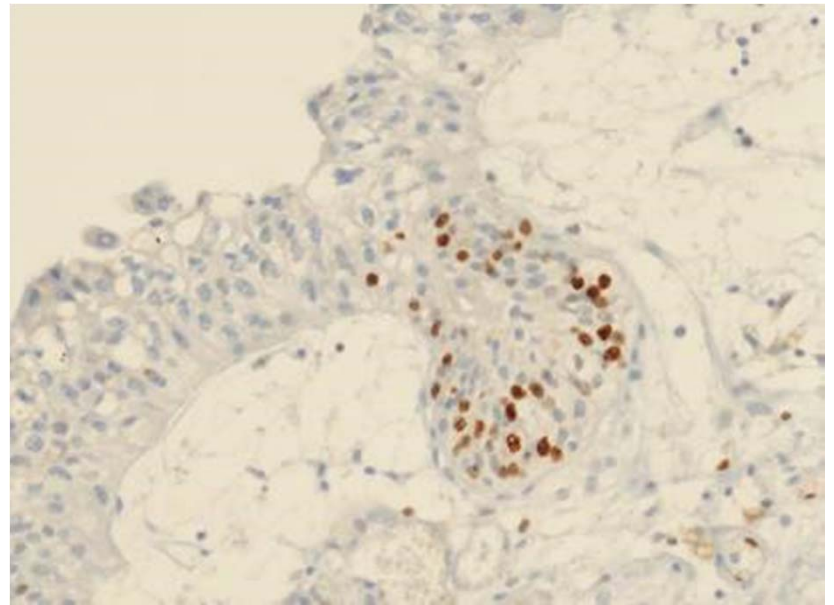
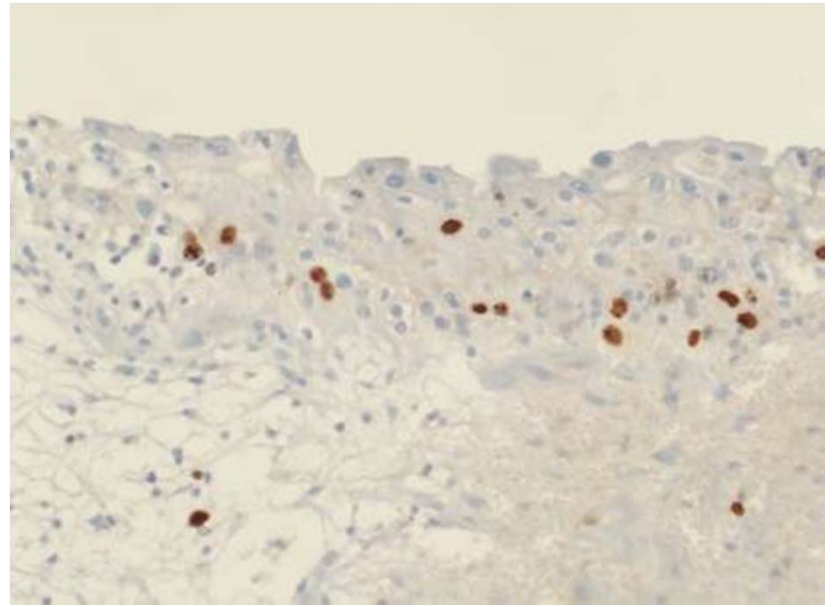
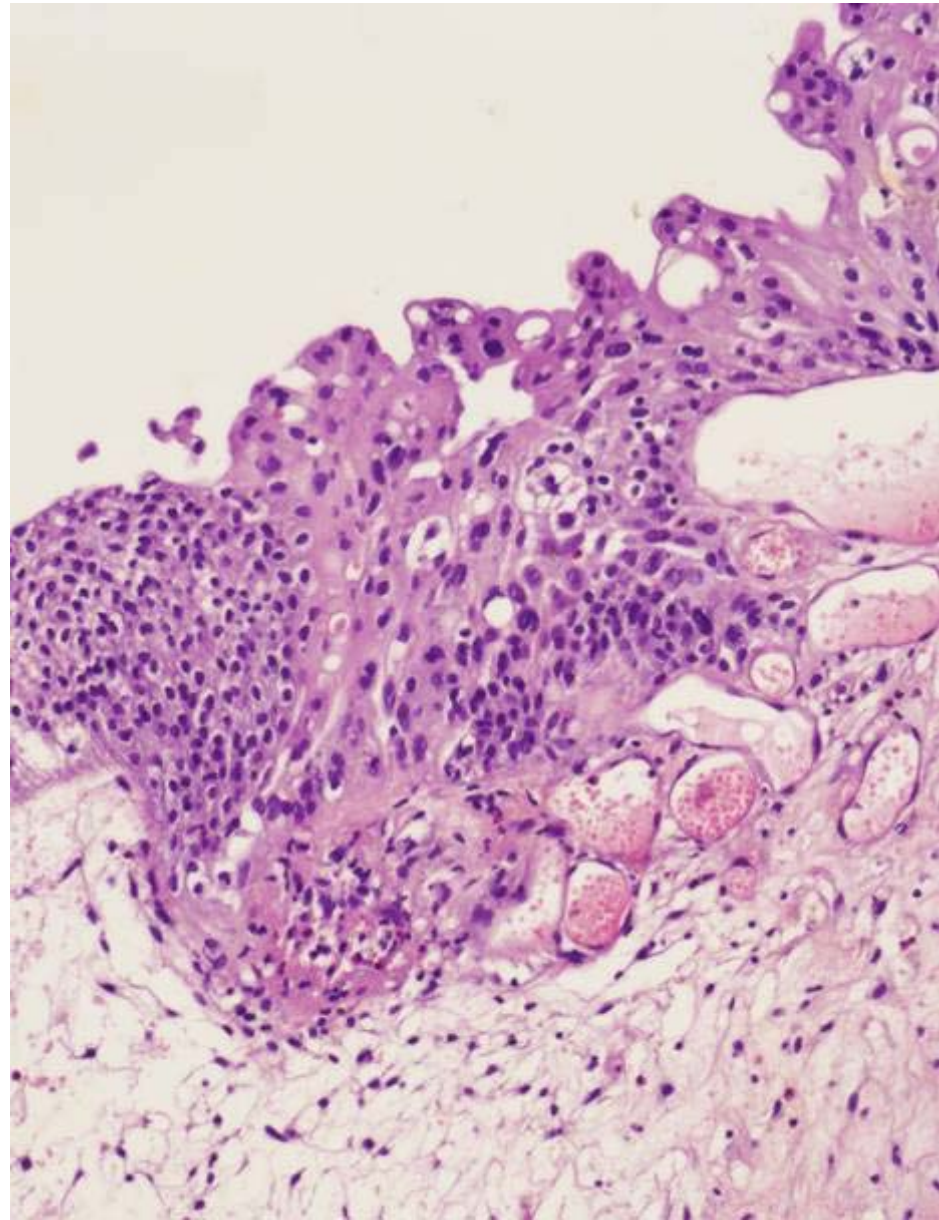


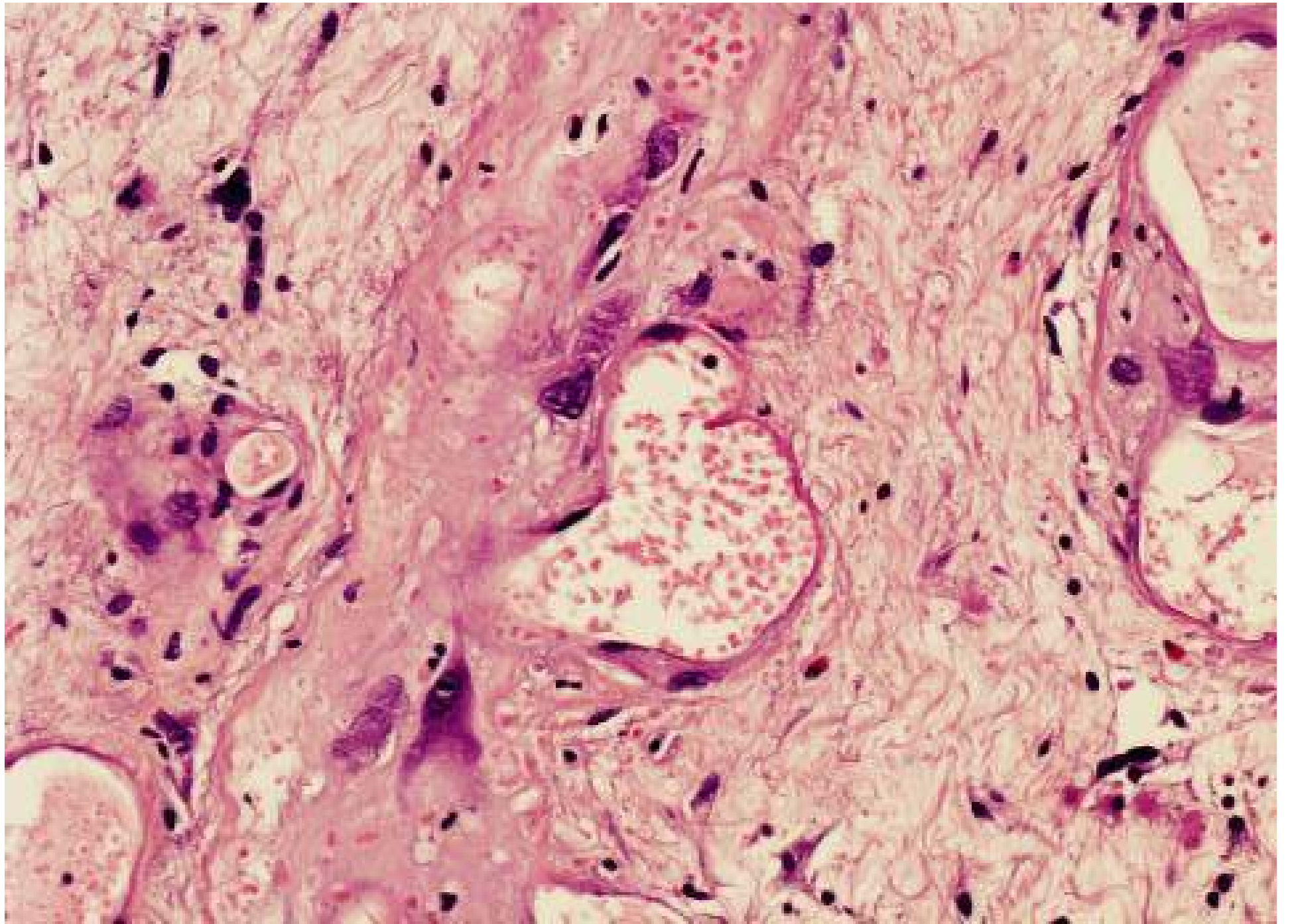


CIS in Von Brunn nest

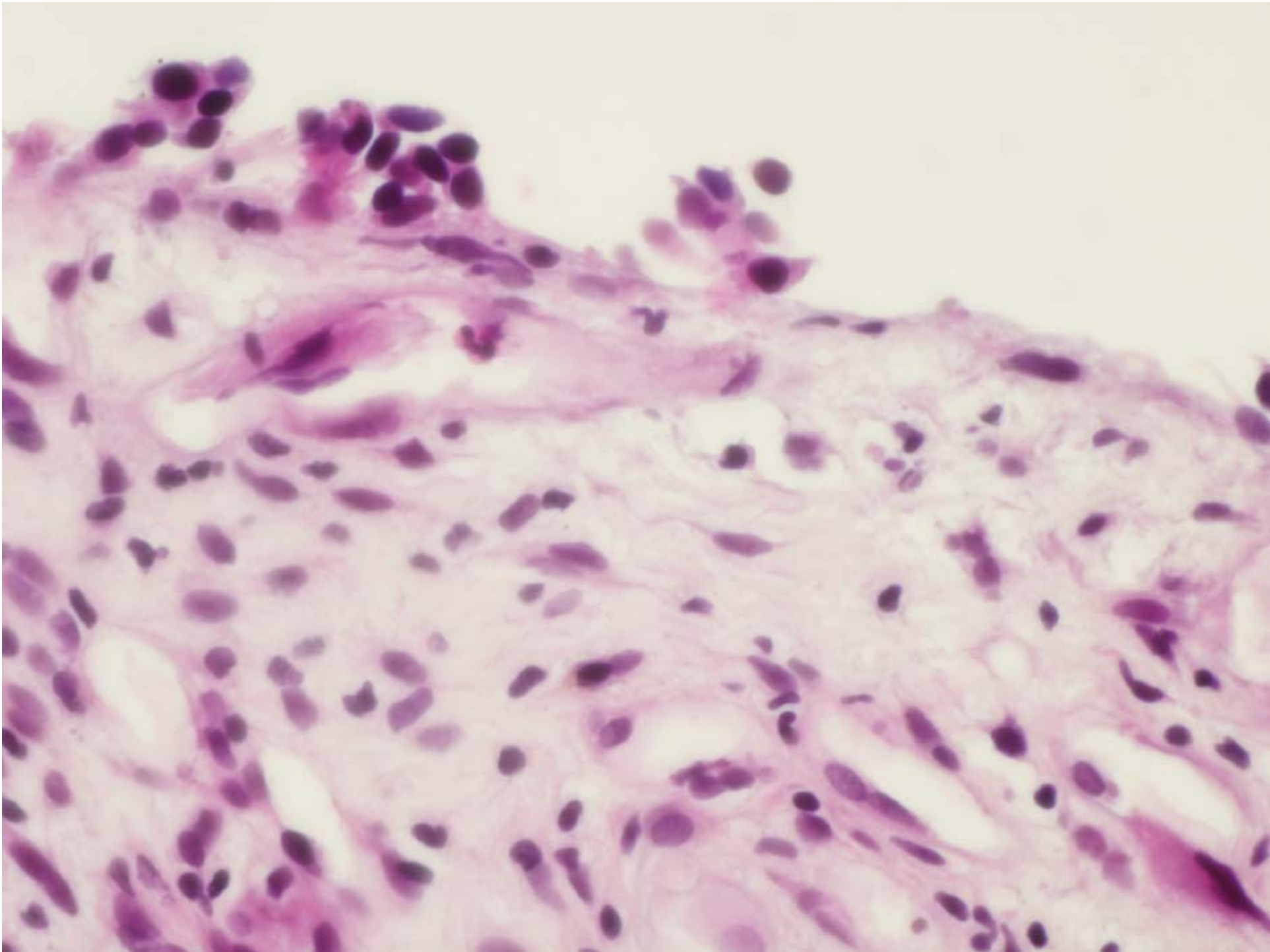




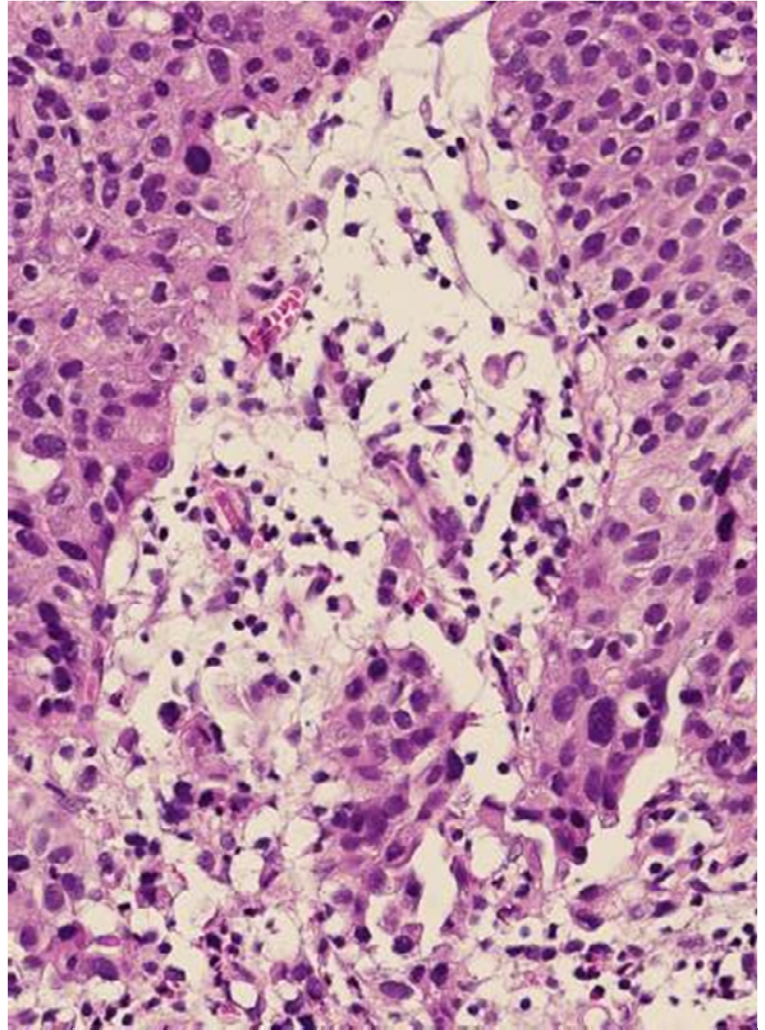
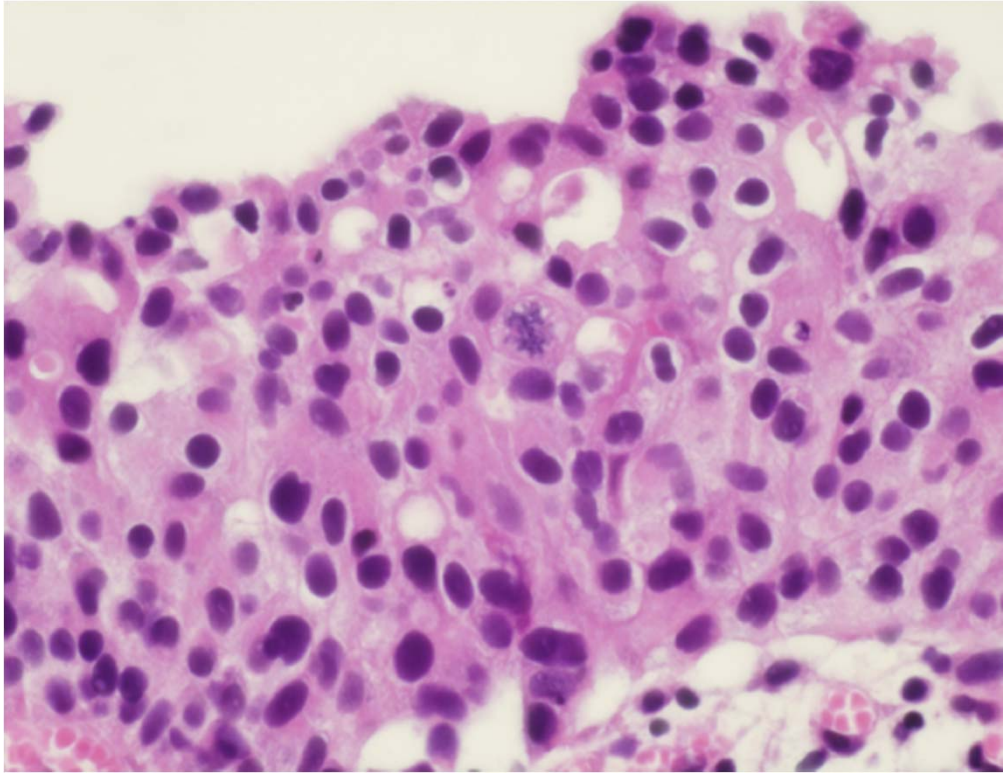




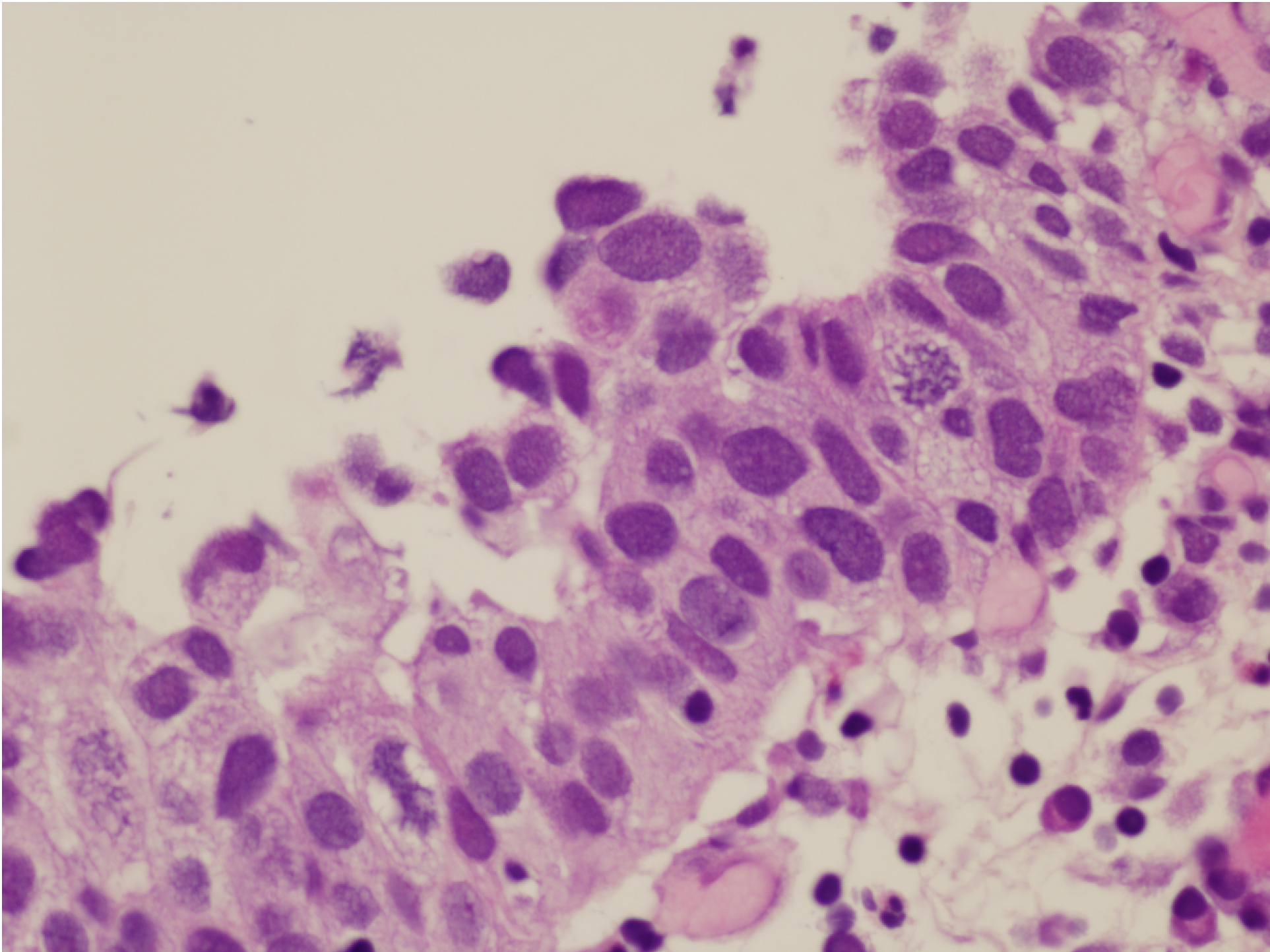
Cystitis post-radiation



6 months later, new TURB

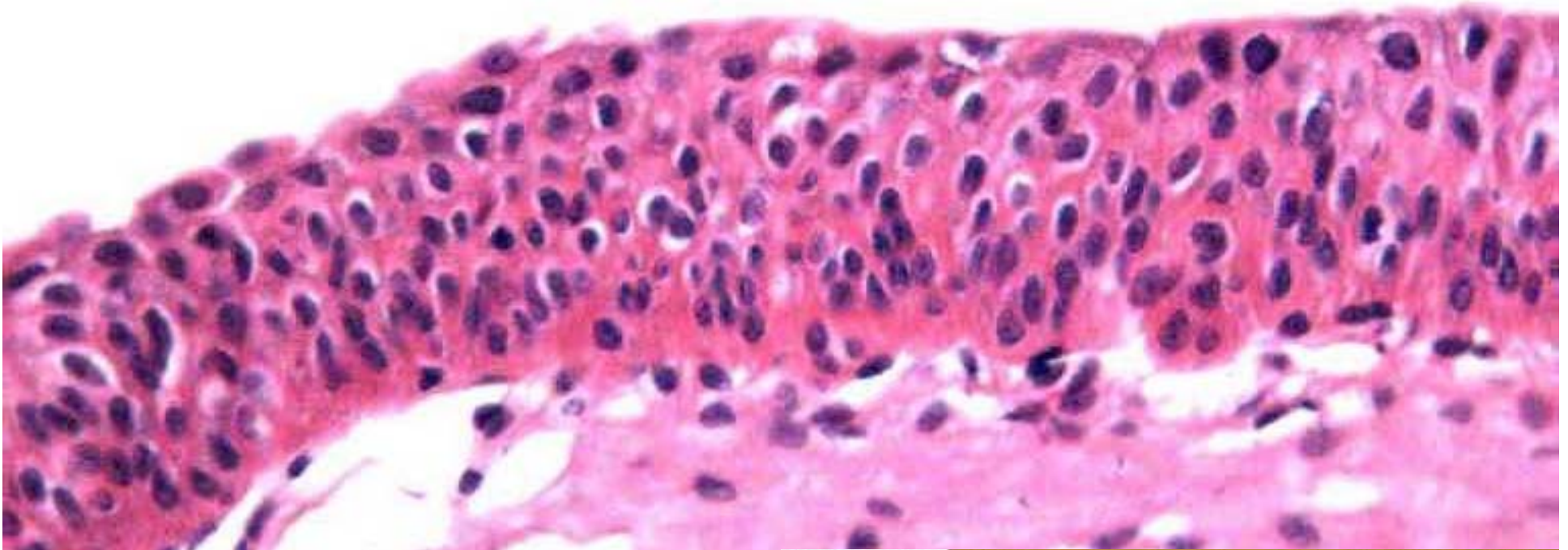


Carcinoma high grade T1 + Tis



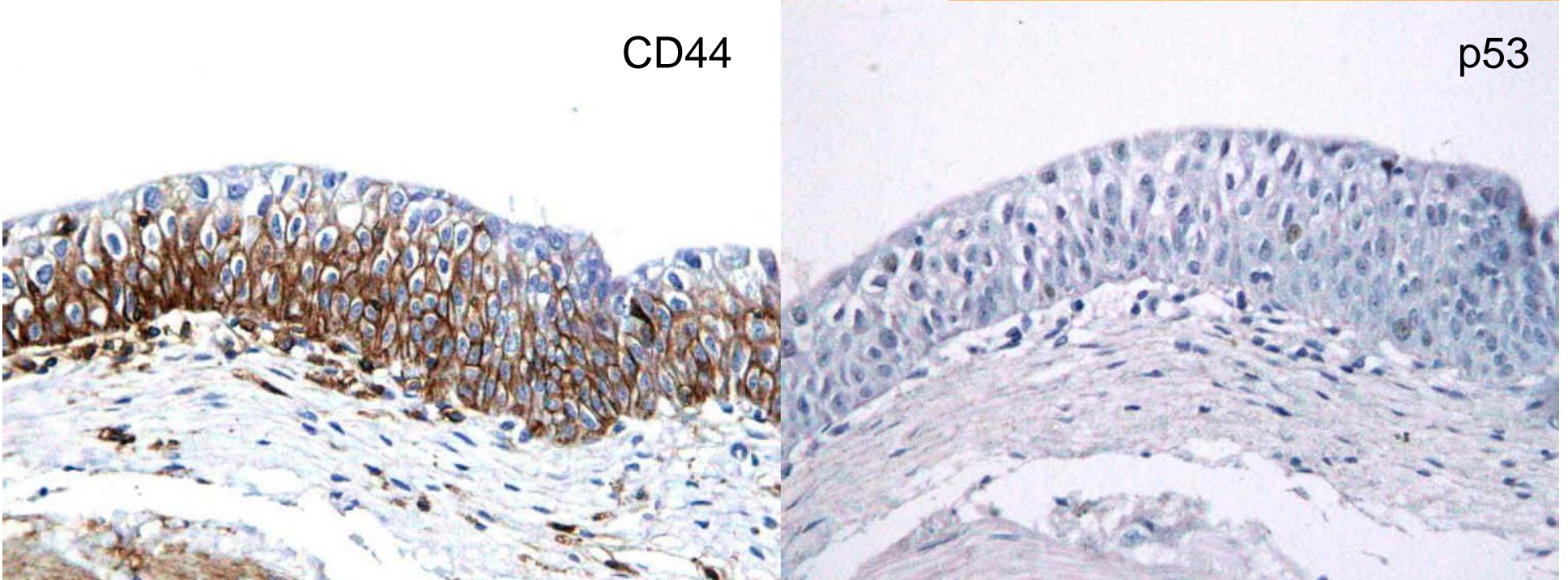
CIS variant

- Could be named hyperplasia papillar with atypia, but the term is misleading

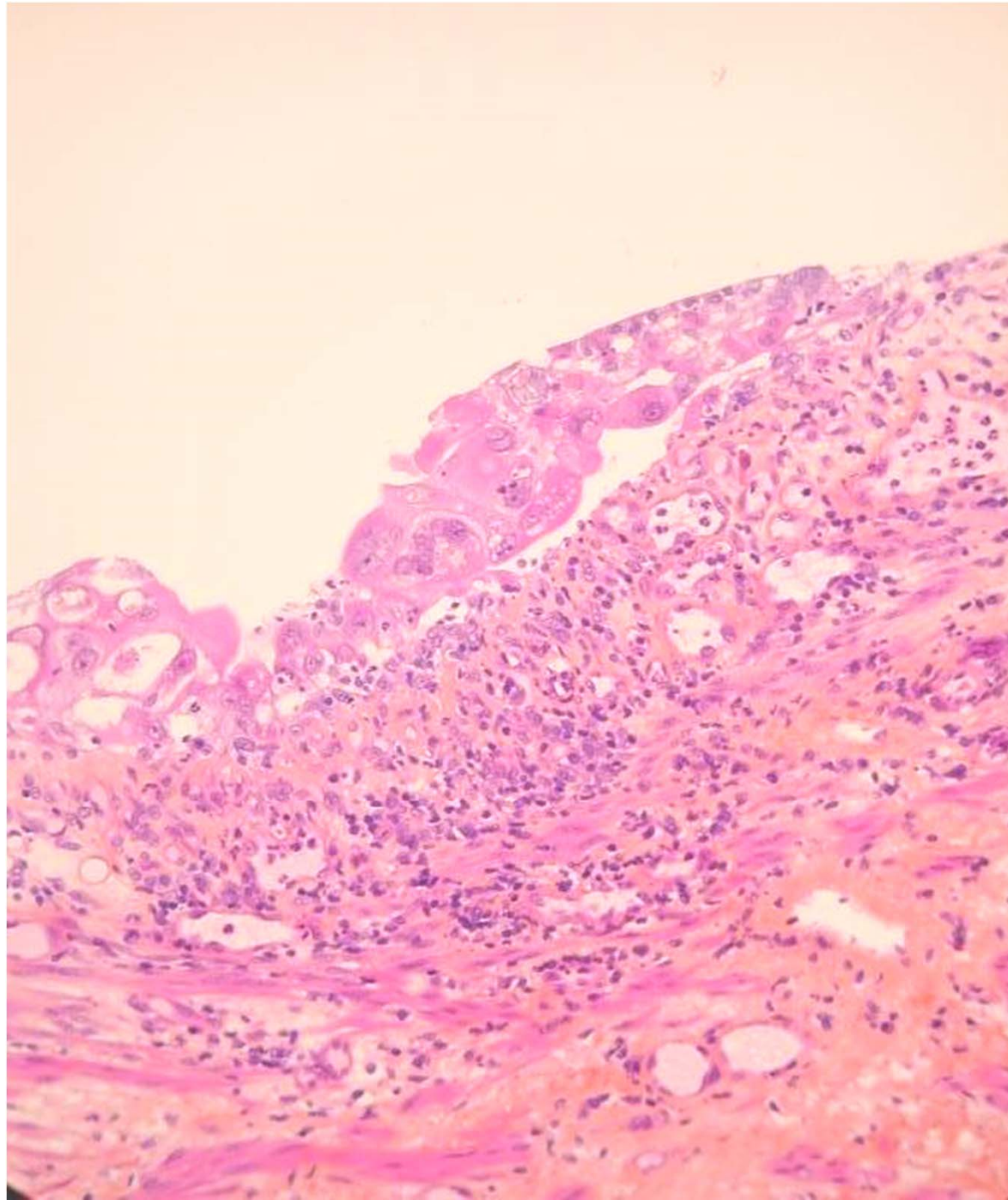


CD44

p53

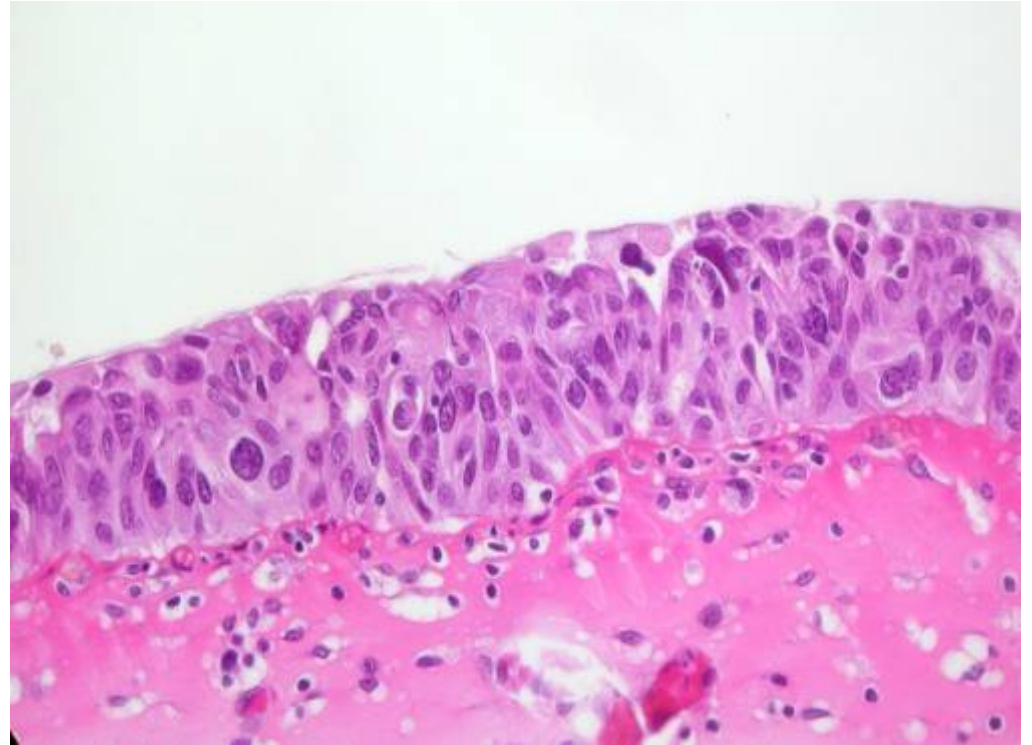
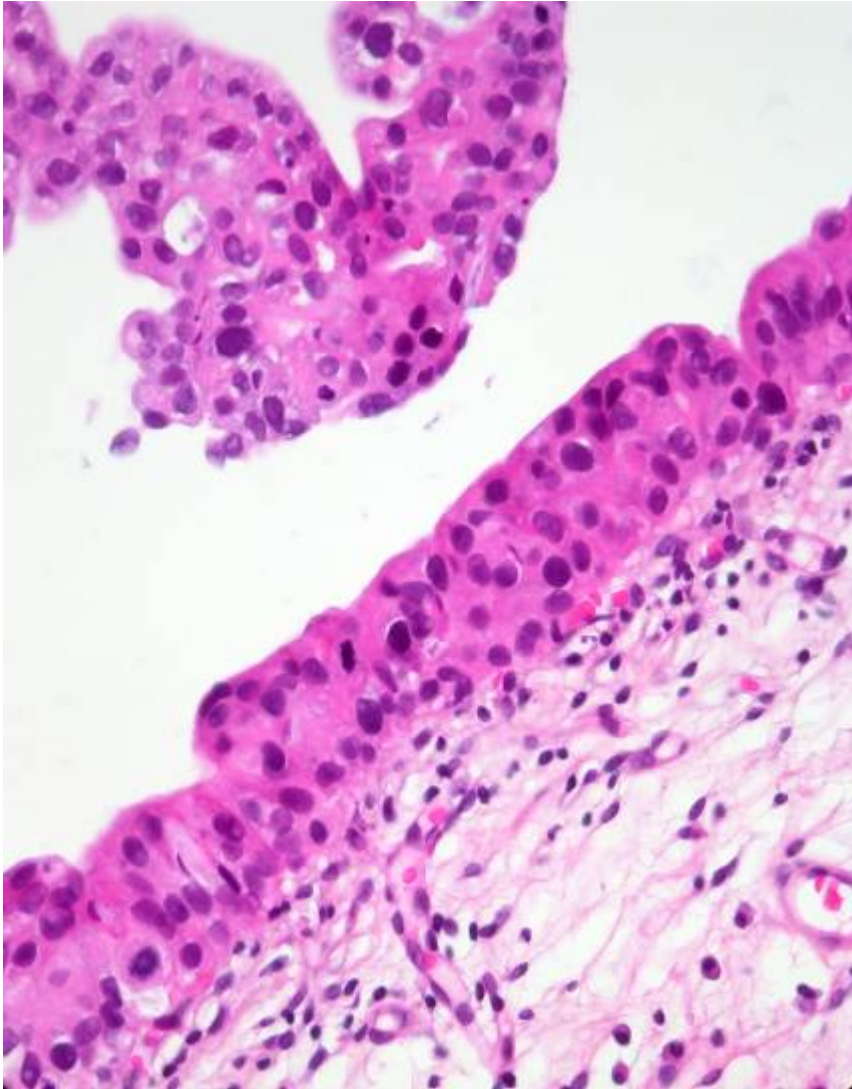


Reactive epithelium

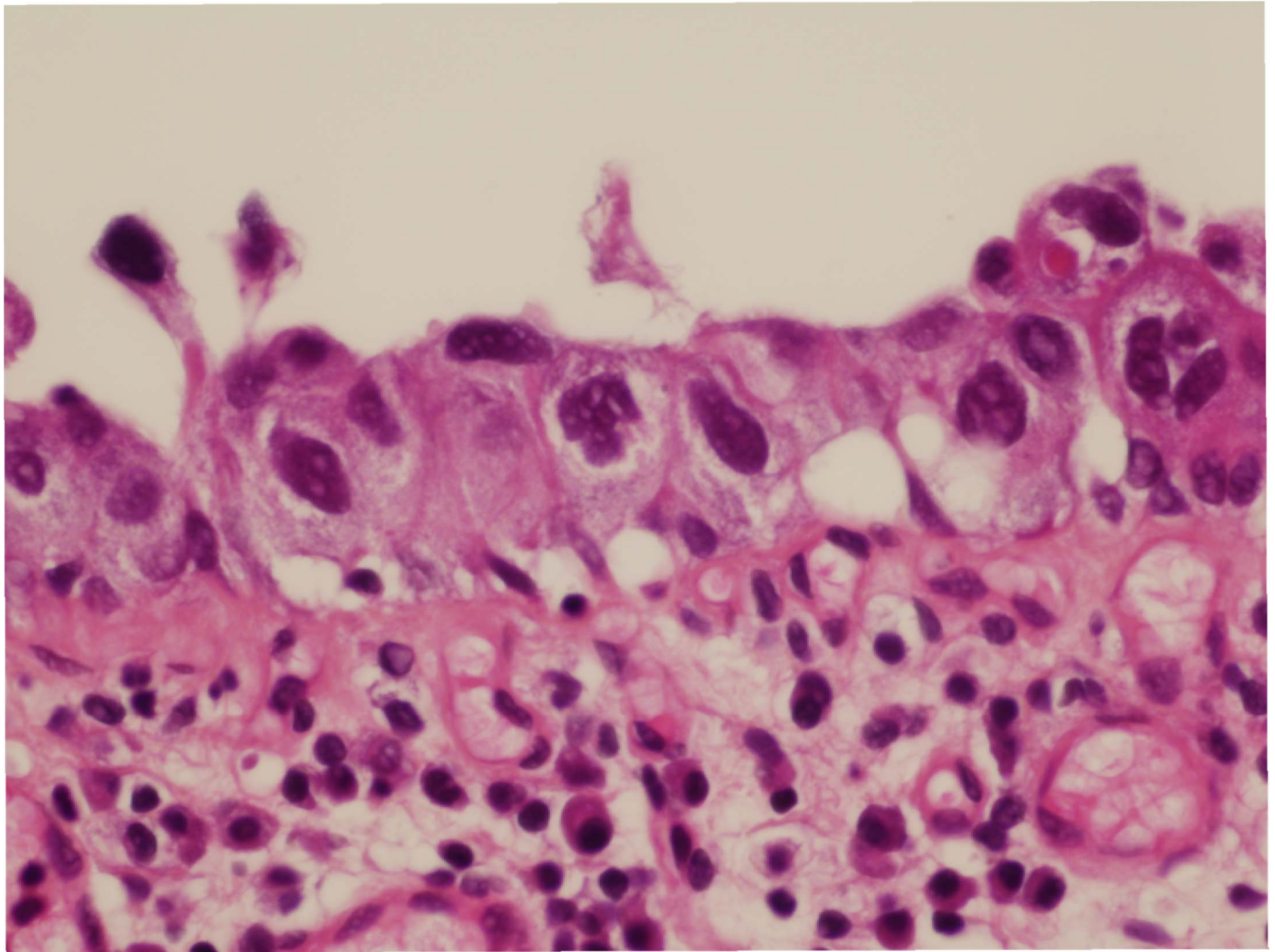


Aspect post ametycine

Aspect post BCG

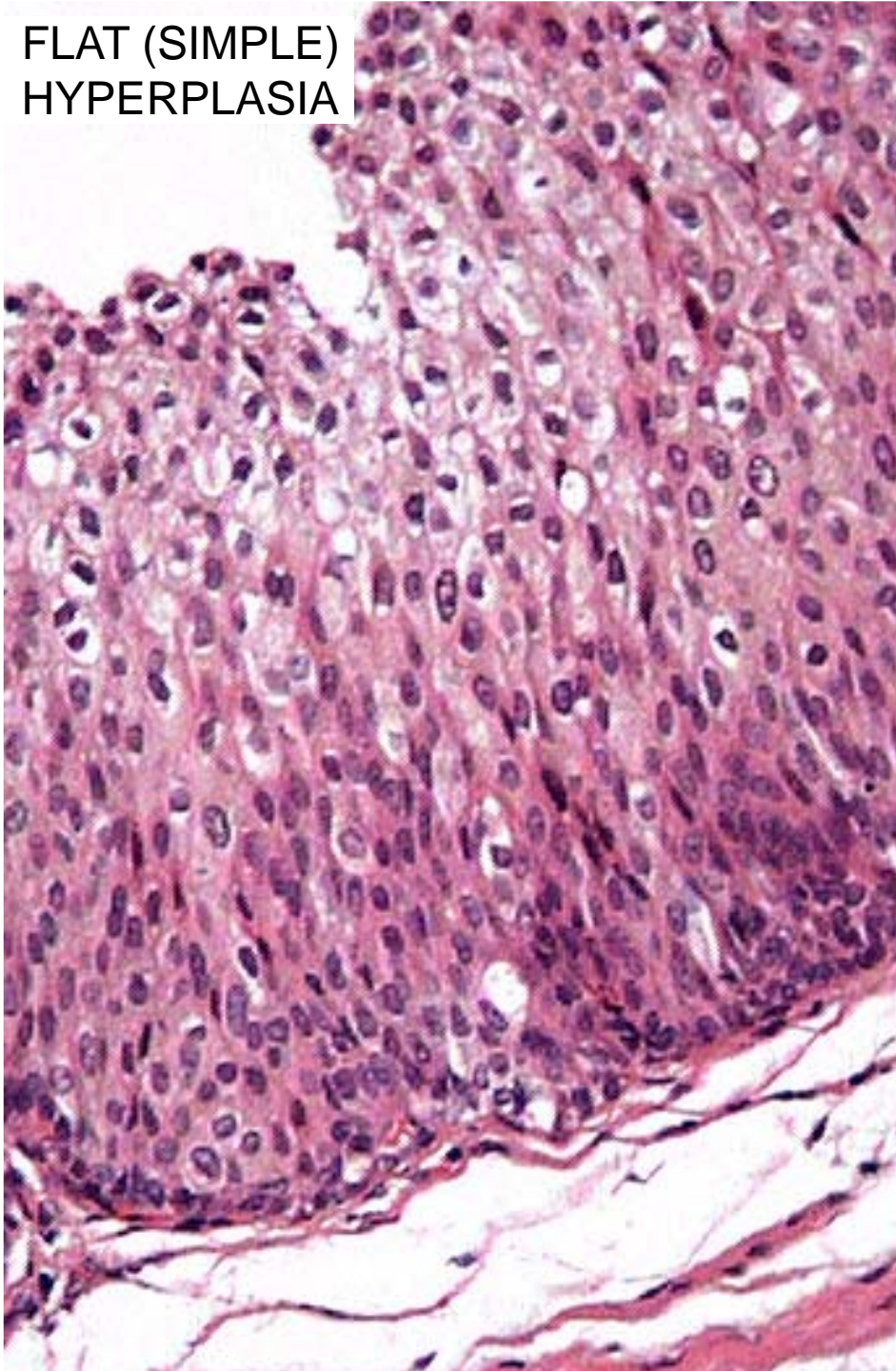


CIS

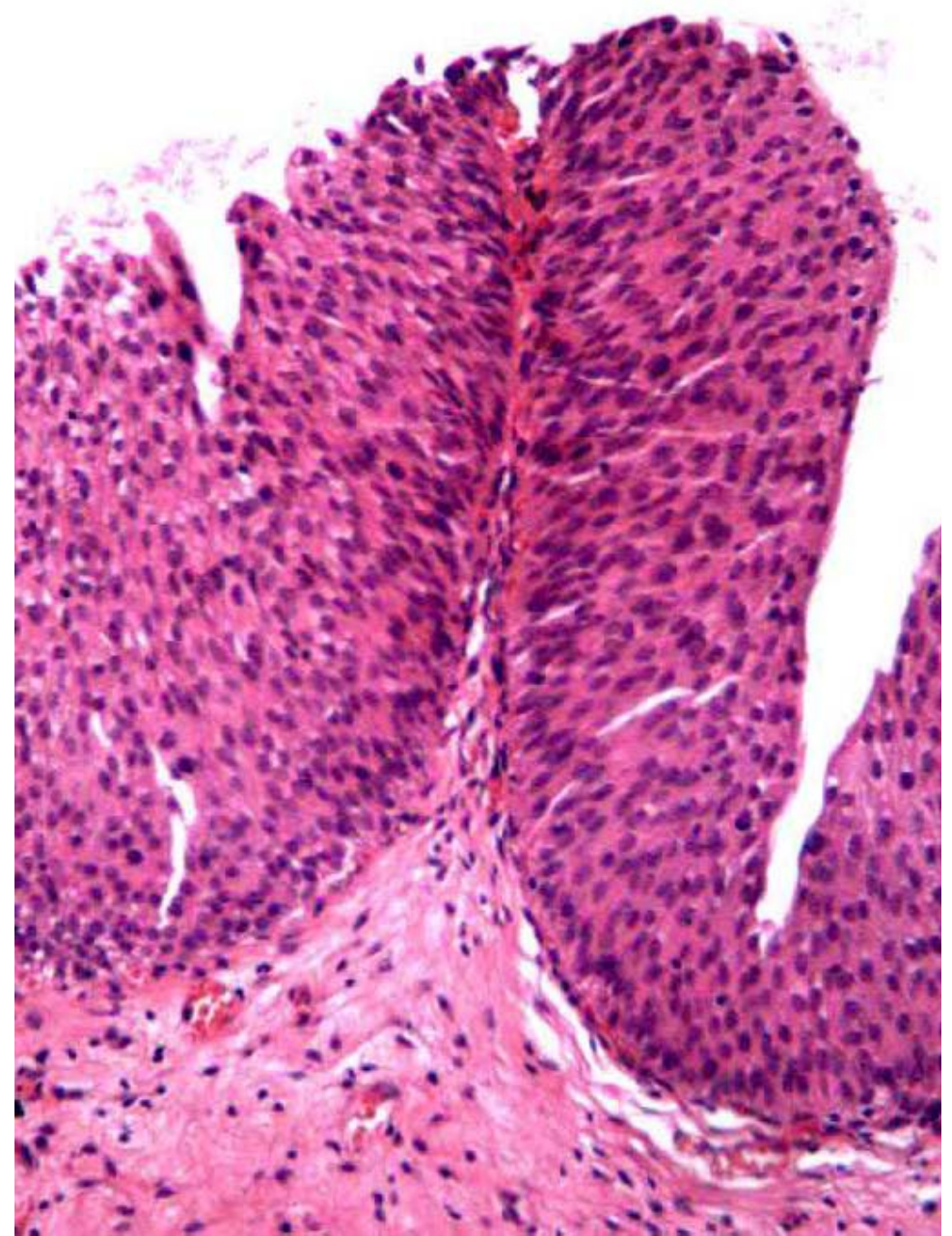


CIS

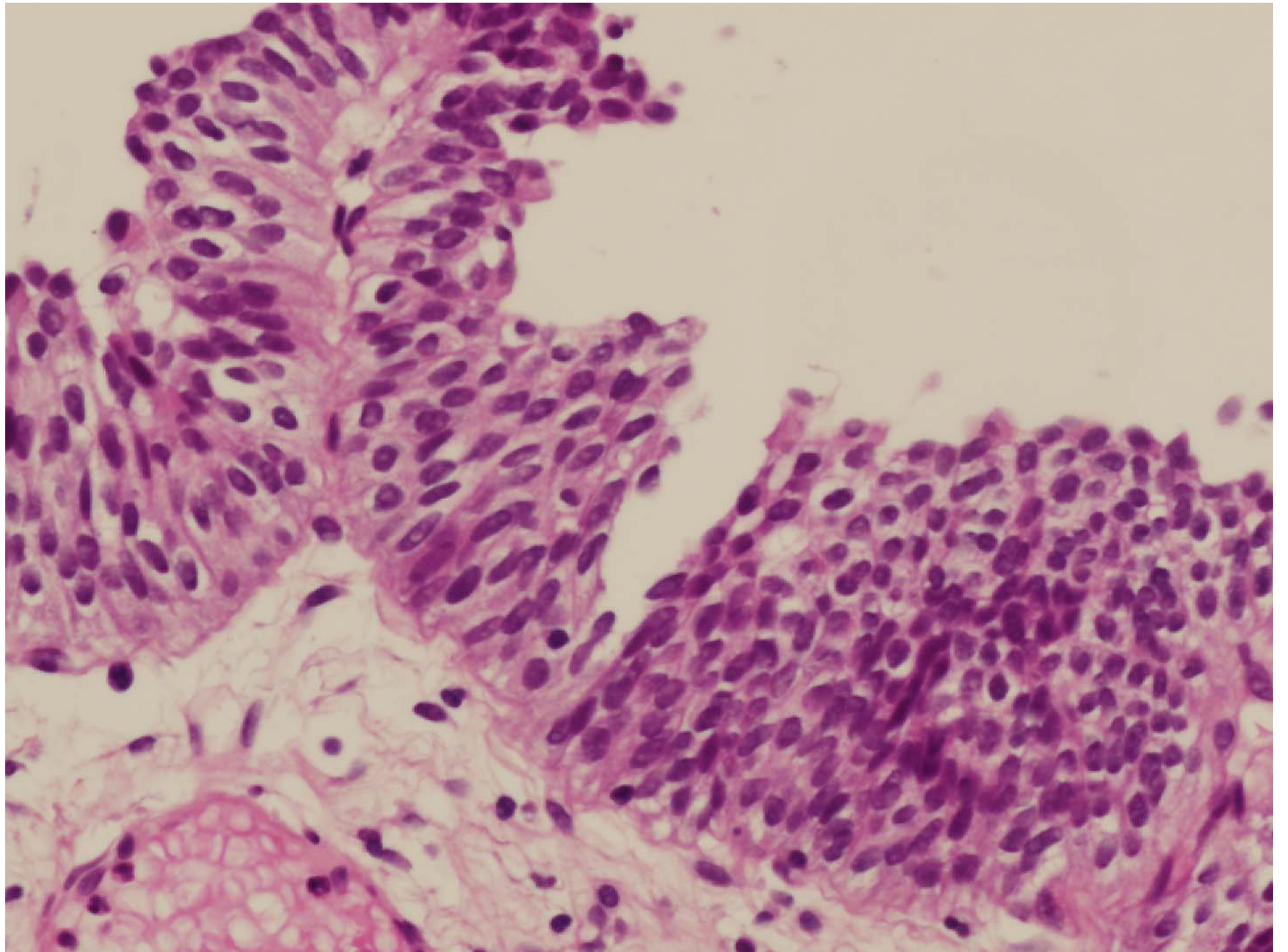
FLAT (SIMPLE)
HYPERPLASIA



PAPILLARY HYPERPLASIA



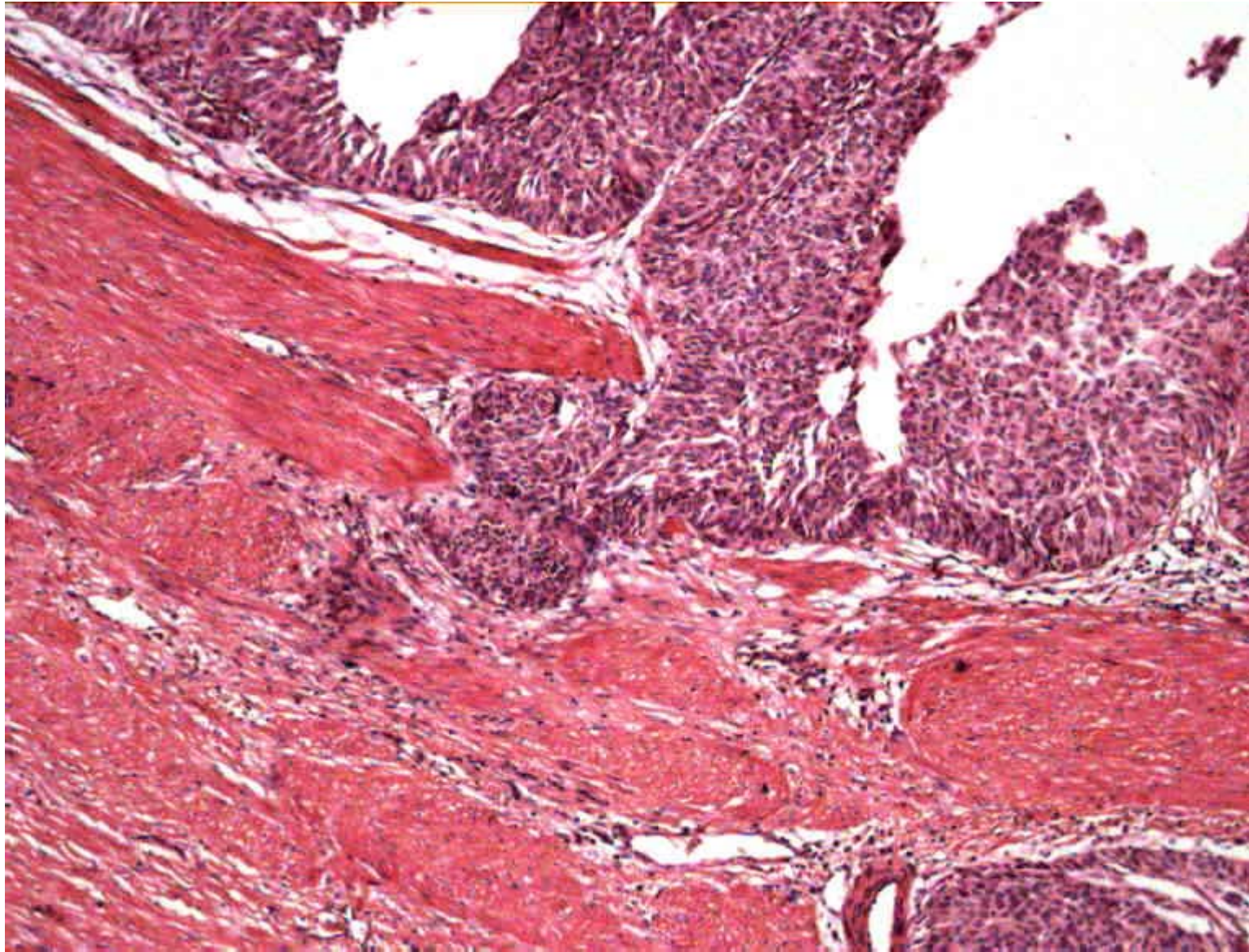
Prior history of UBC, low grade Ta



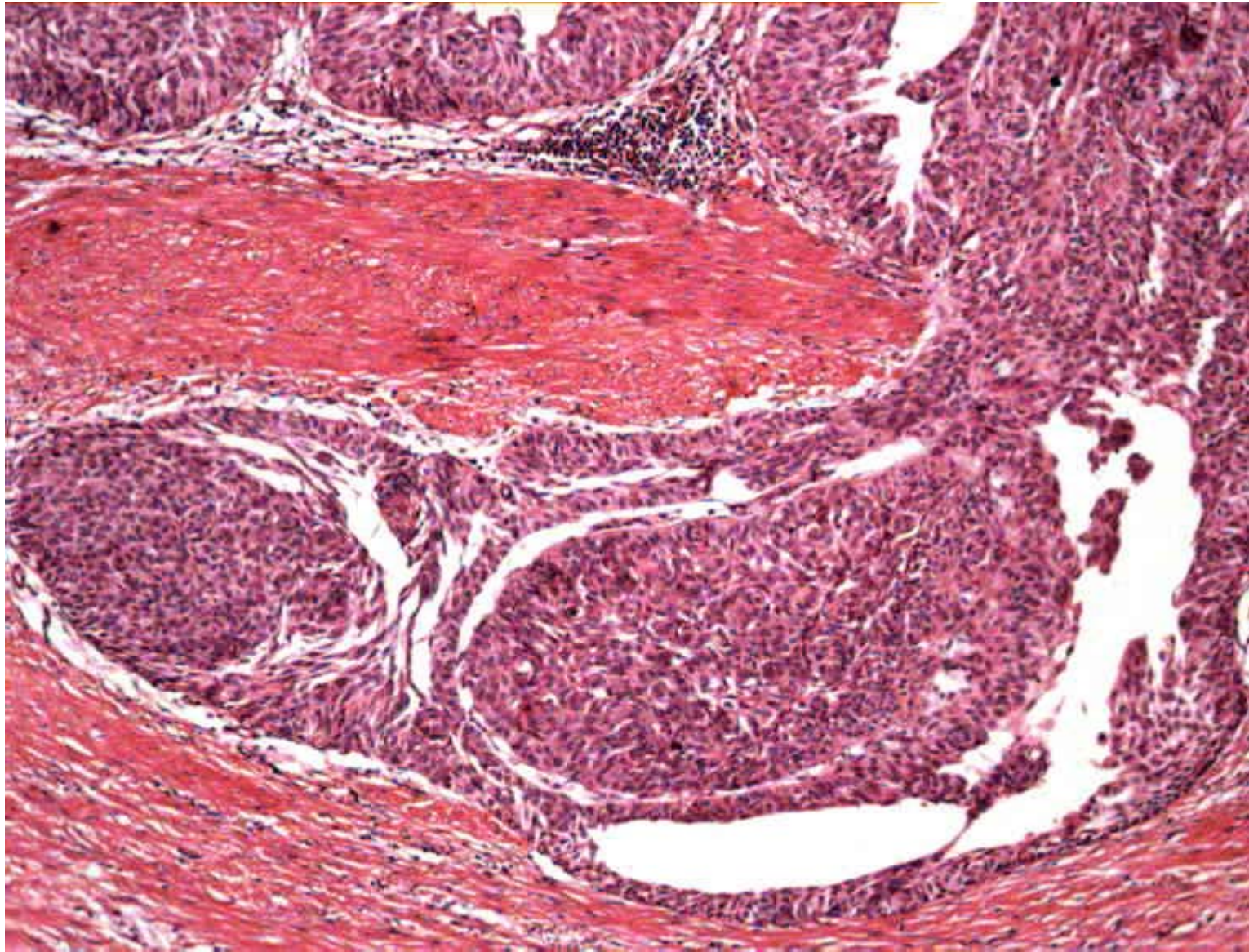
Early recurrence Ta low grade carcinoma ?

Staging

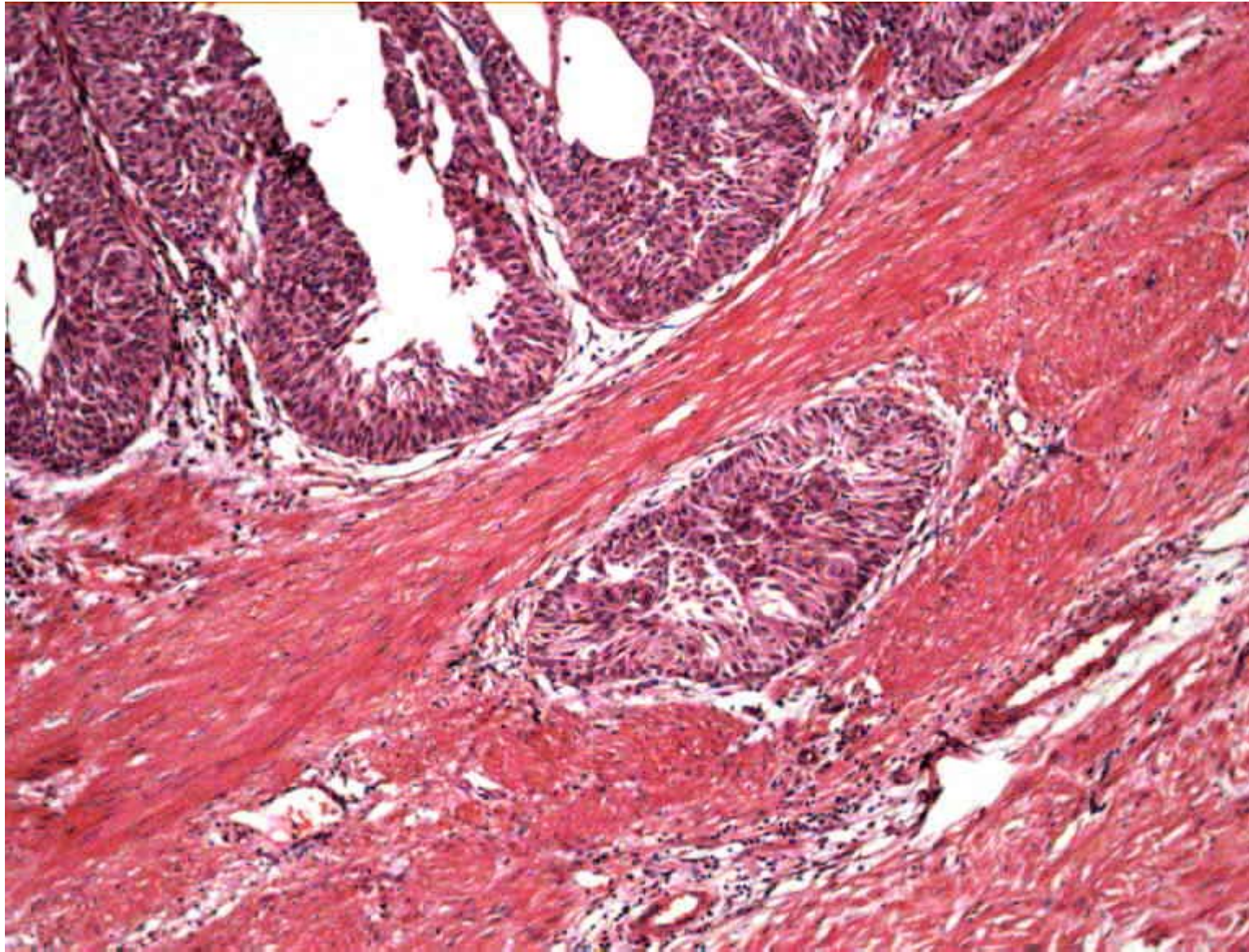
URETER



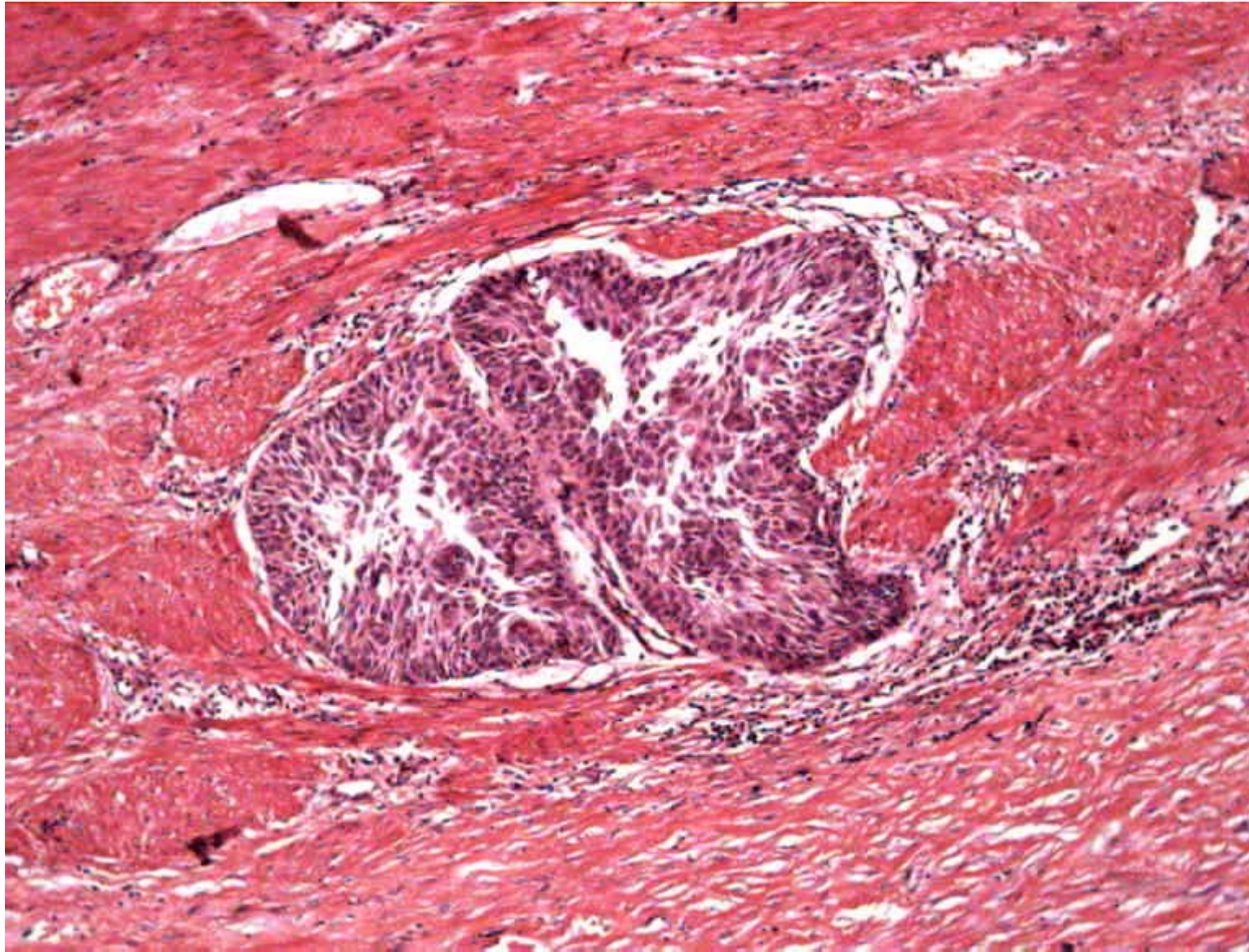
URETER



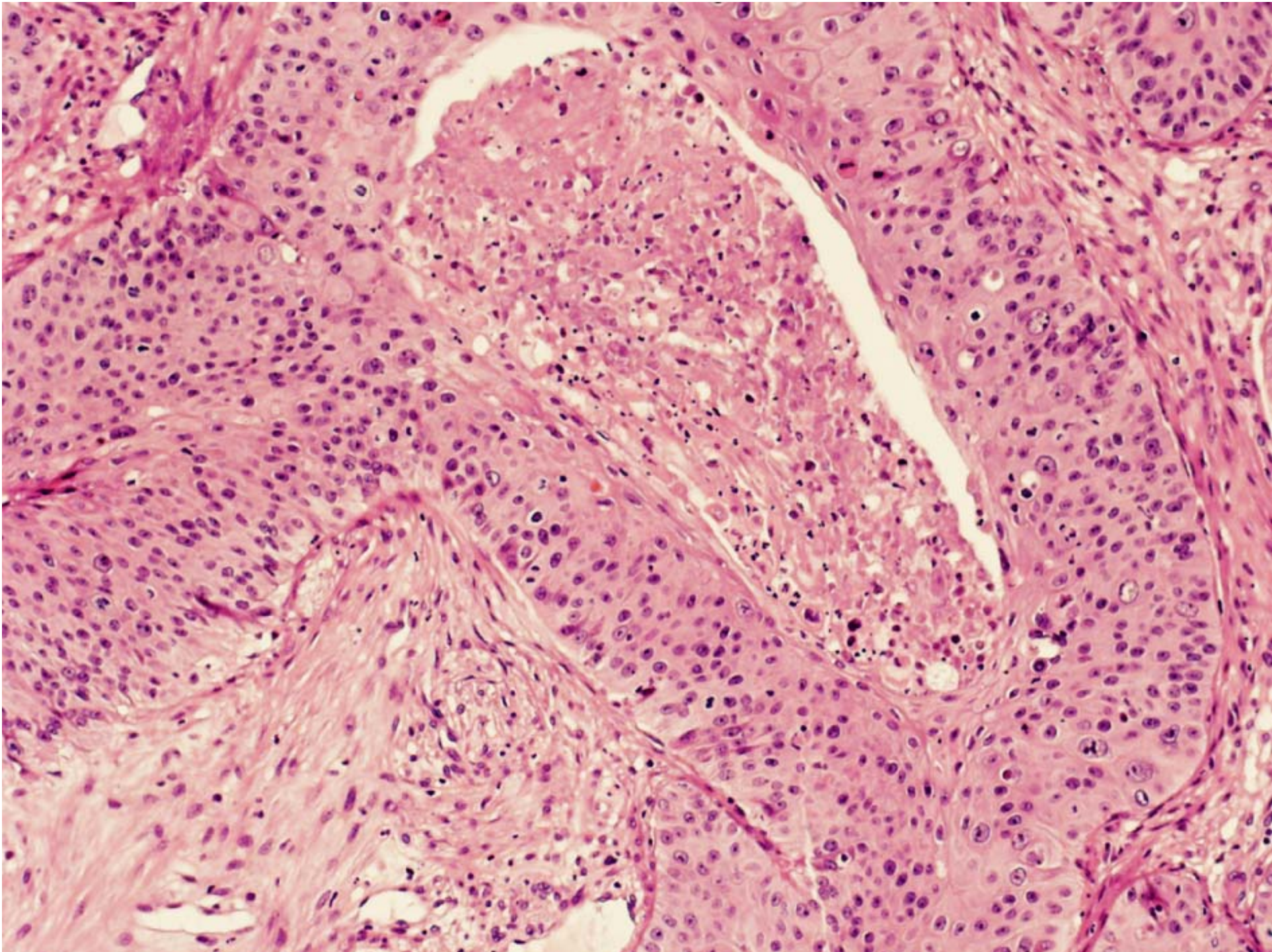
URETER



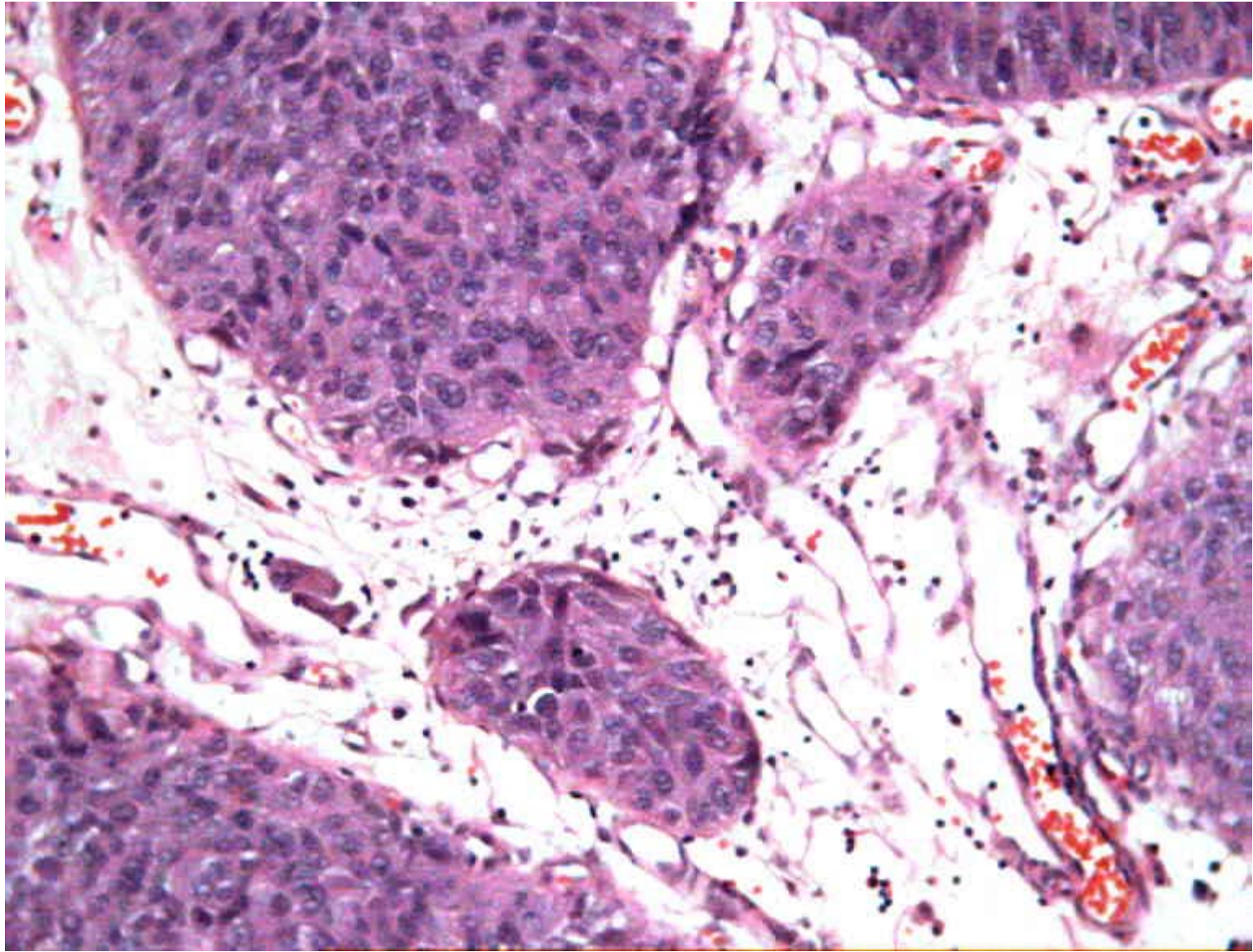
URETER

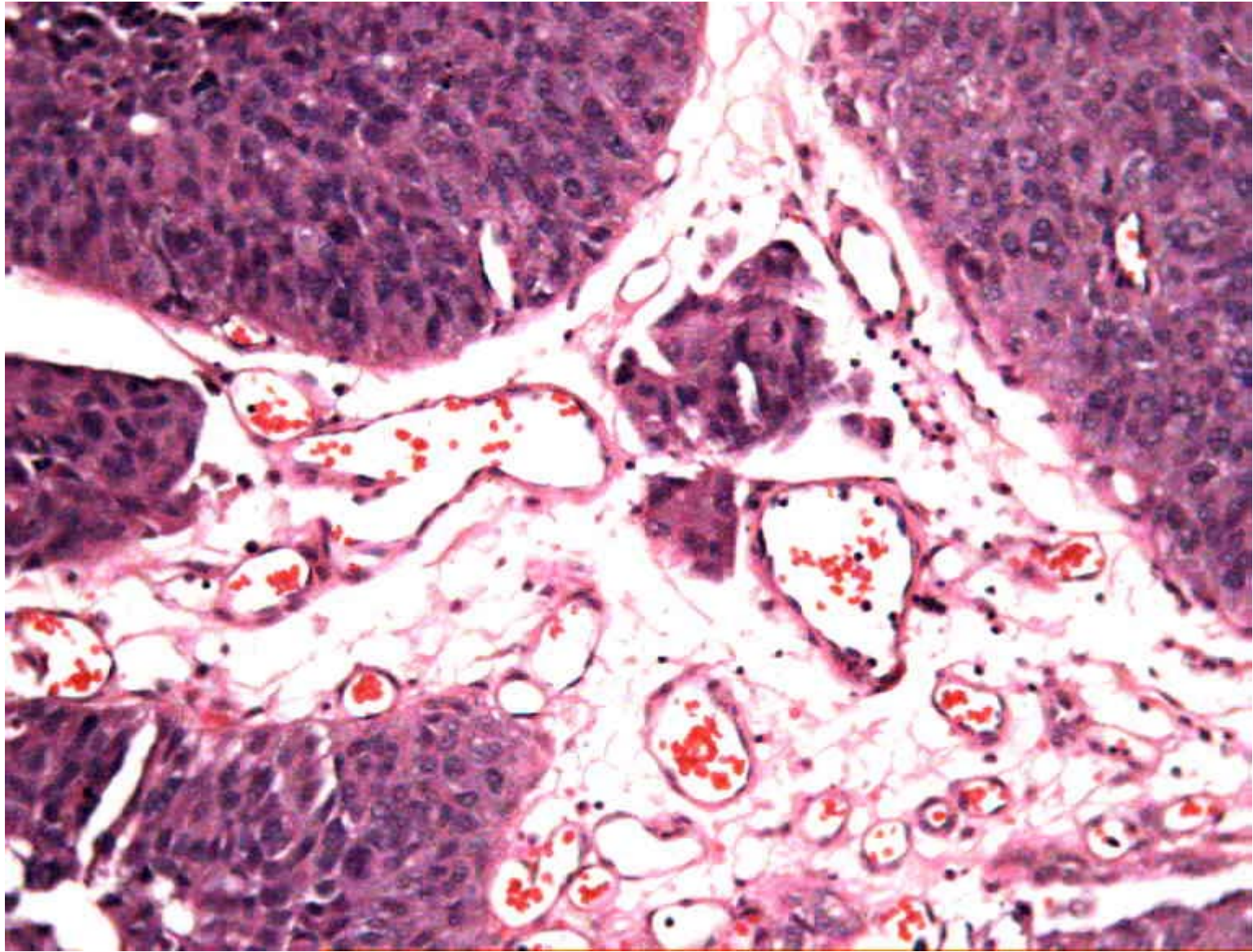


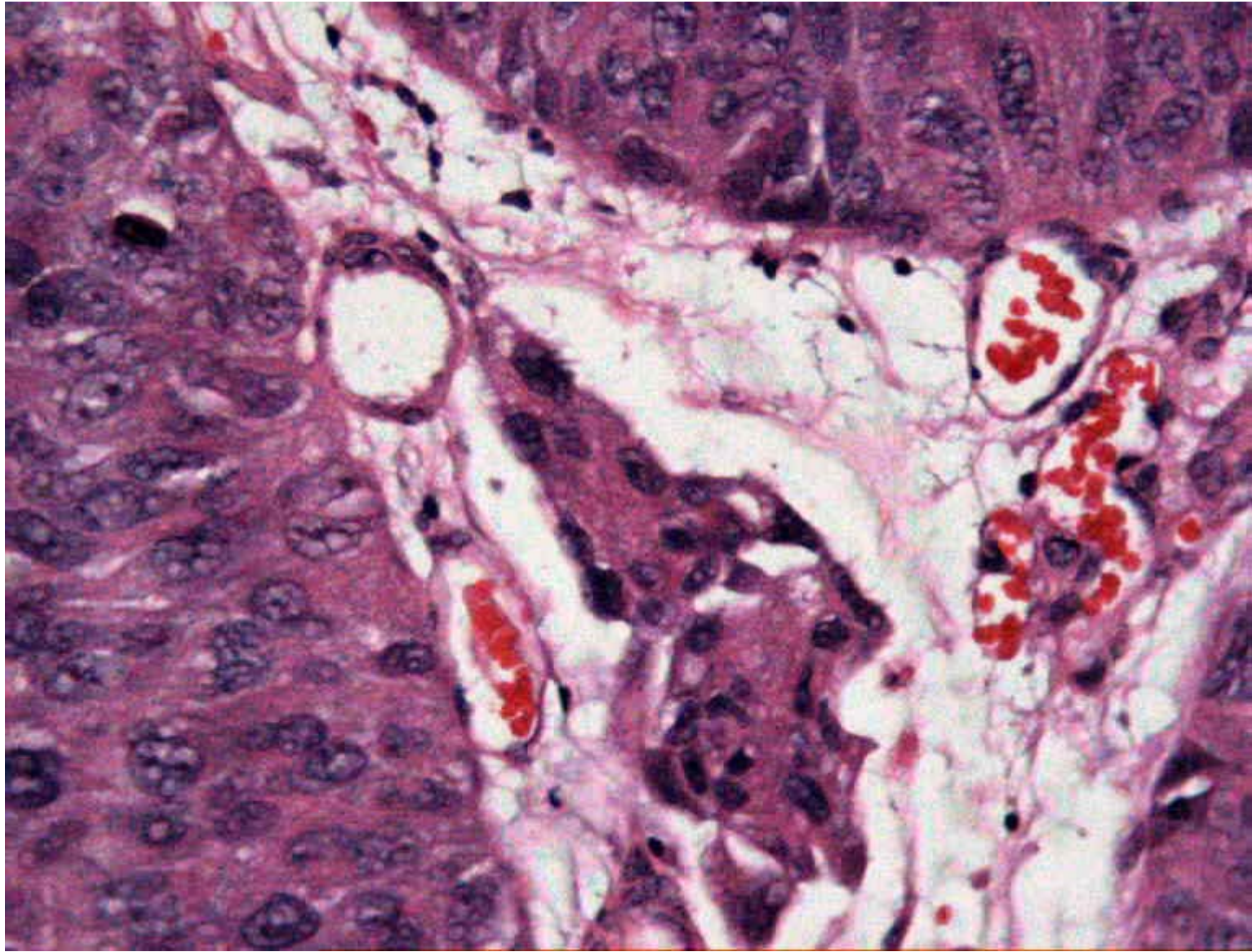
Muscle invasion (T2)
endophytic growth

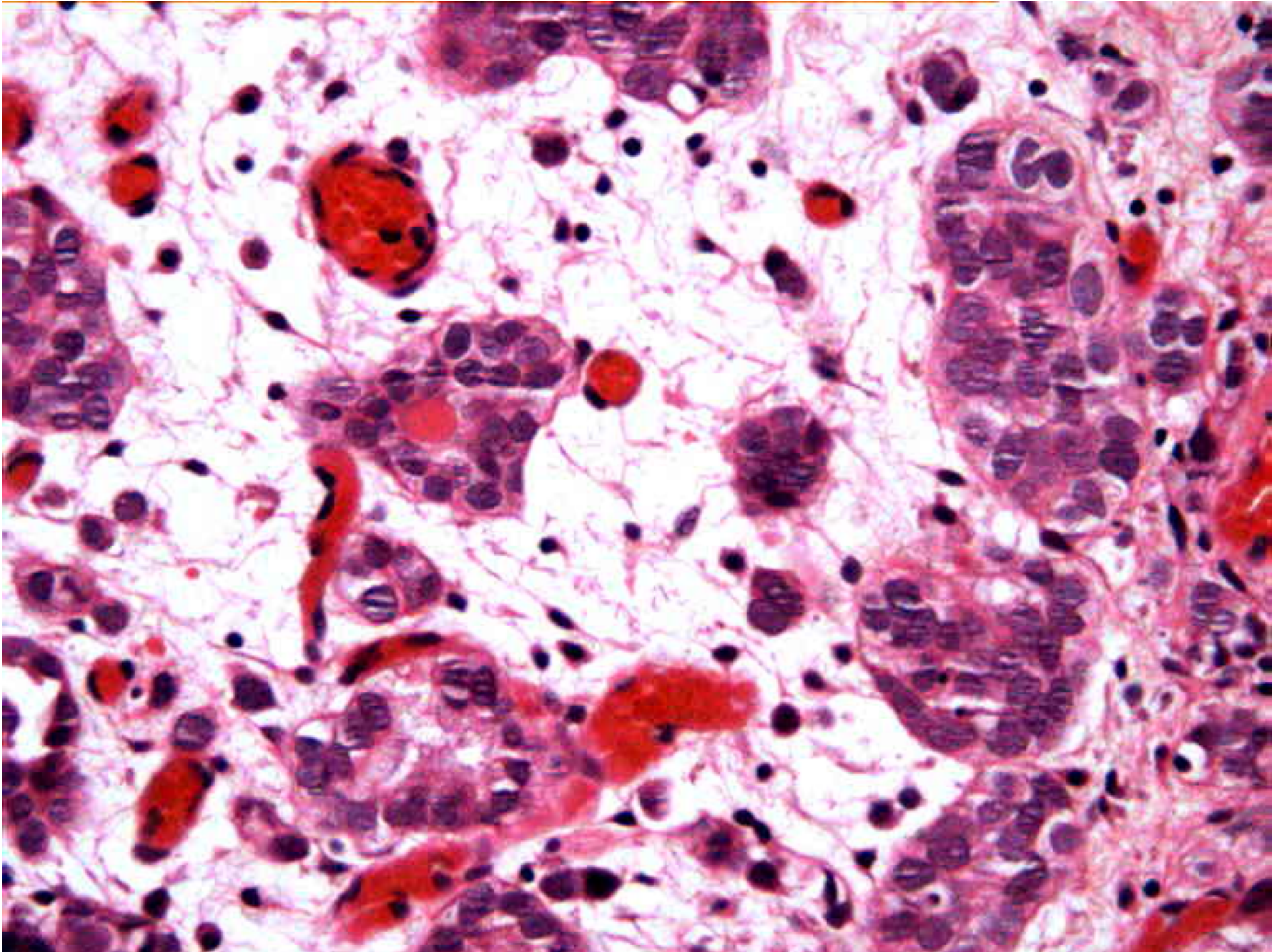


Myofibroblastic stroma

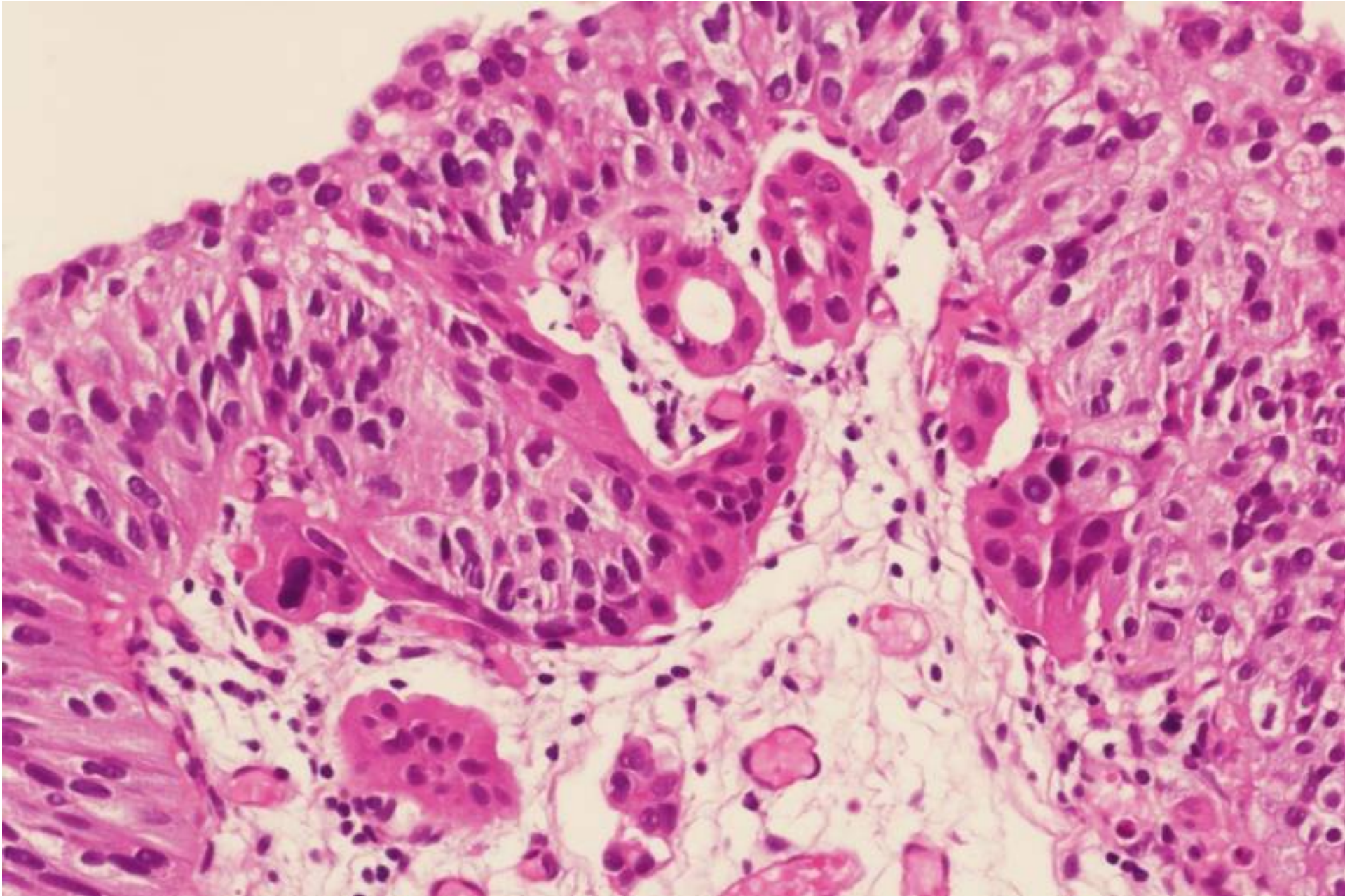




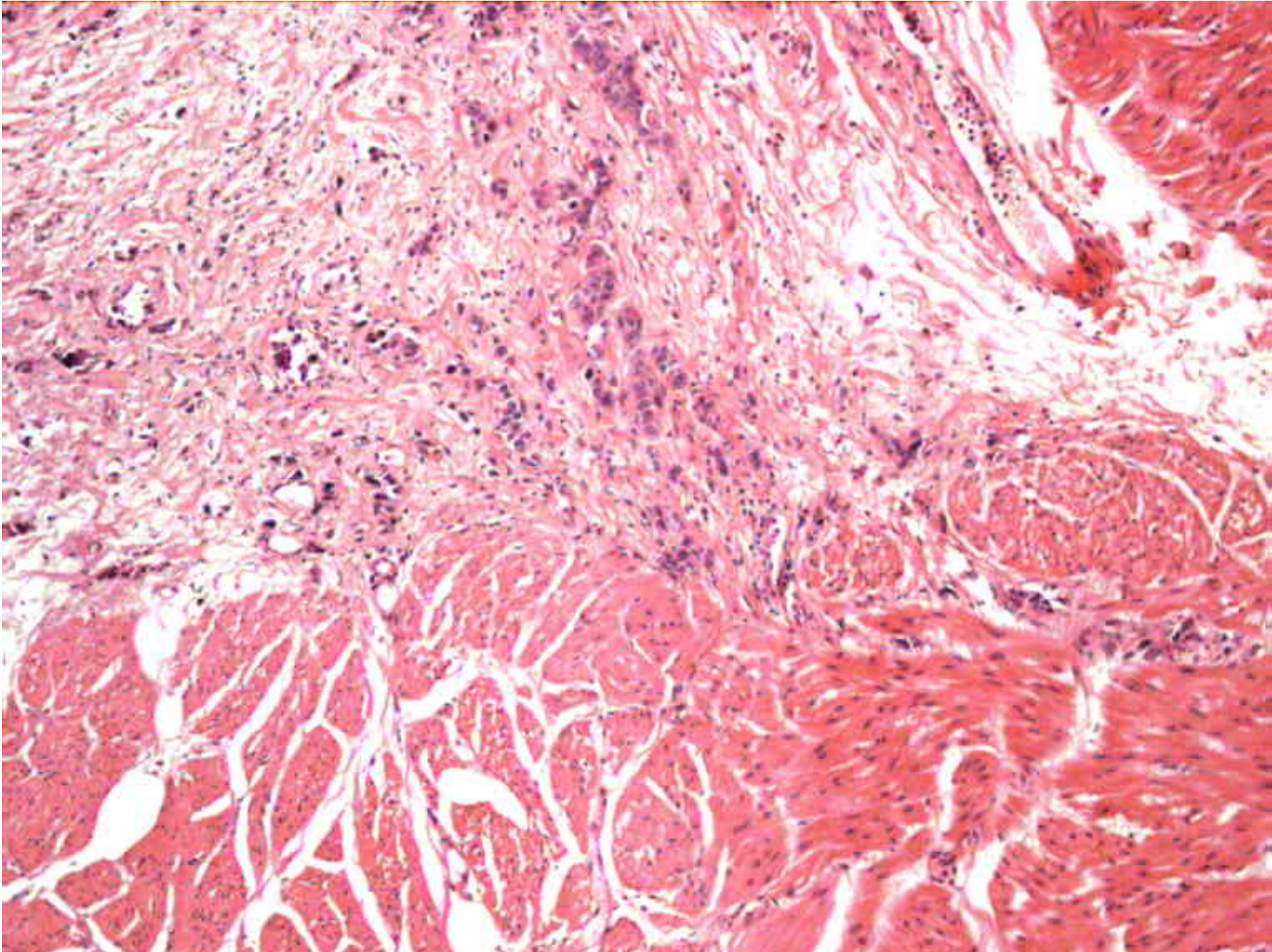


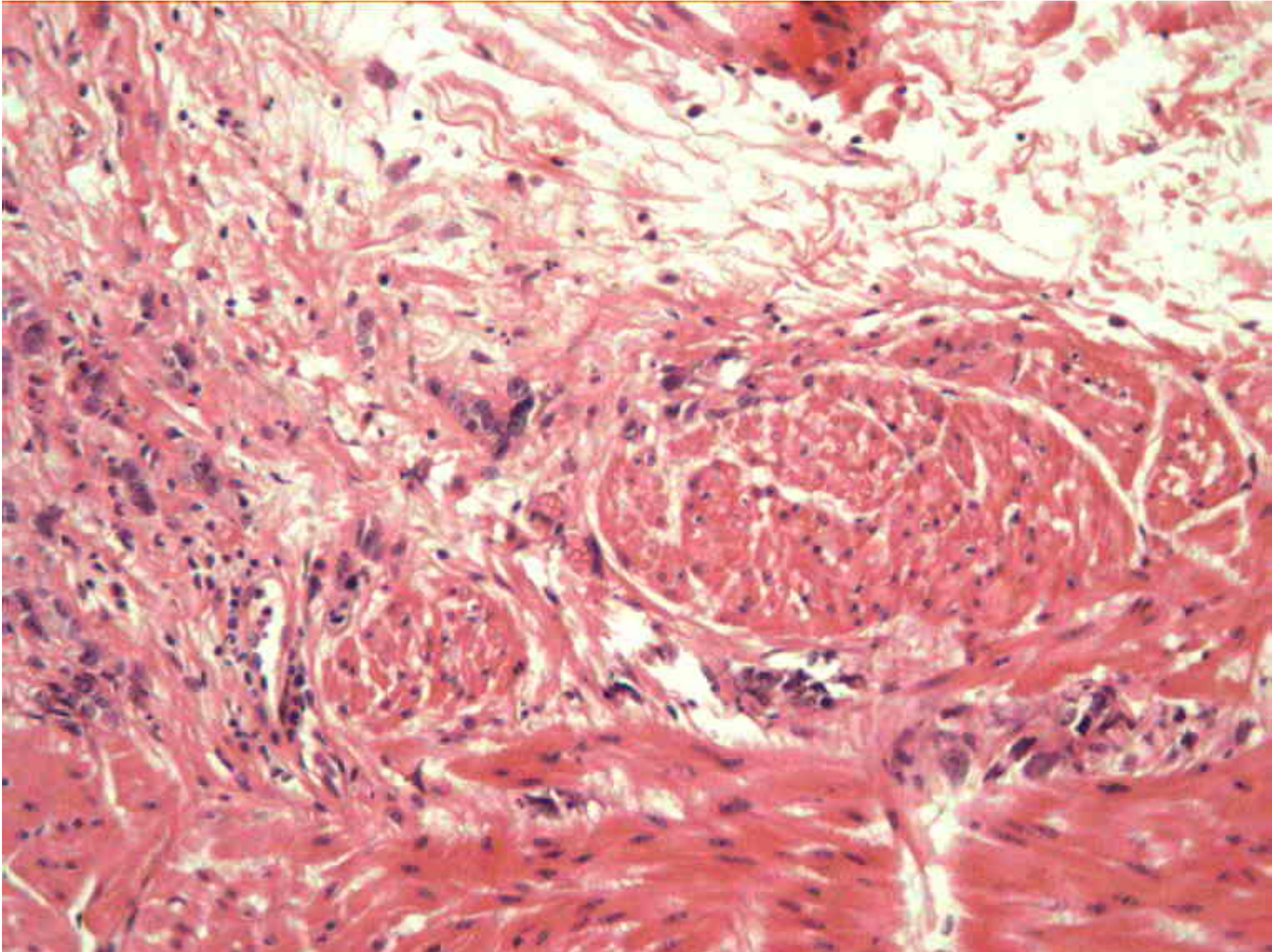


UBC T1

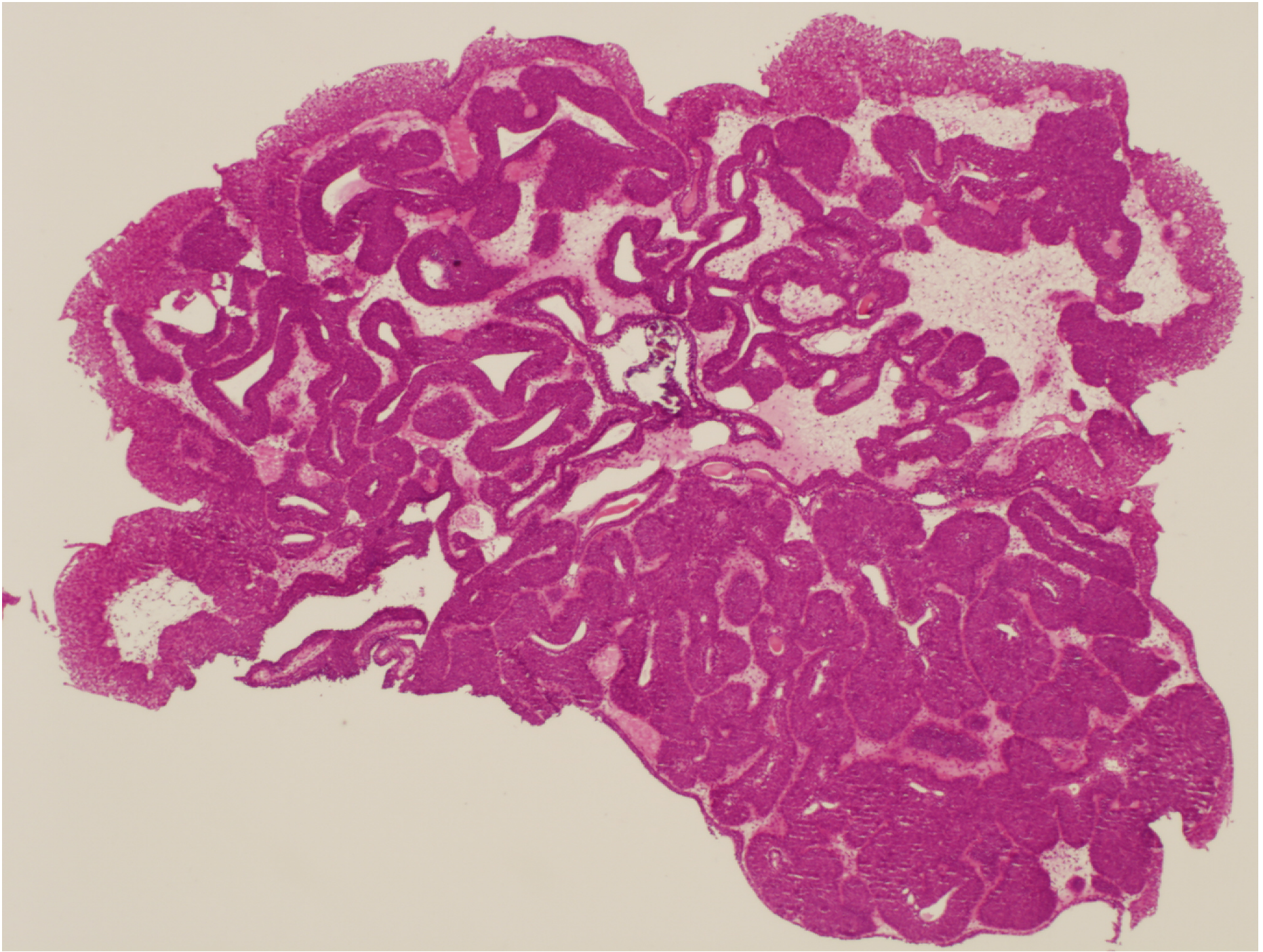


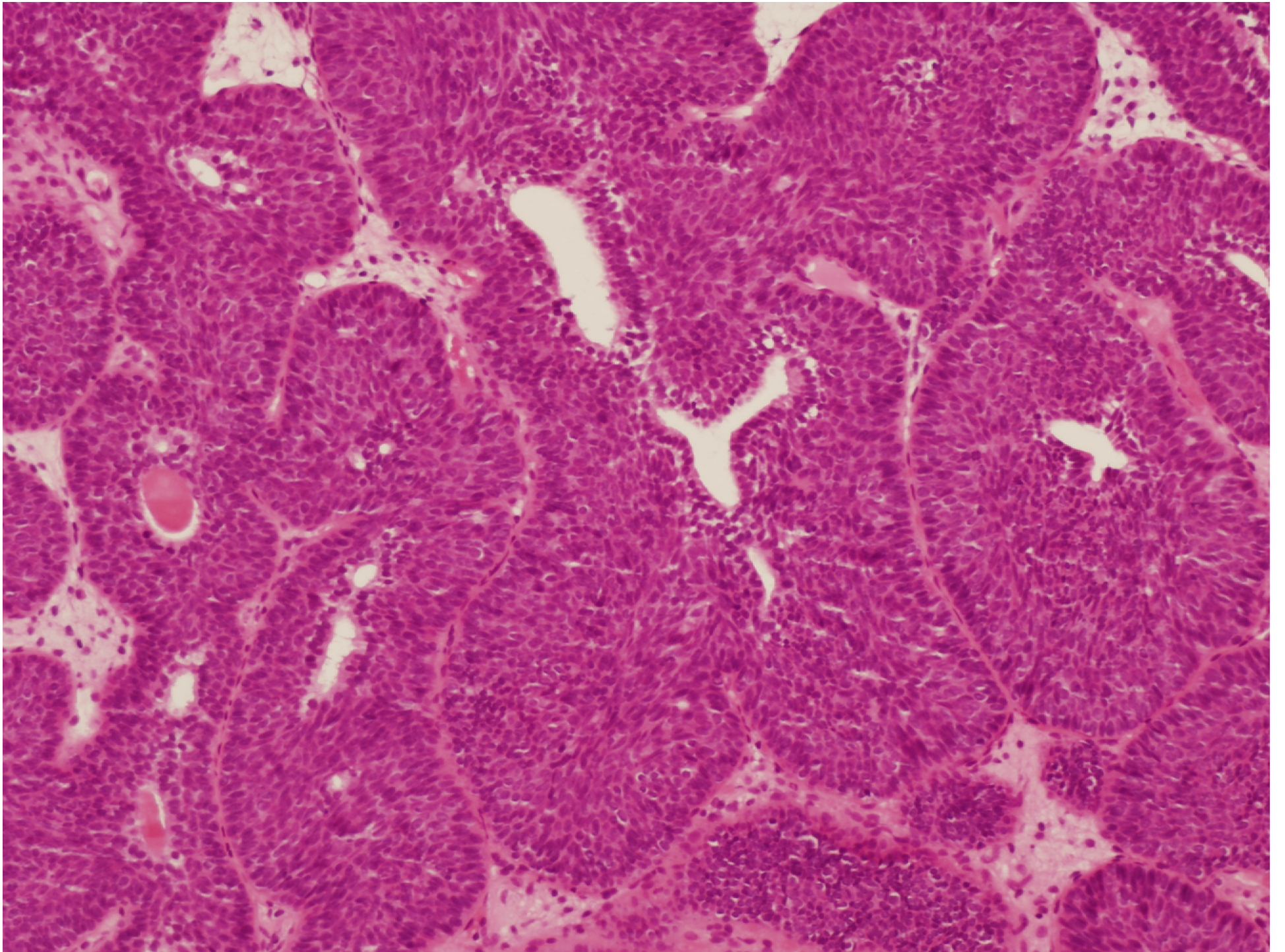
Carcinoma high grade T1 + Tis

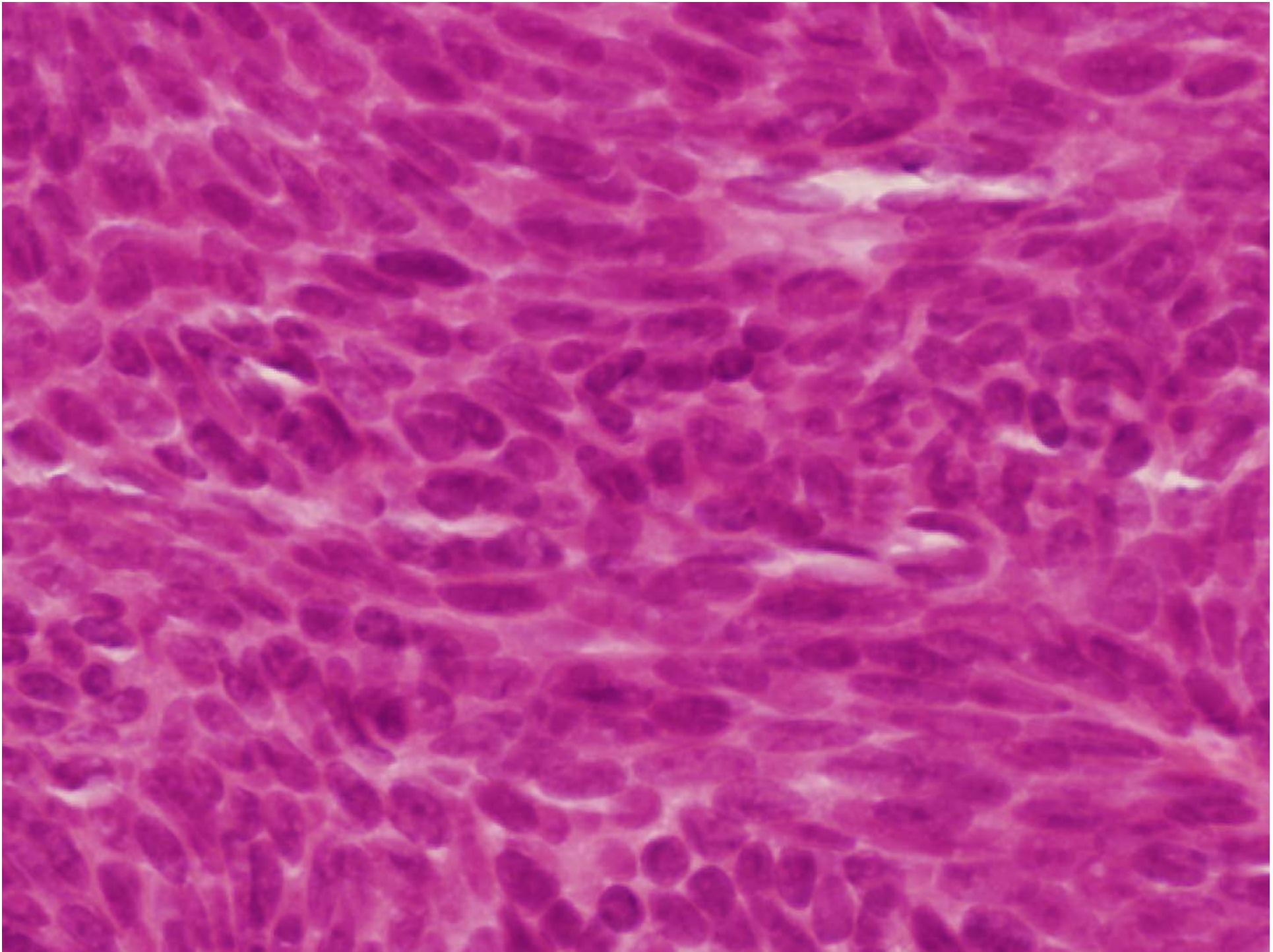


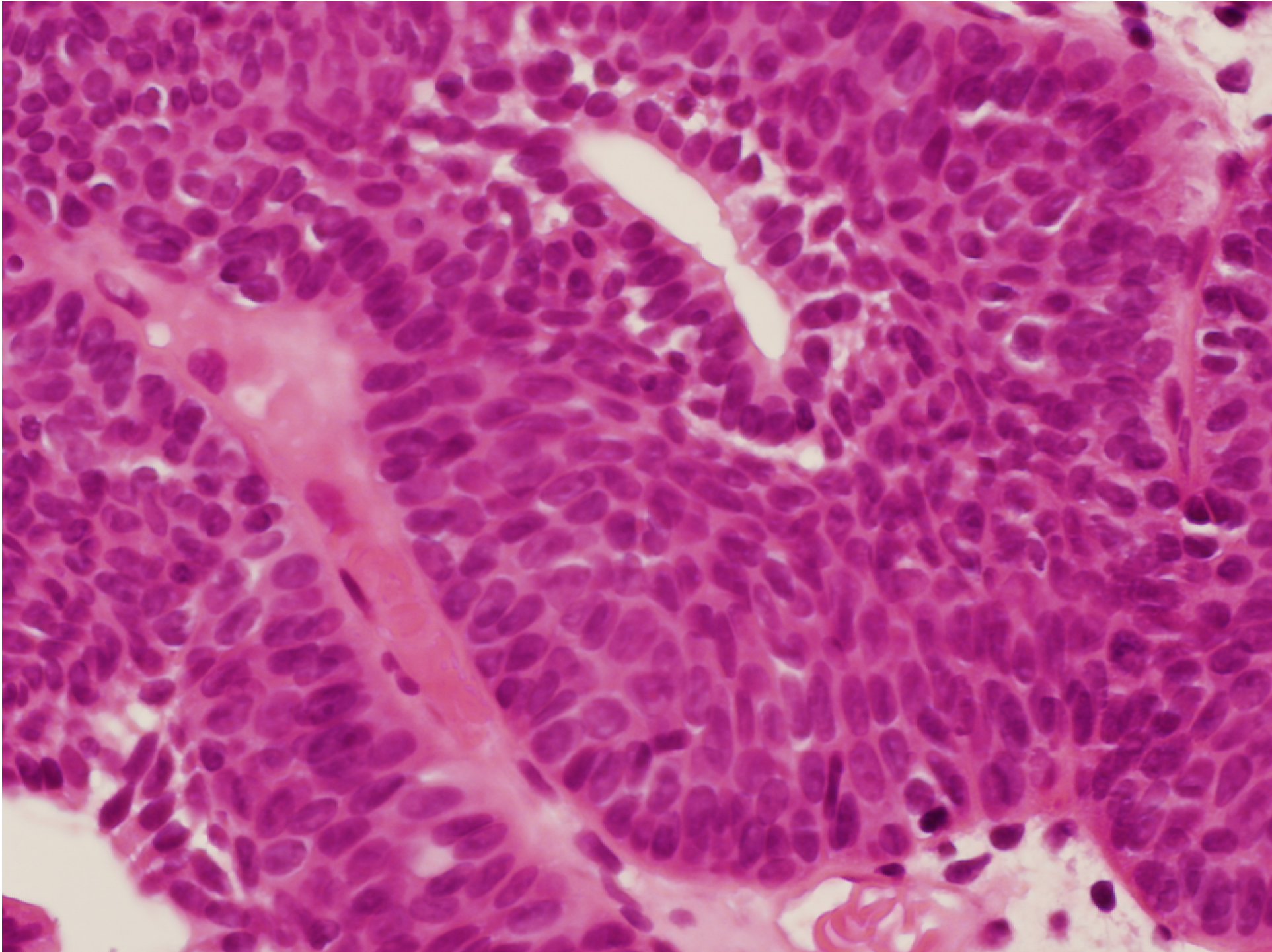


UBC stage T2

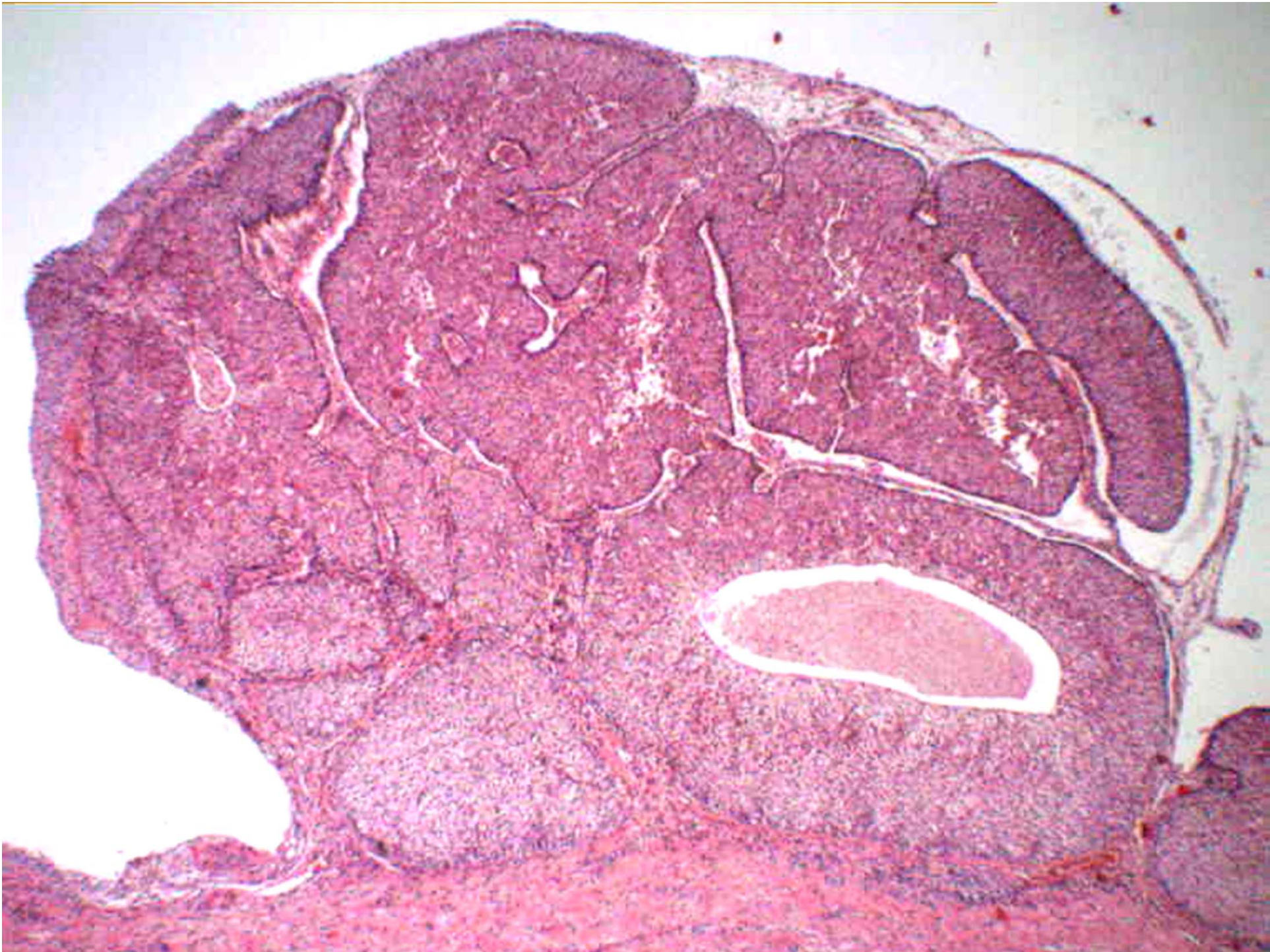

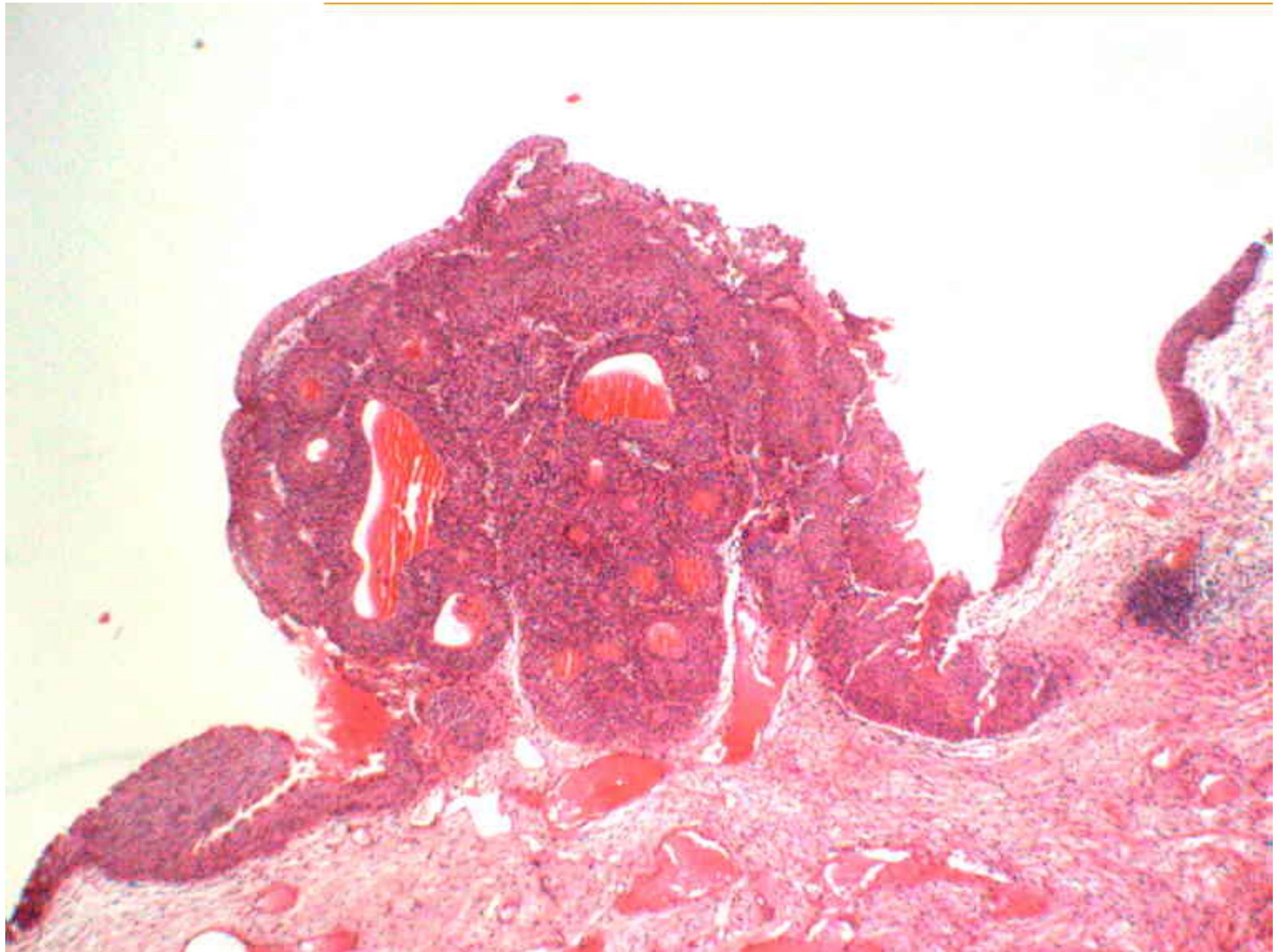





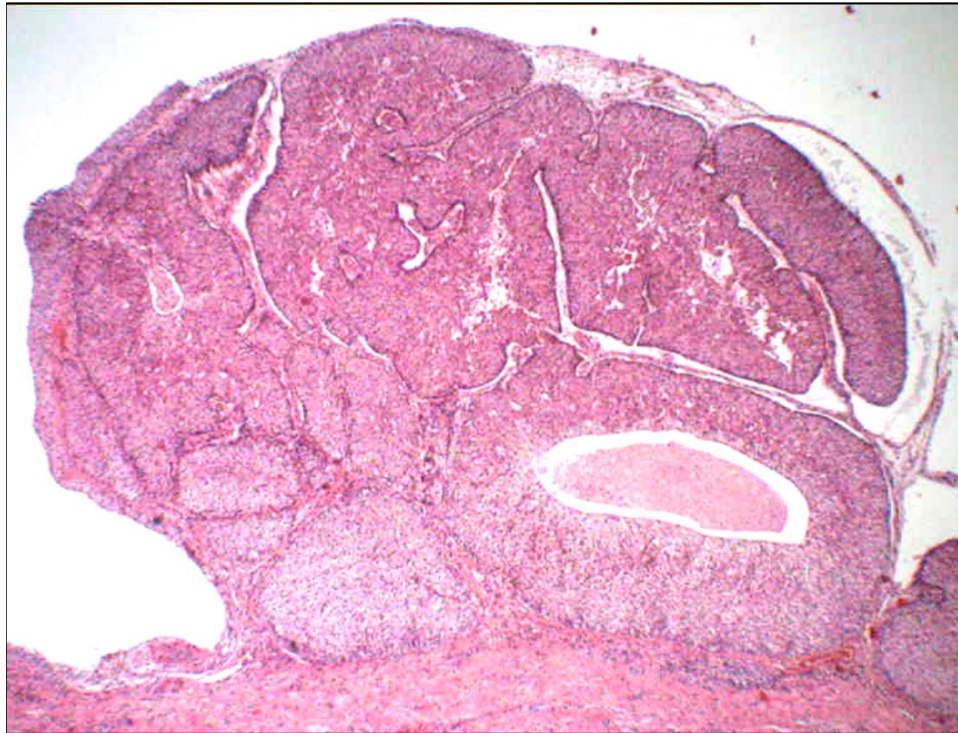
Inverted papilloma

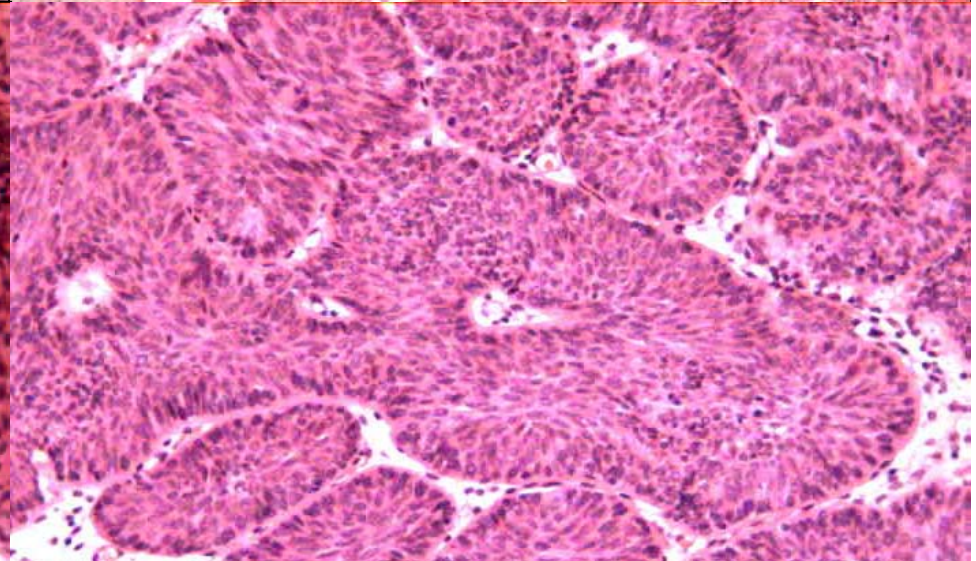
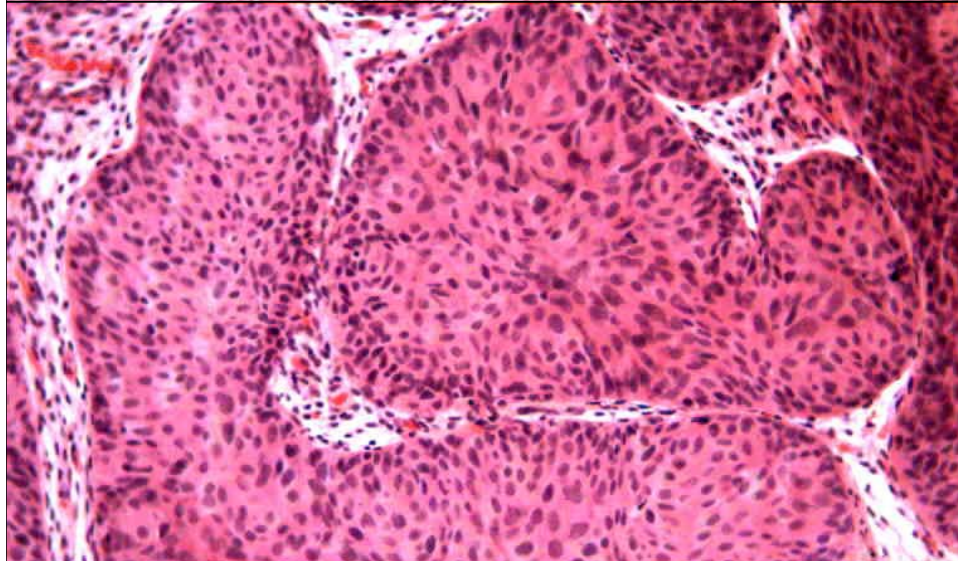
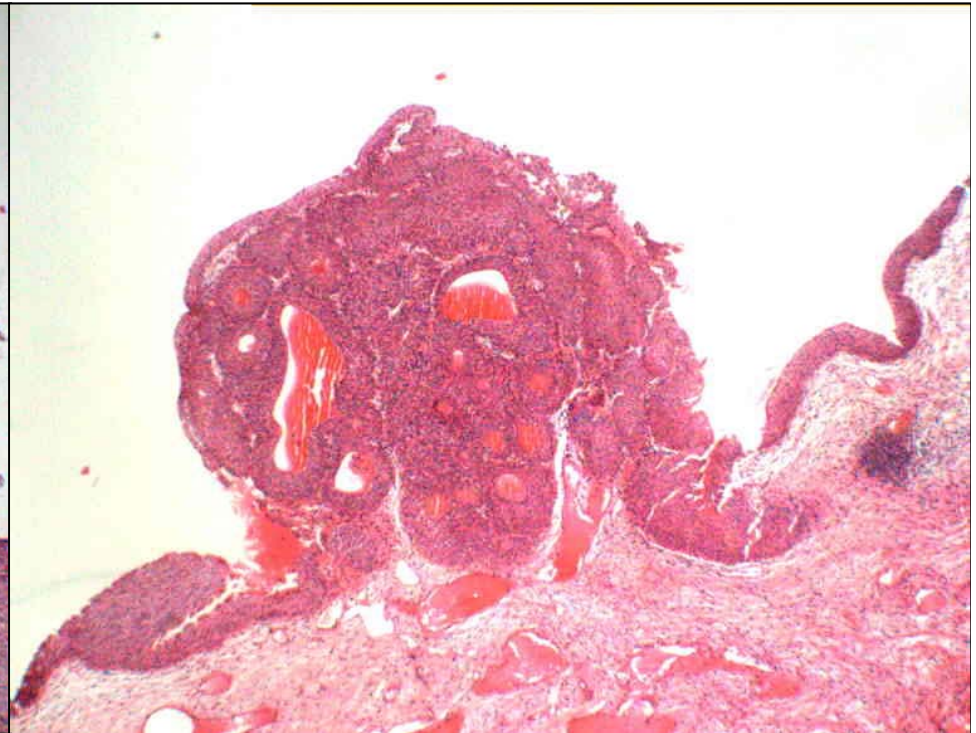




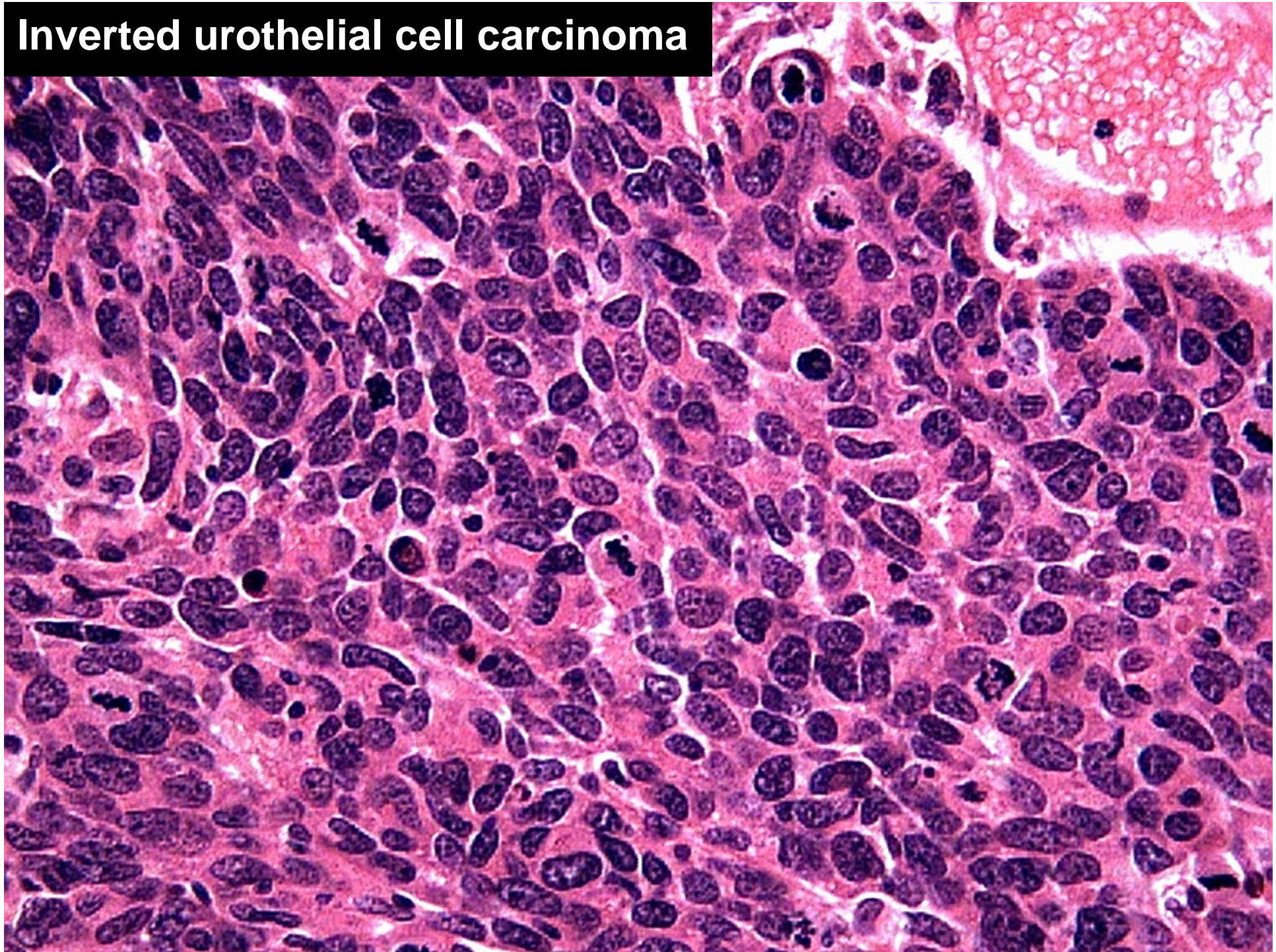
Inverted carcinoma



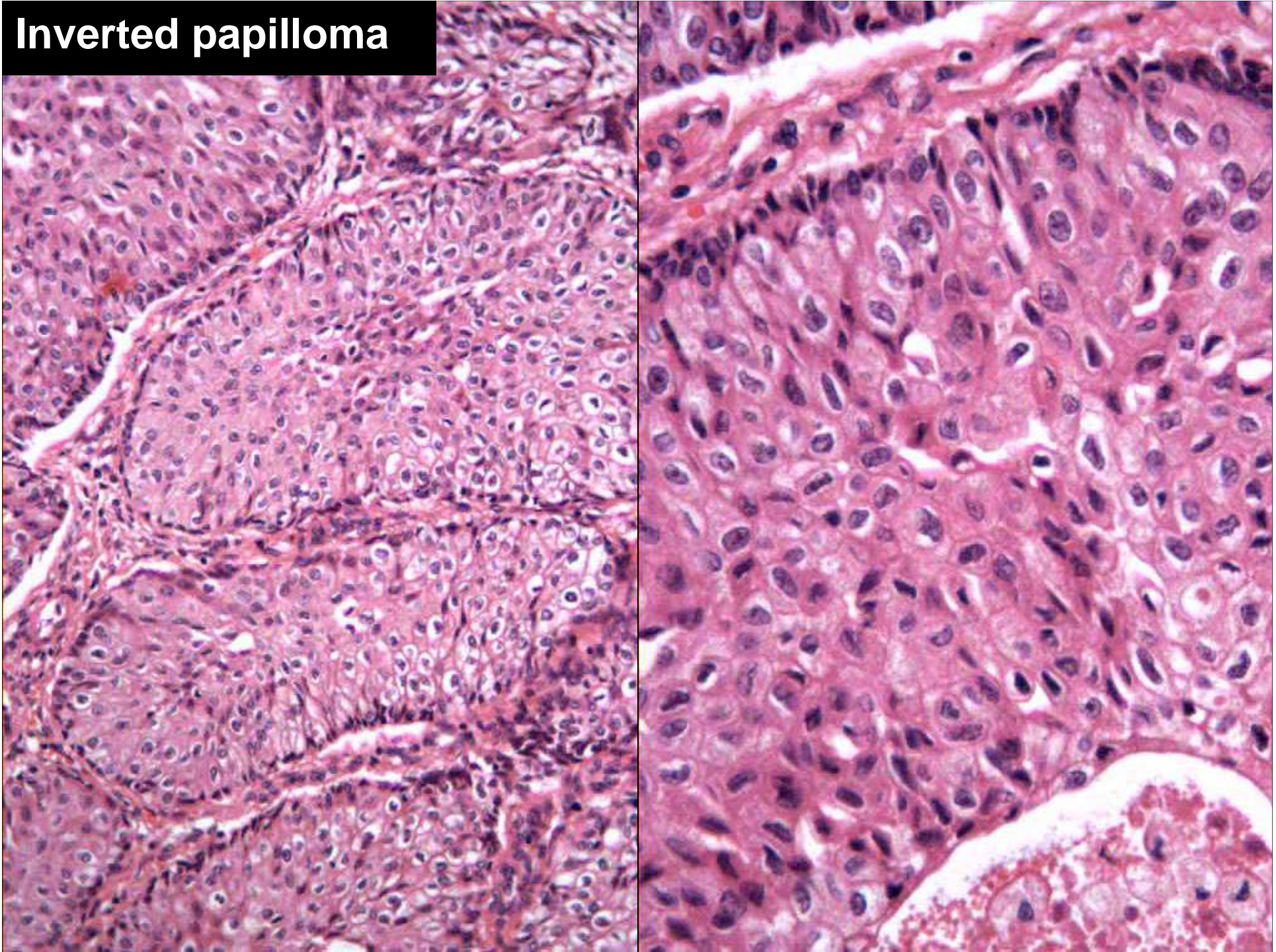
Inverted papilloma



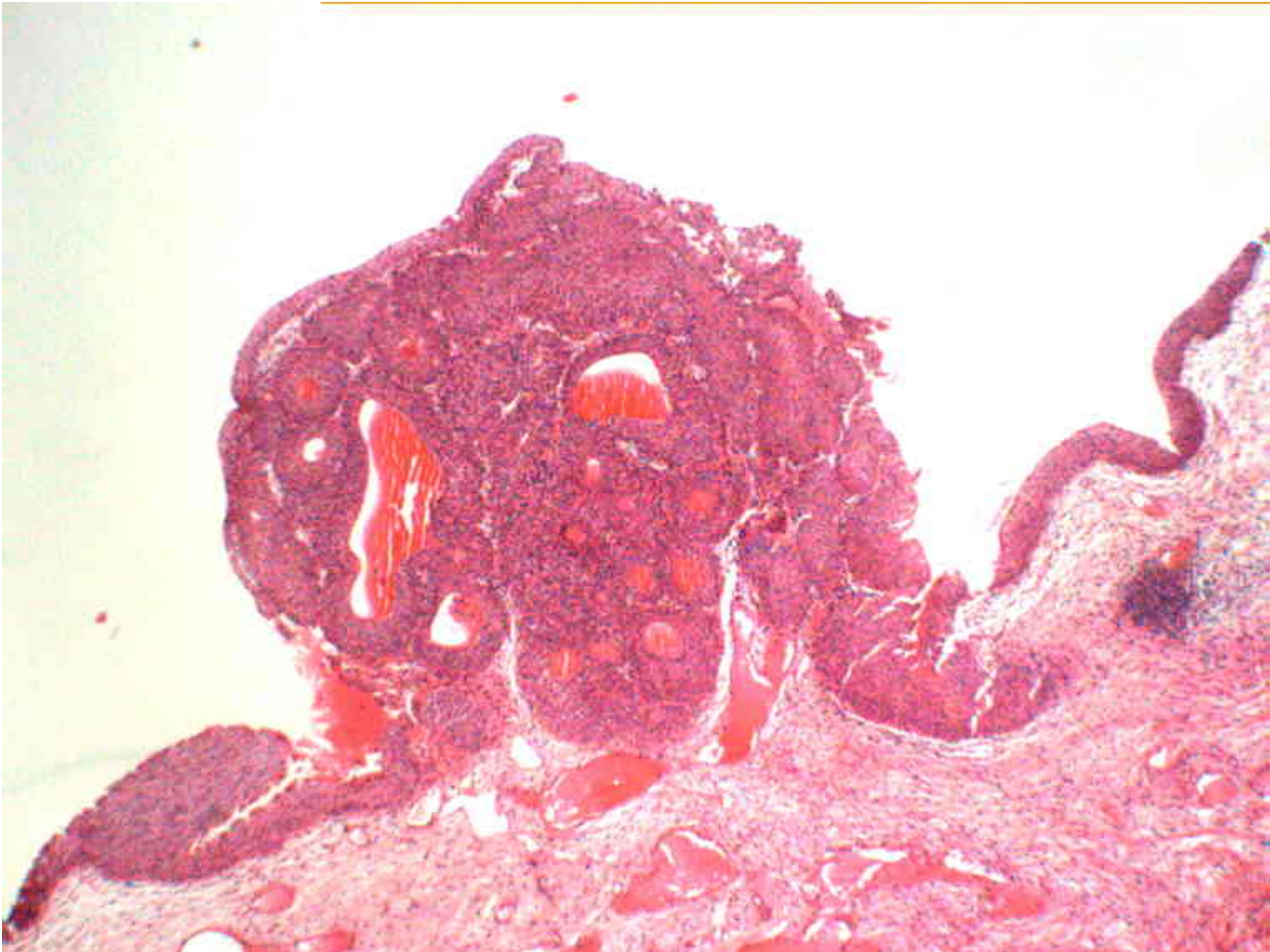
Inverted urothelial cell carcinoma



Inverted papilloma



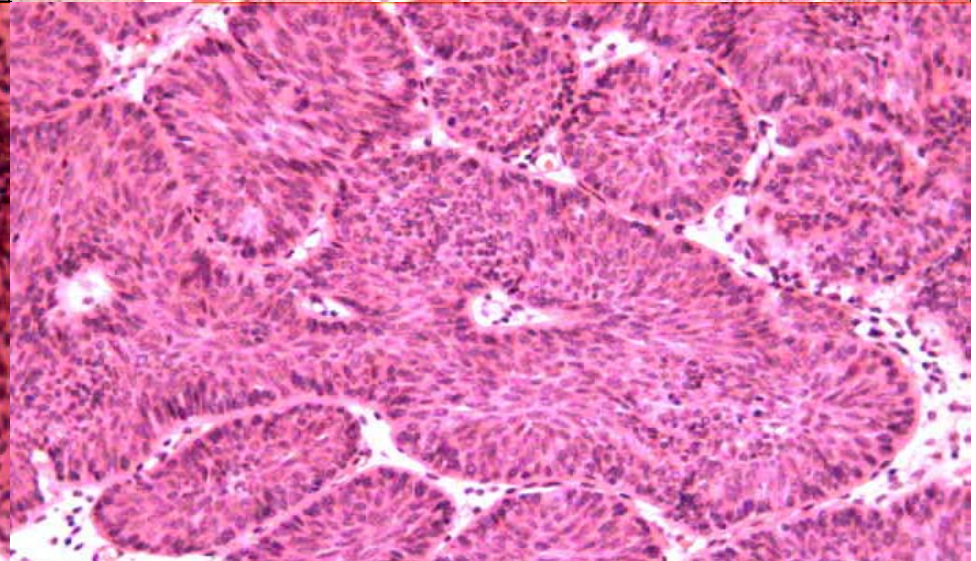
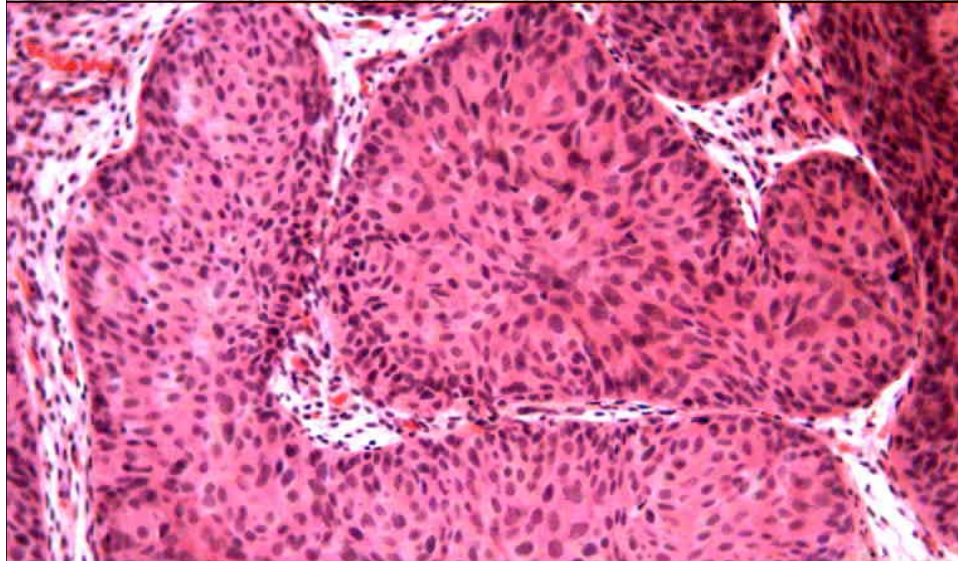
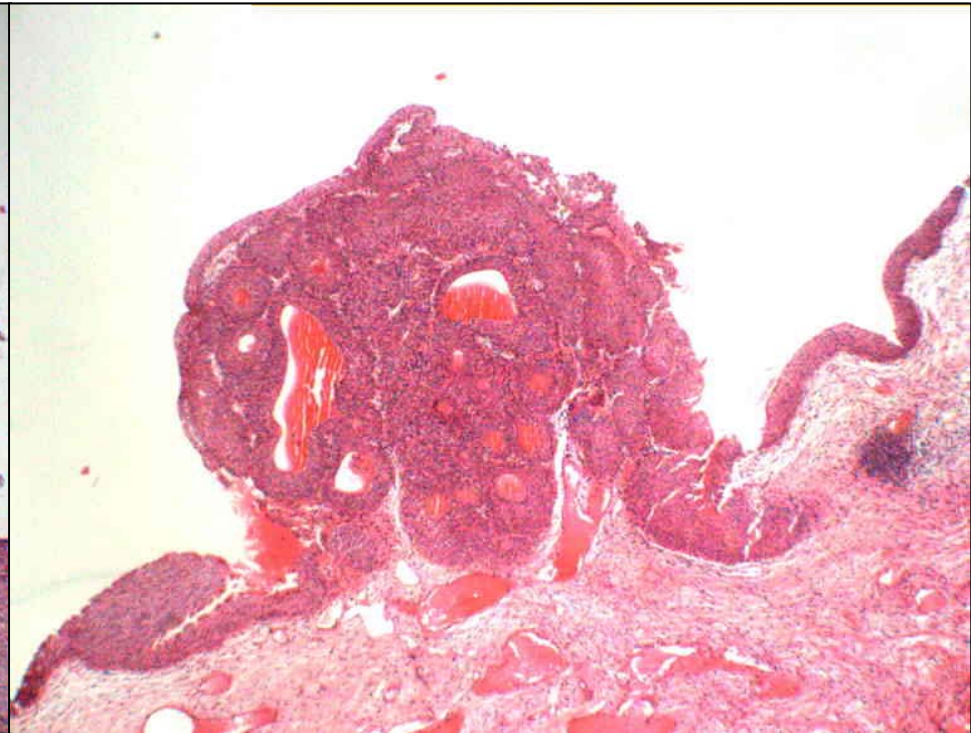




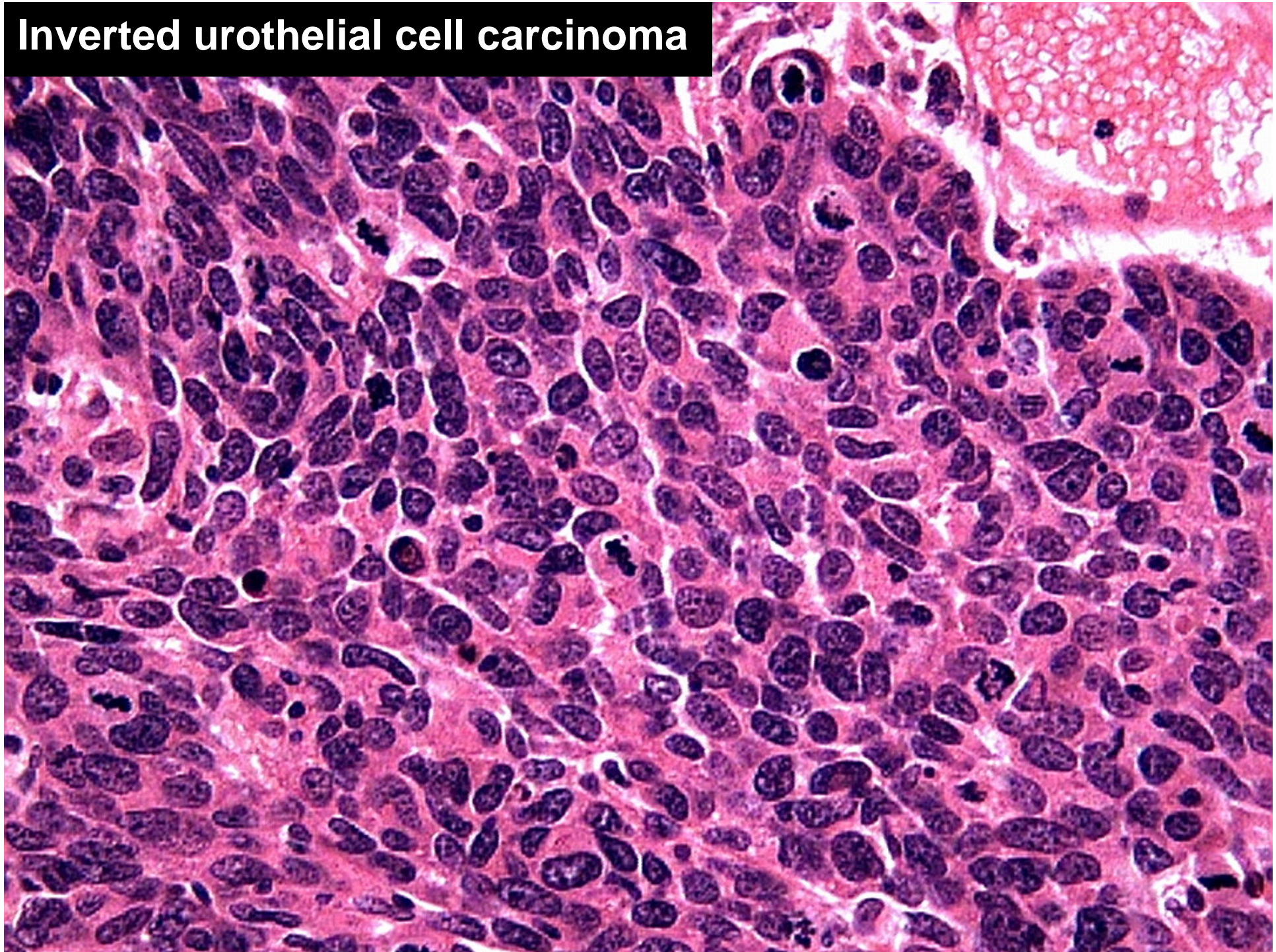
Inverted carcinoma



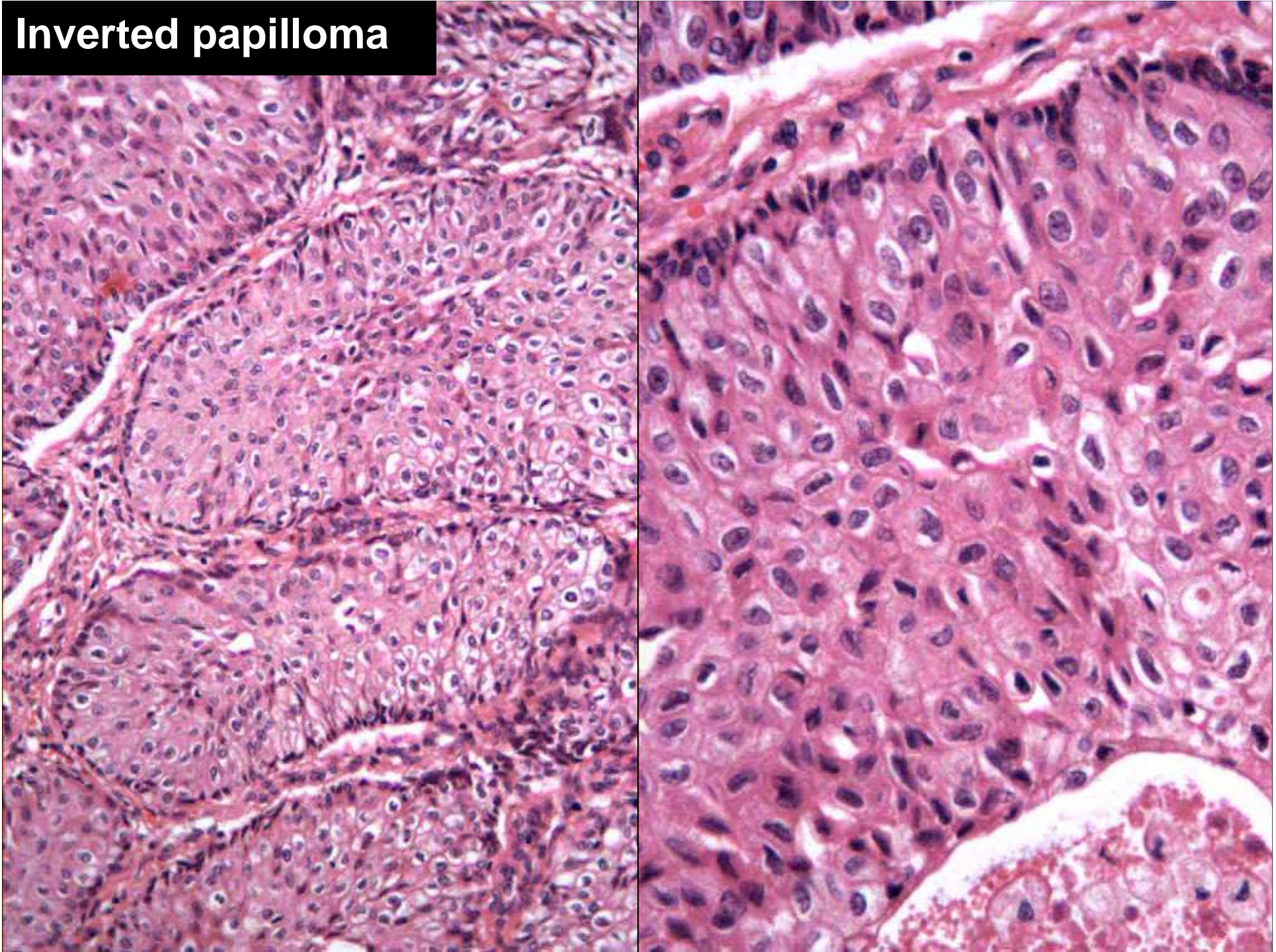
Inverted papilloma

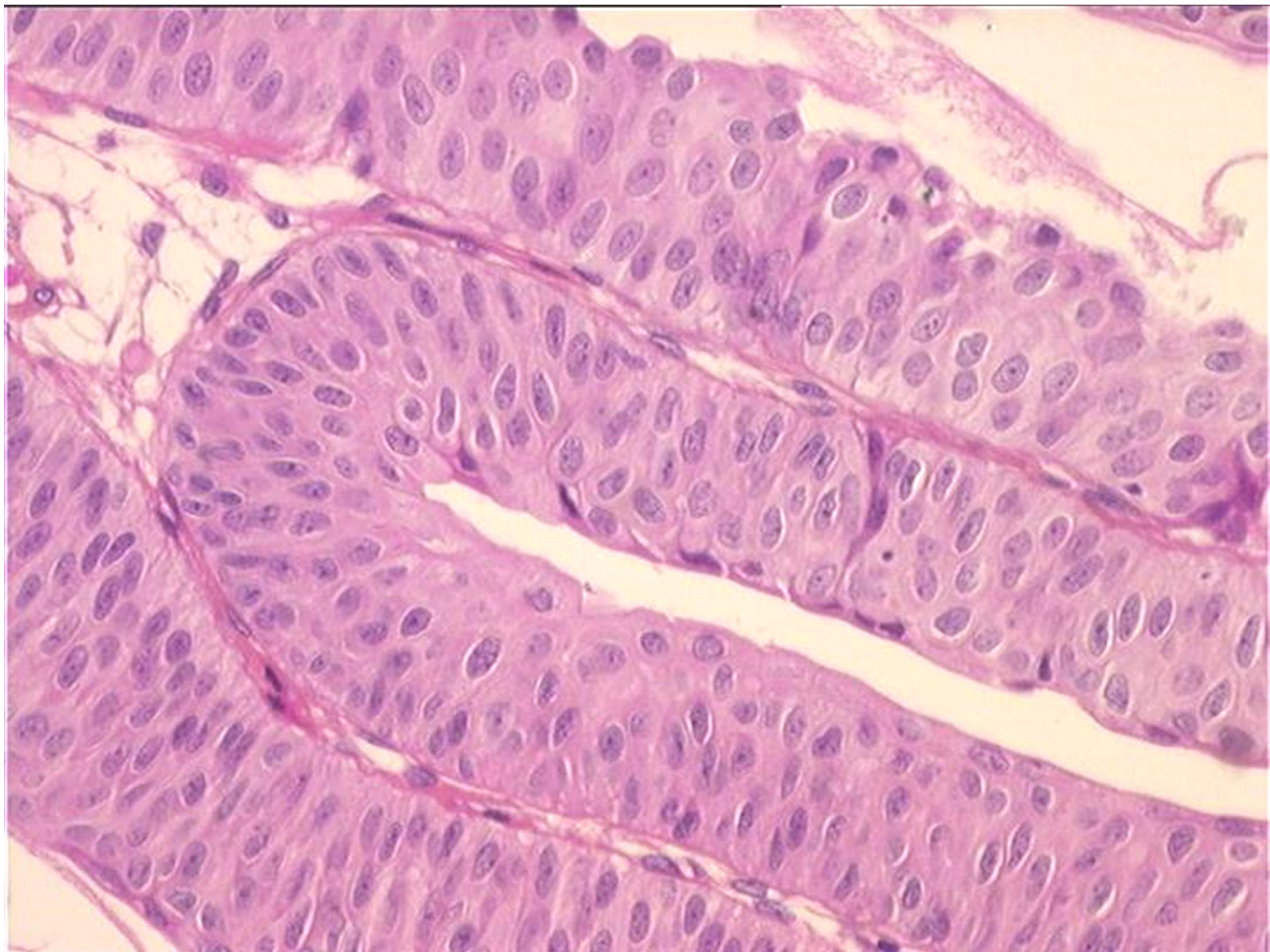


Inverted urothelial cell carcinoma



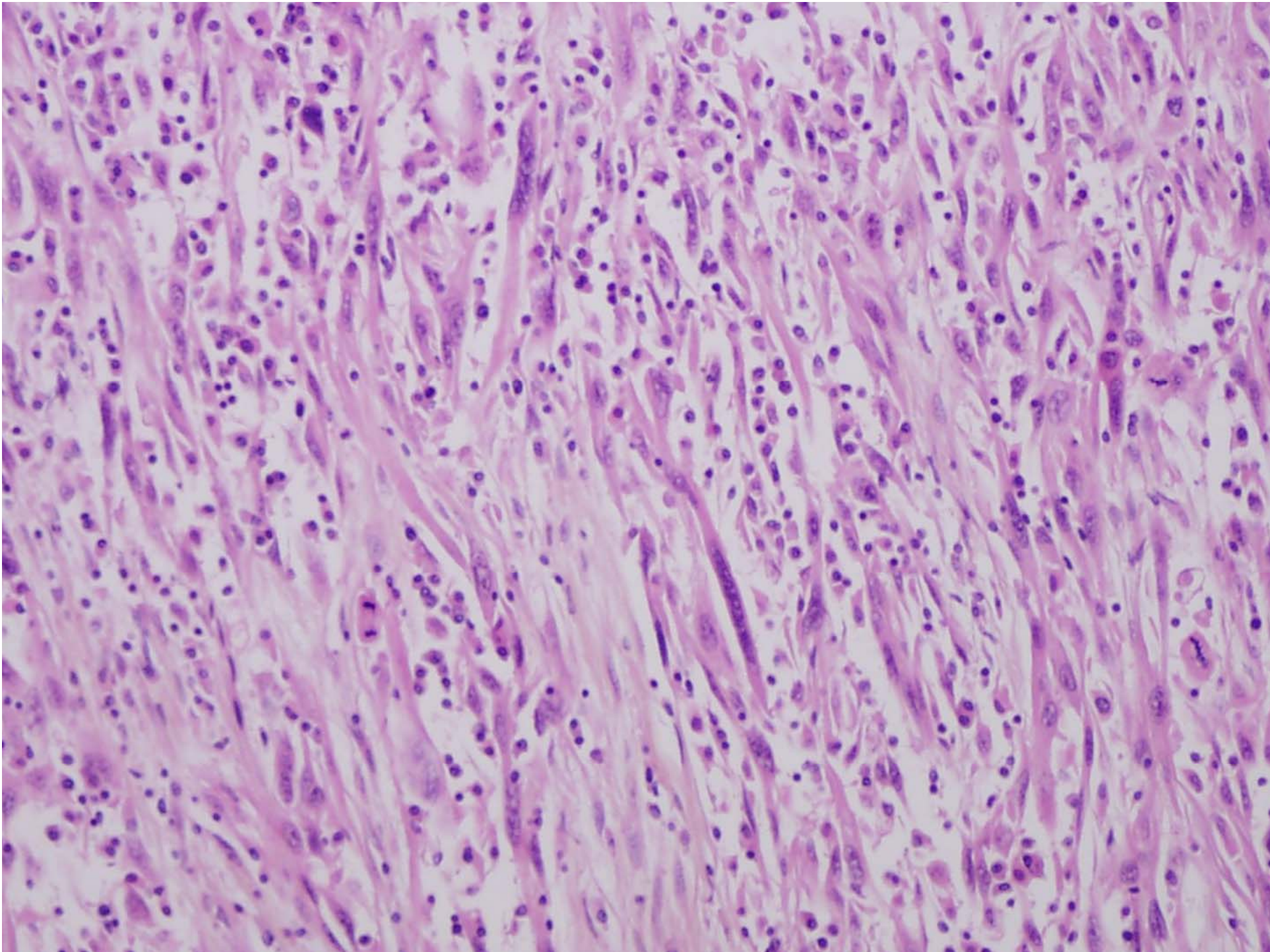
Inverted papilloma

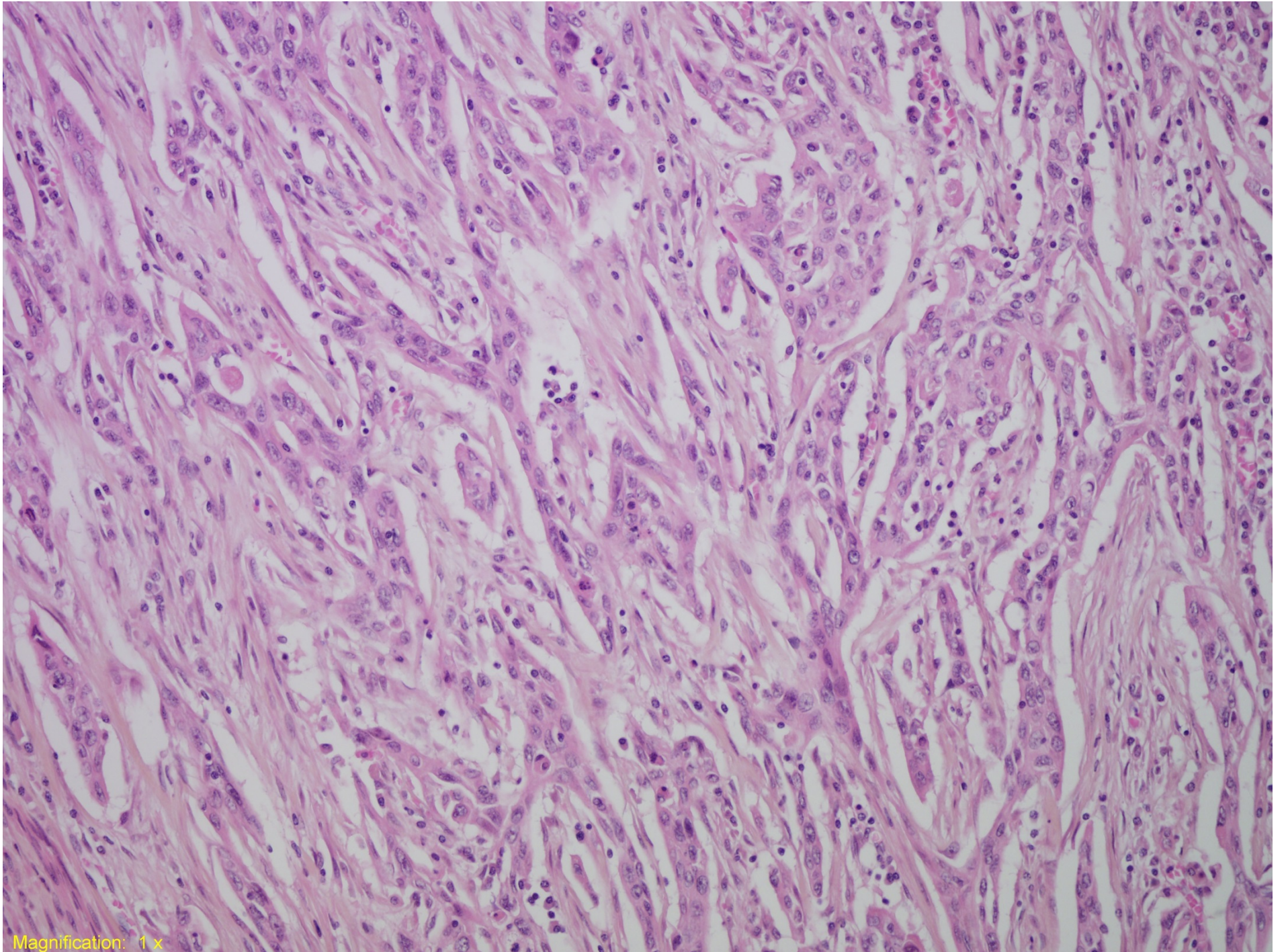




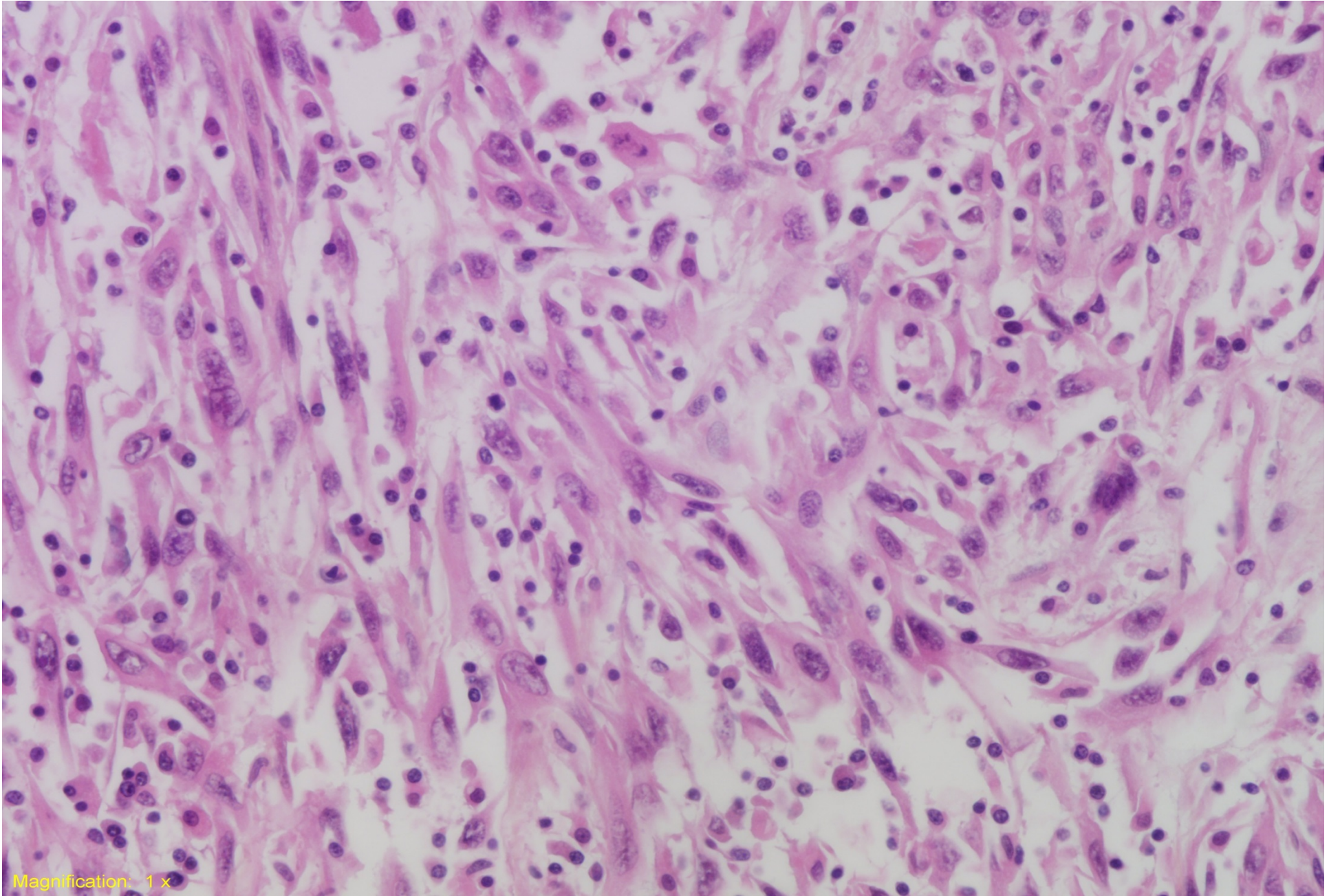
Papilloma (no hyperplasia, no atypia)

spindel cell pattern

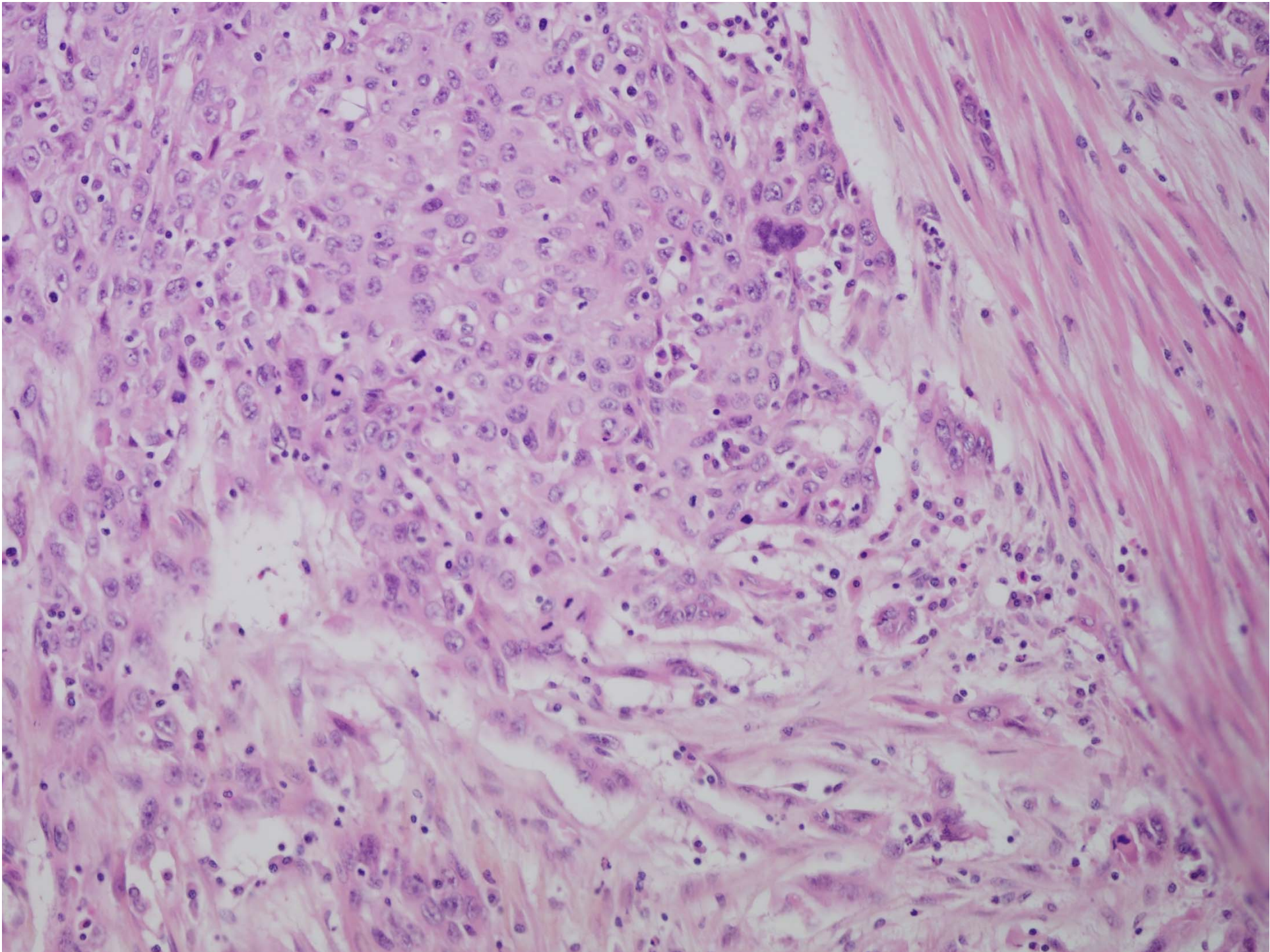




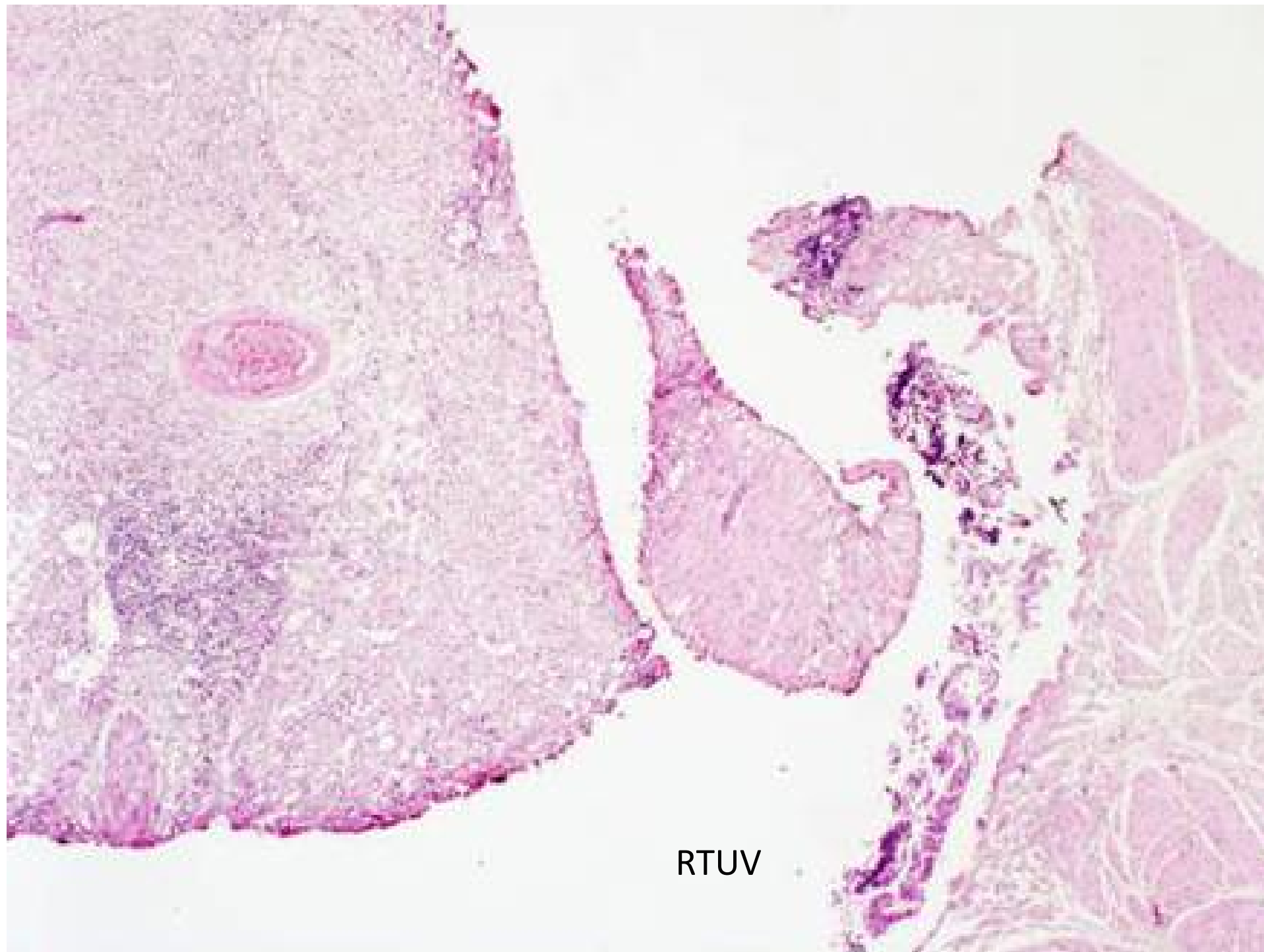
Magnification: 1 x



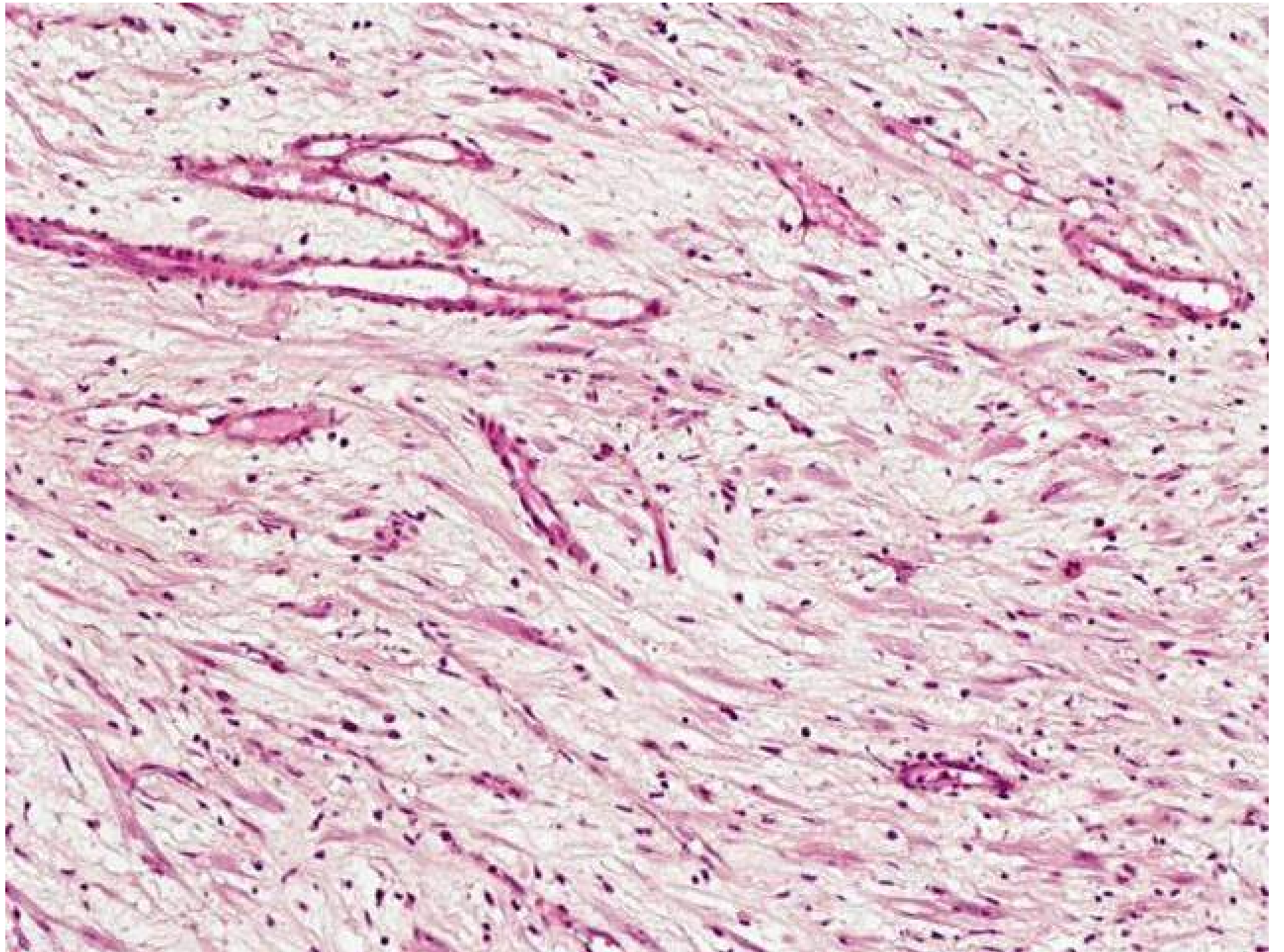
Magnification: 1 x

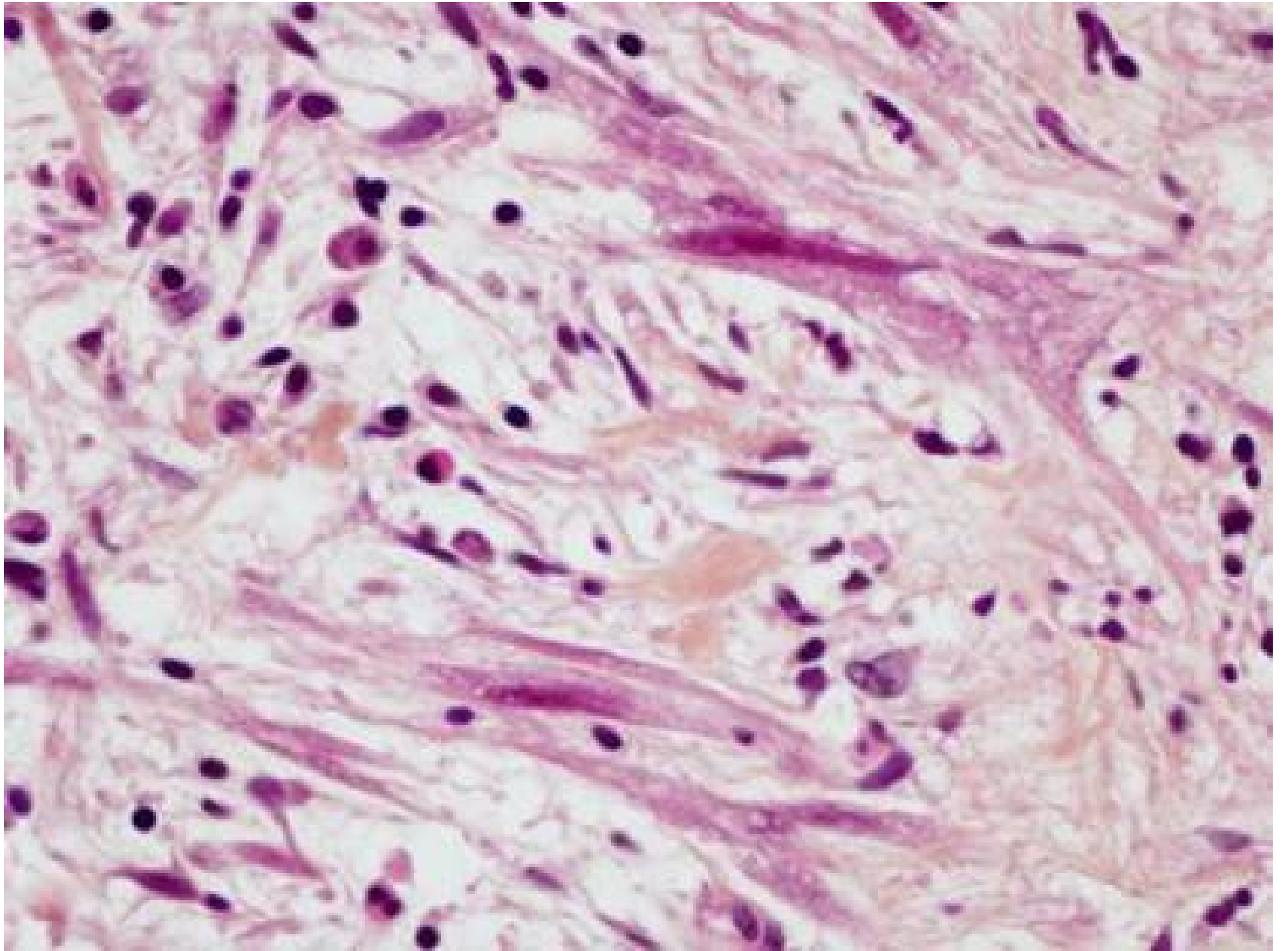


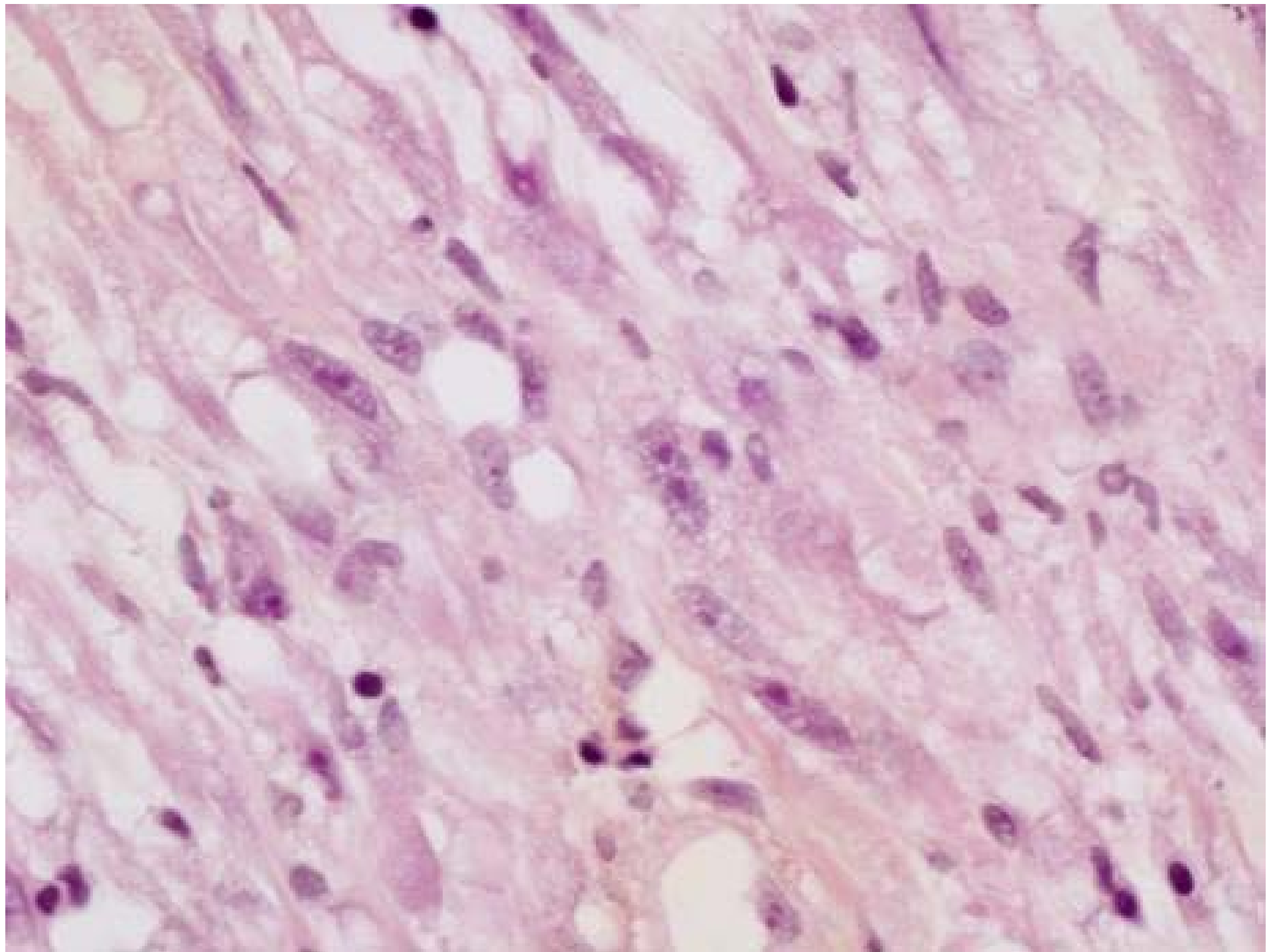
Sarcomatoid carcinoma

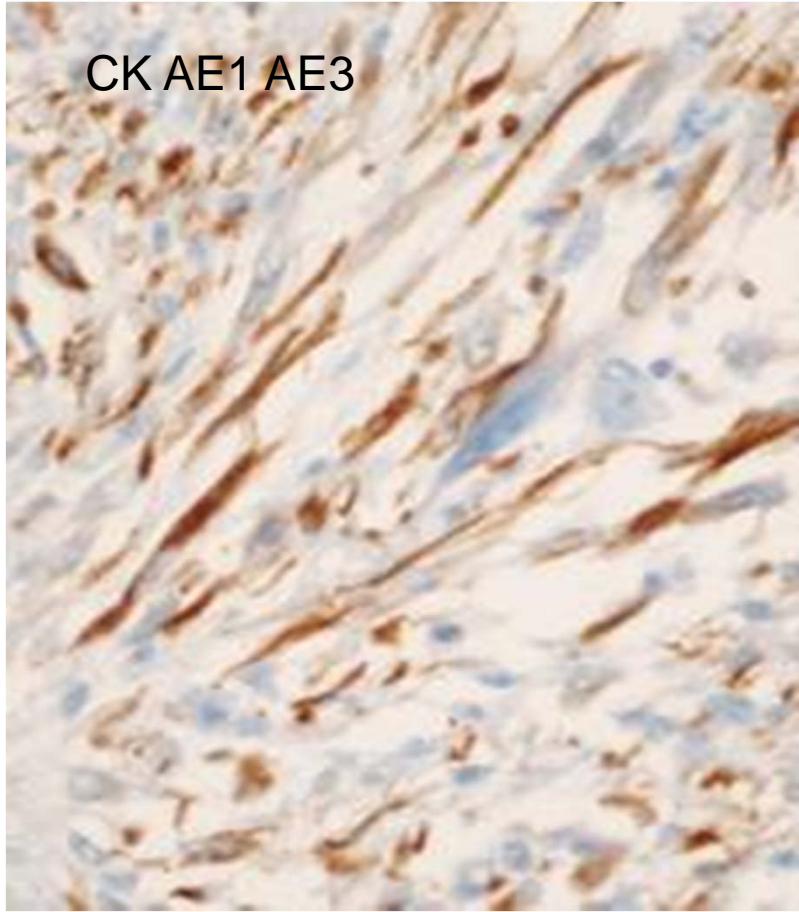
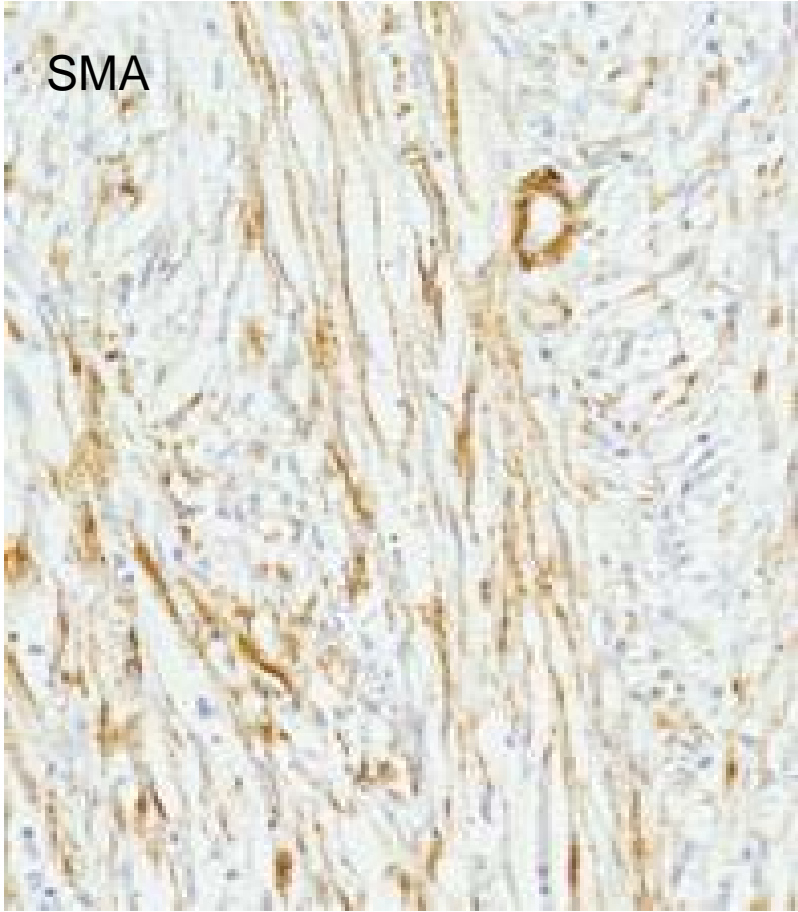


RTUV

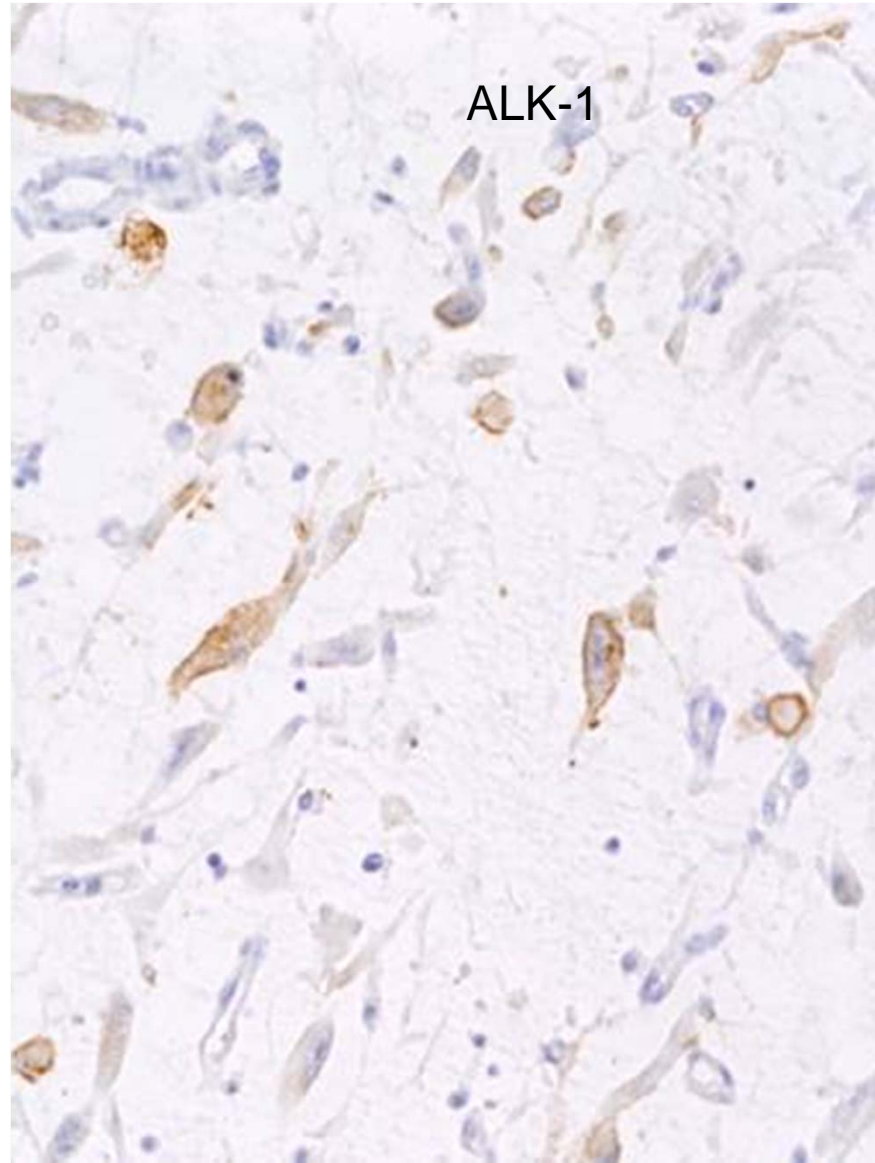






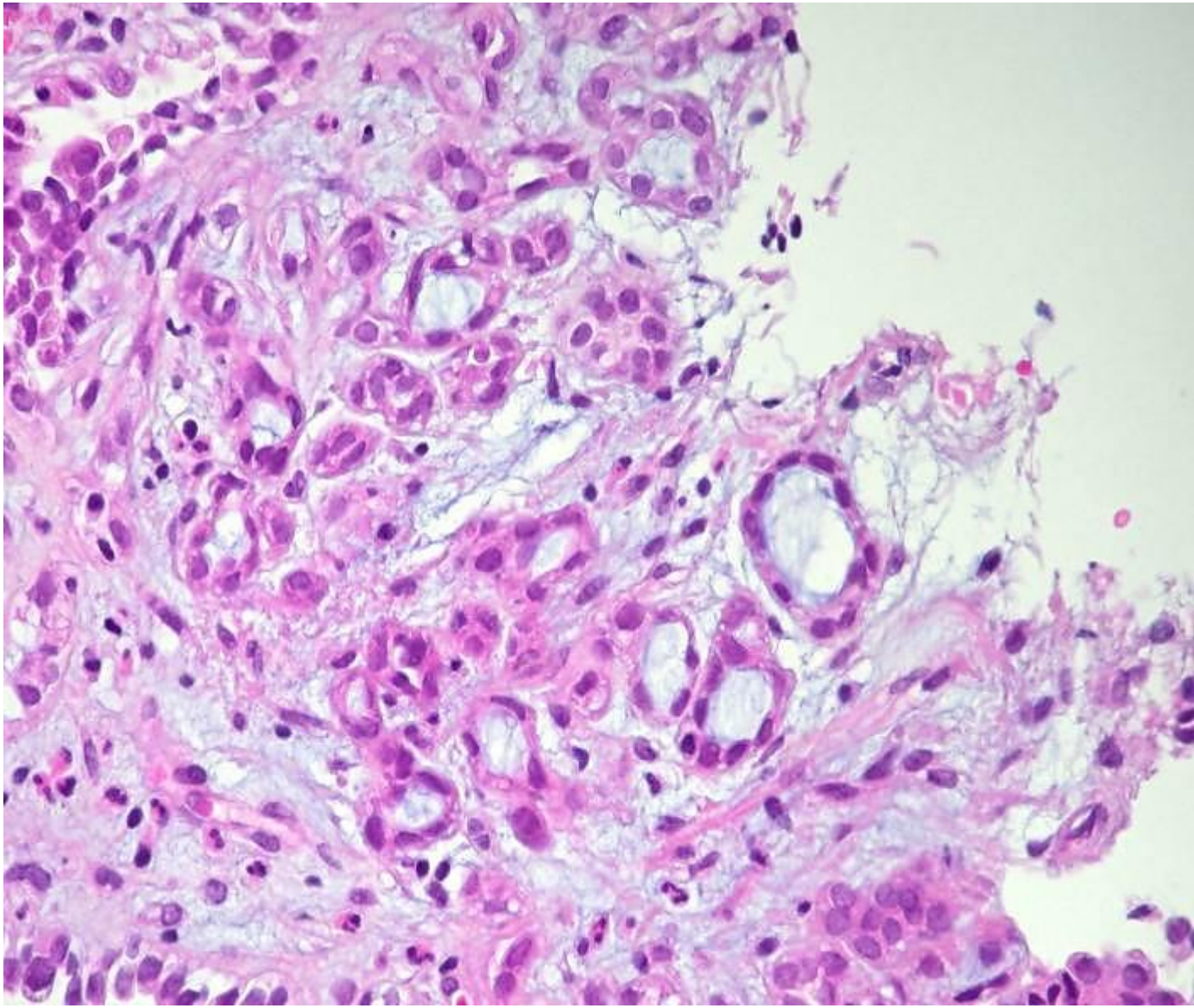


ALK-1



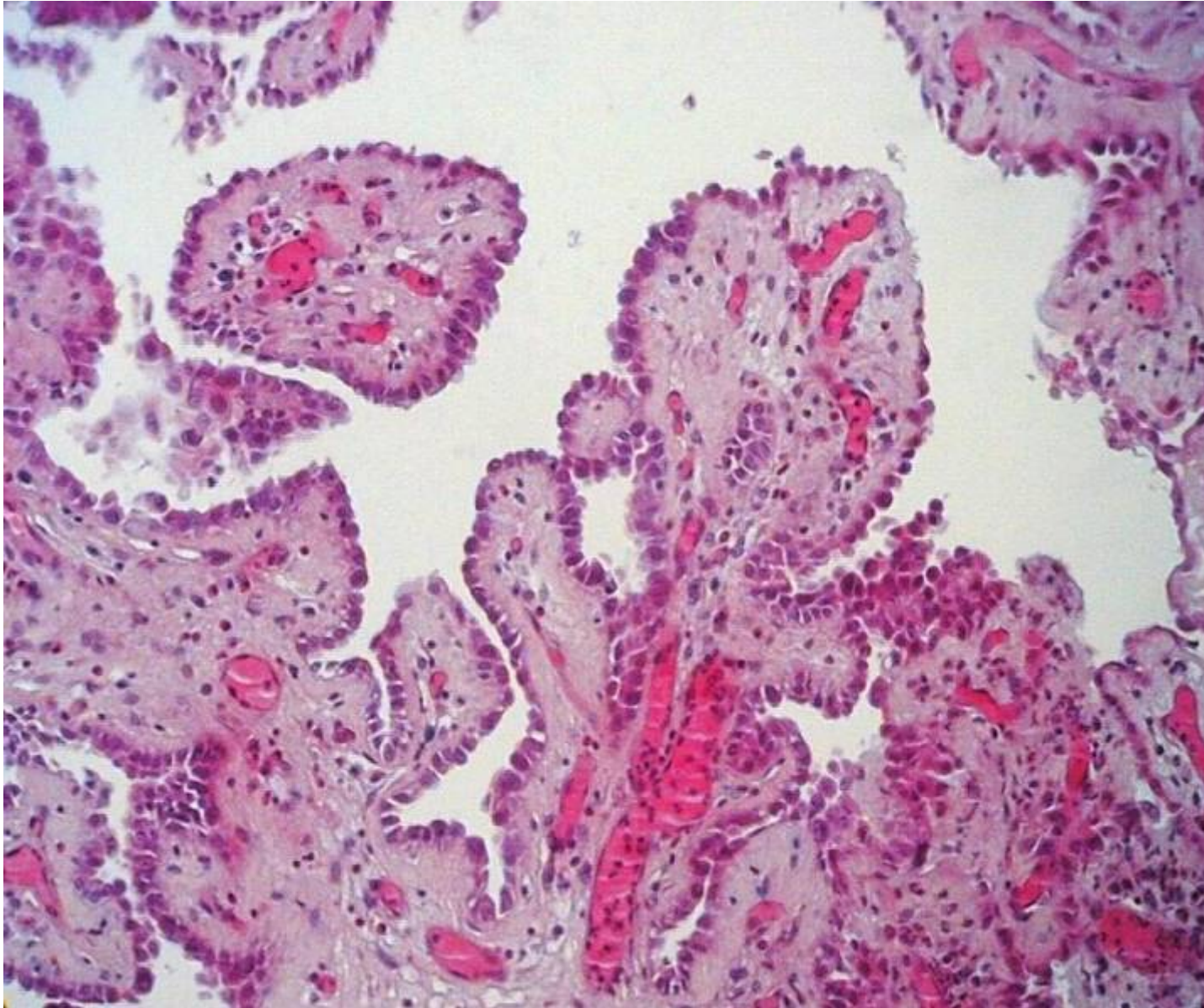
Myofibroblastic proliferation

Glandular pattern



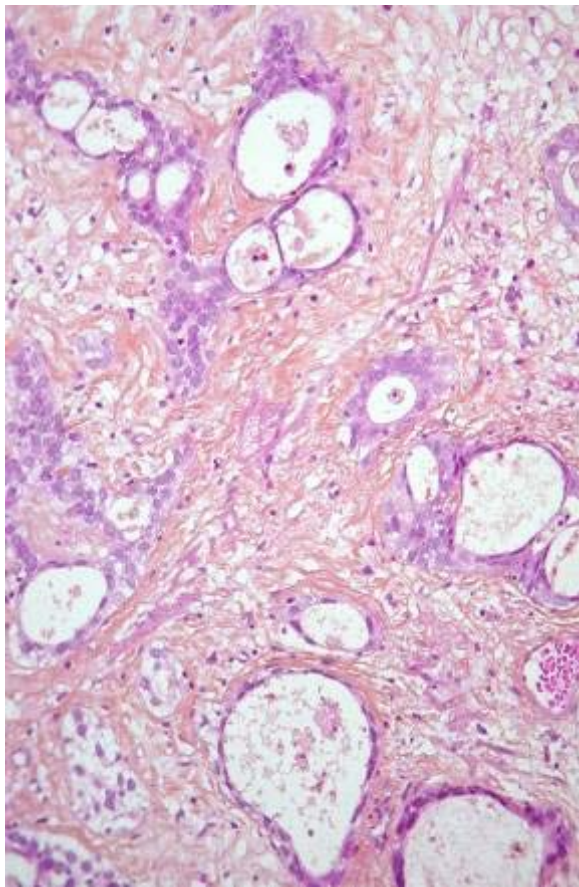
Nephrogenic metaplasia with tubular pattern

Nephrogenic metaplasia with papillary pattern



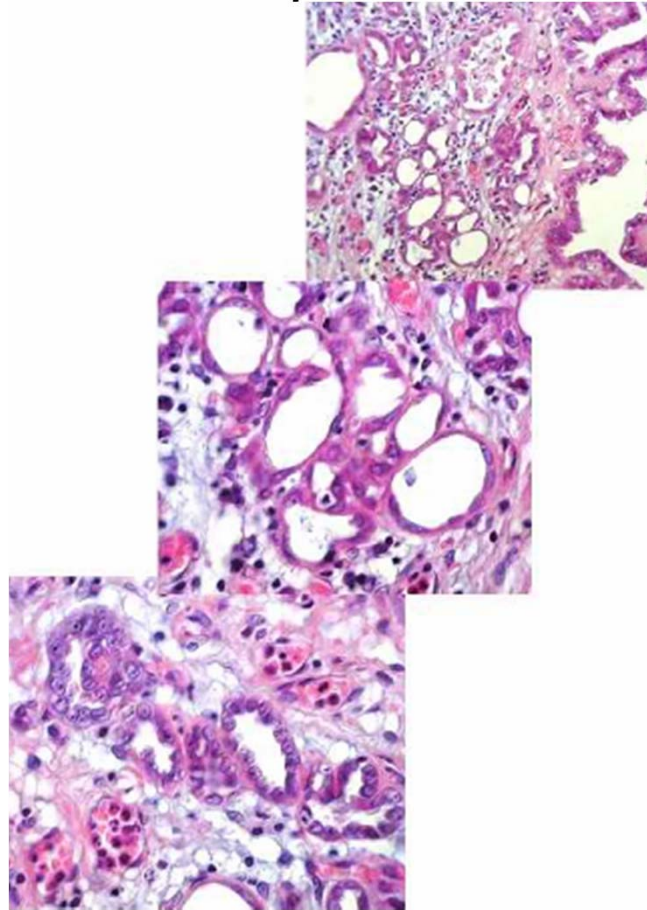
Differential diagnosis for the microcystic carcinoma

Microcystic carcinoma



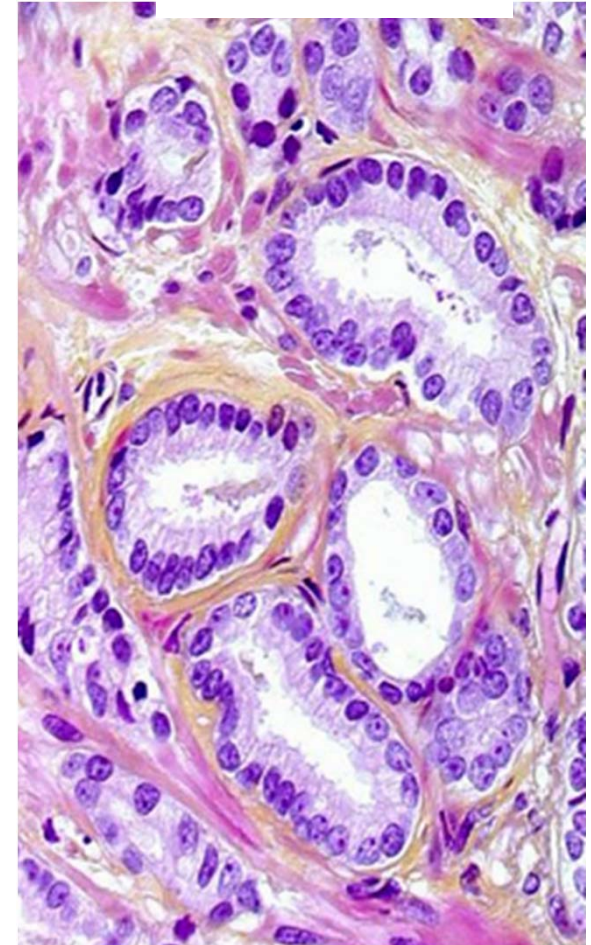
CK7+,p504s+/-

Nephrogenic metaplasia

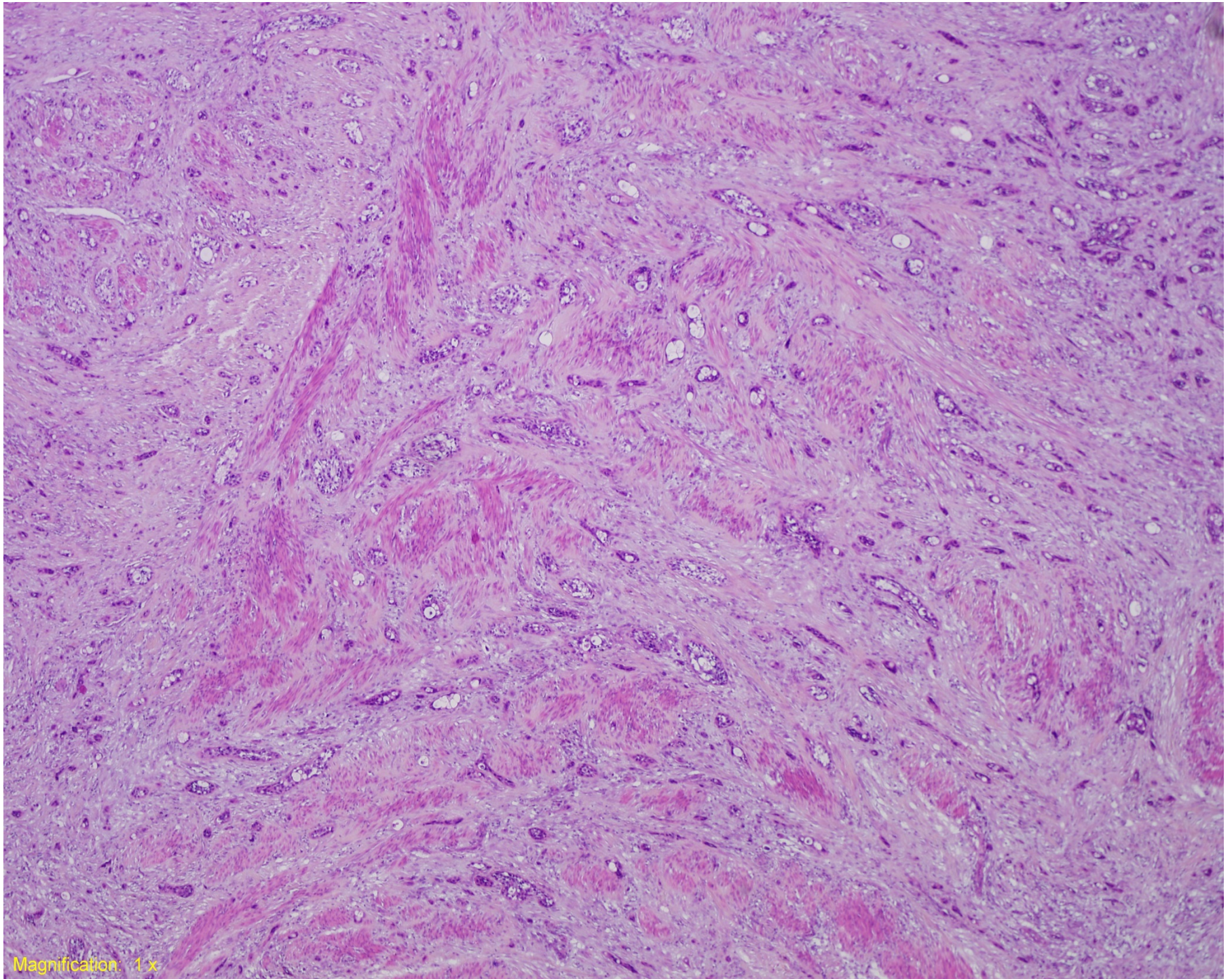


CK7+,p504s+

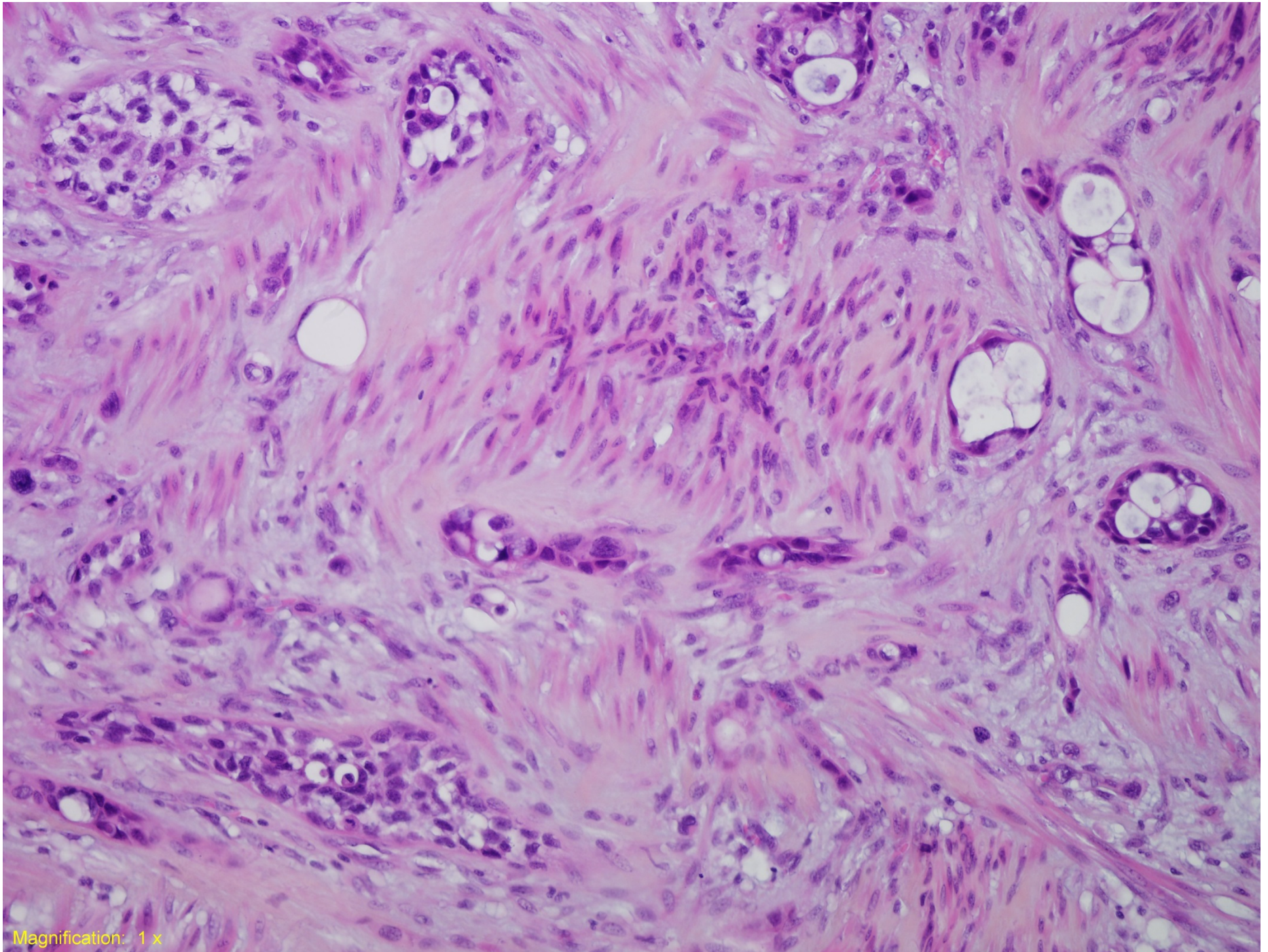
Prostate carcinoma



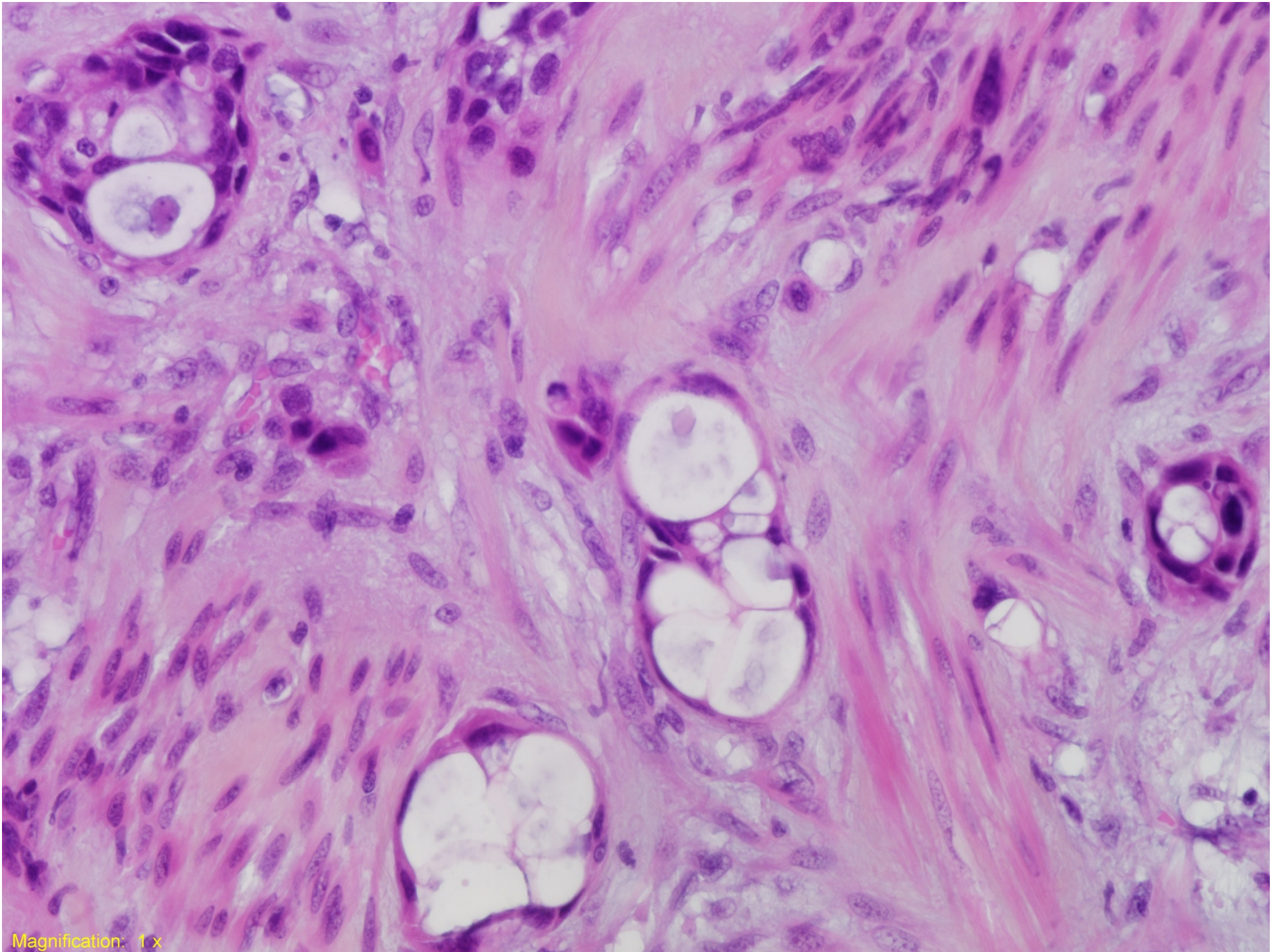
CK7-,p504s+



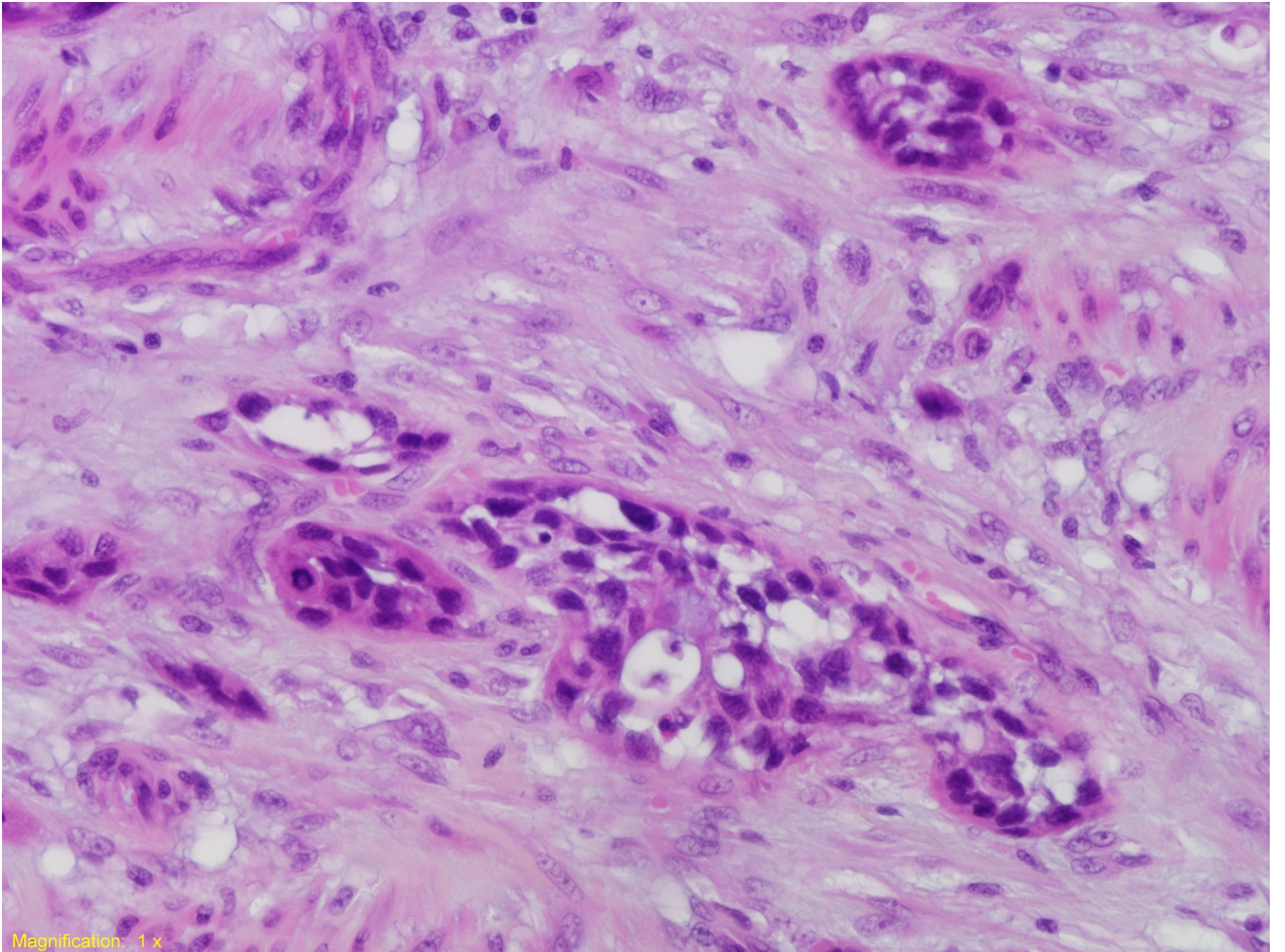
Magnification: 1 x



Magnification: 1 x

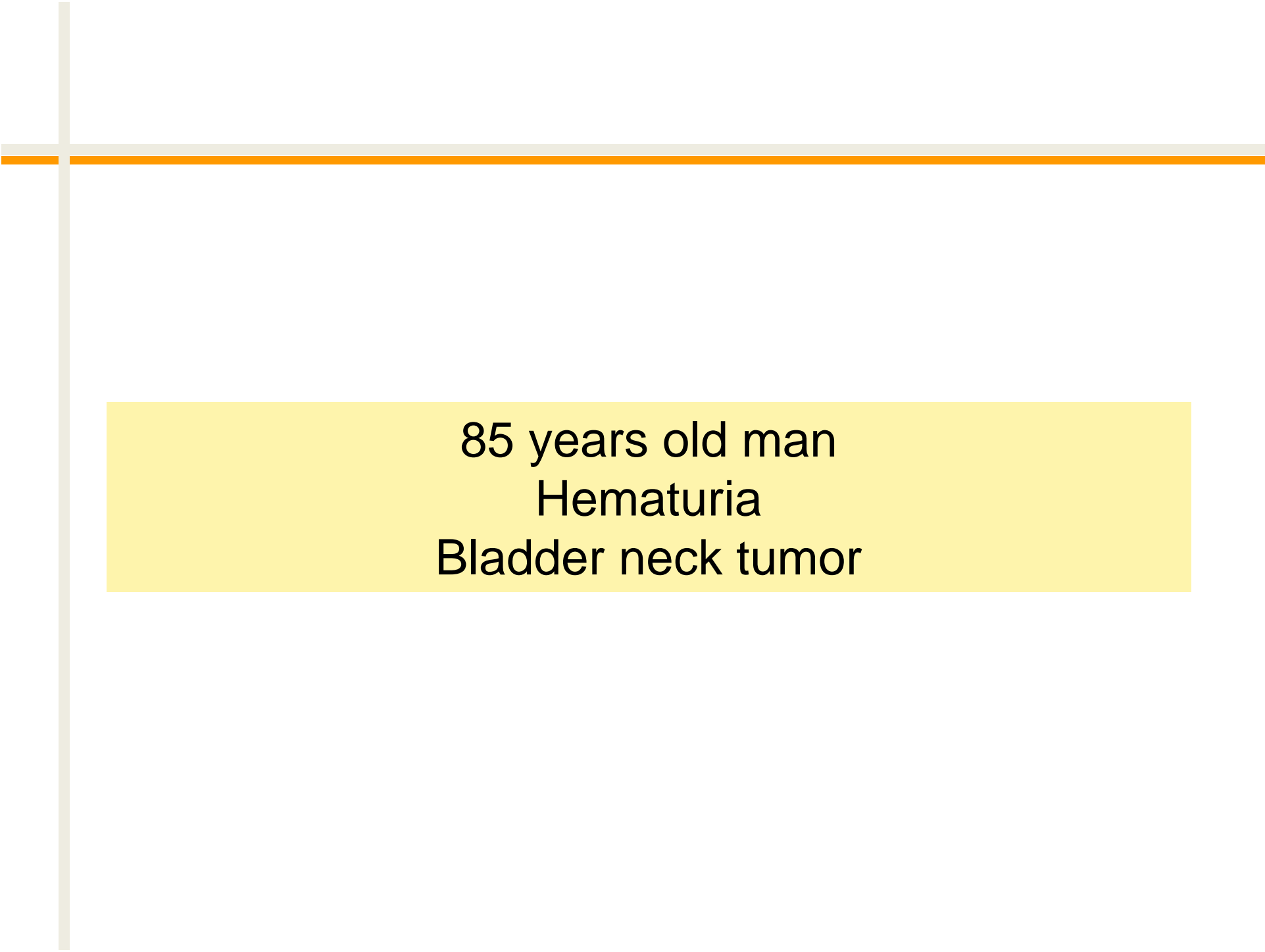


Magnification: 1x

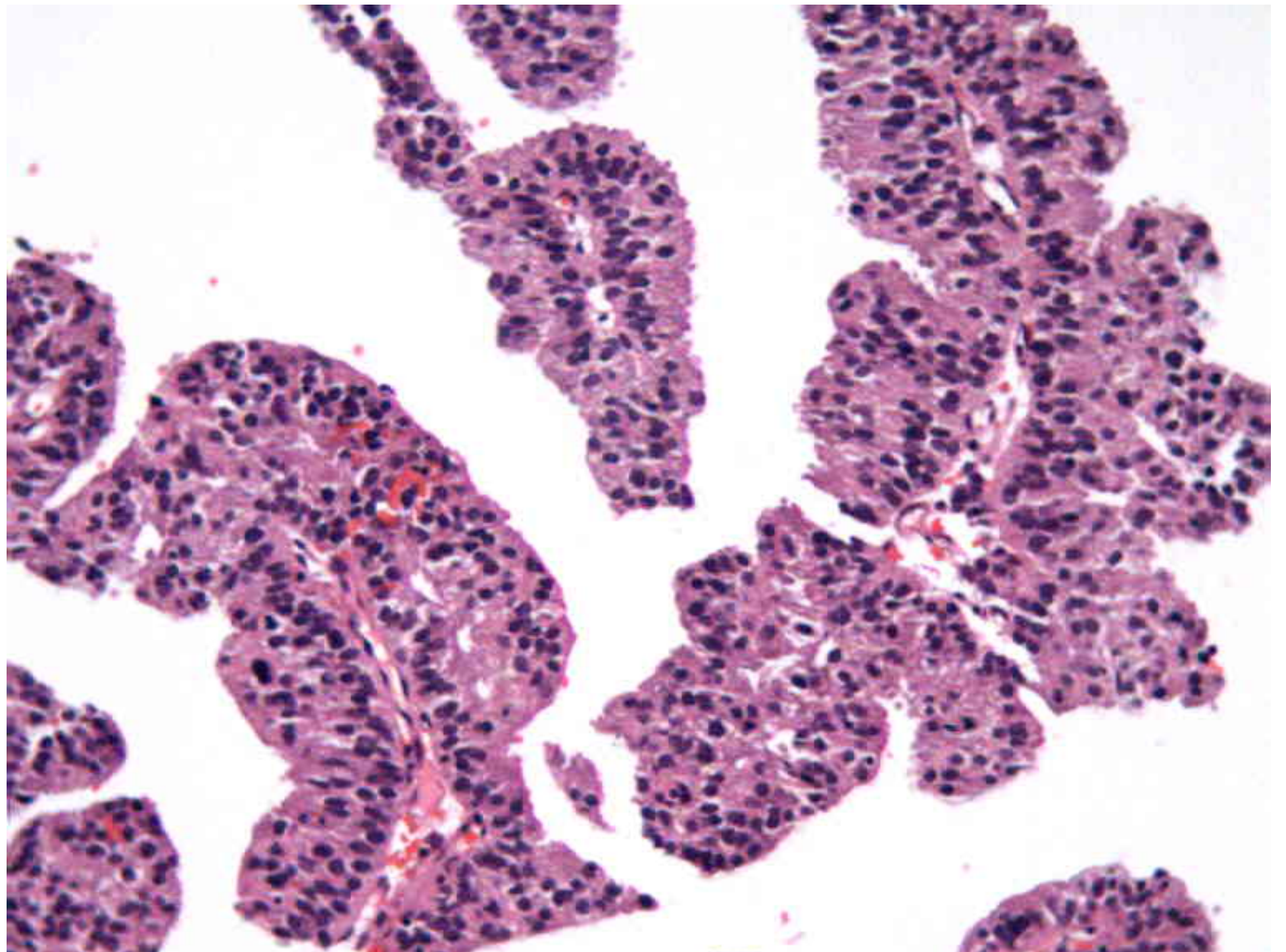


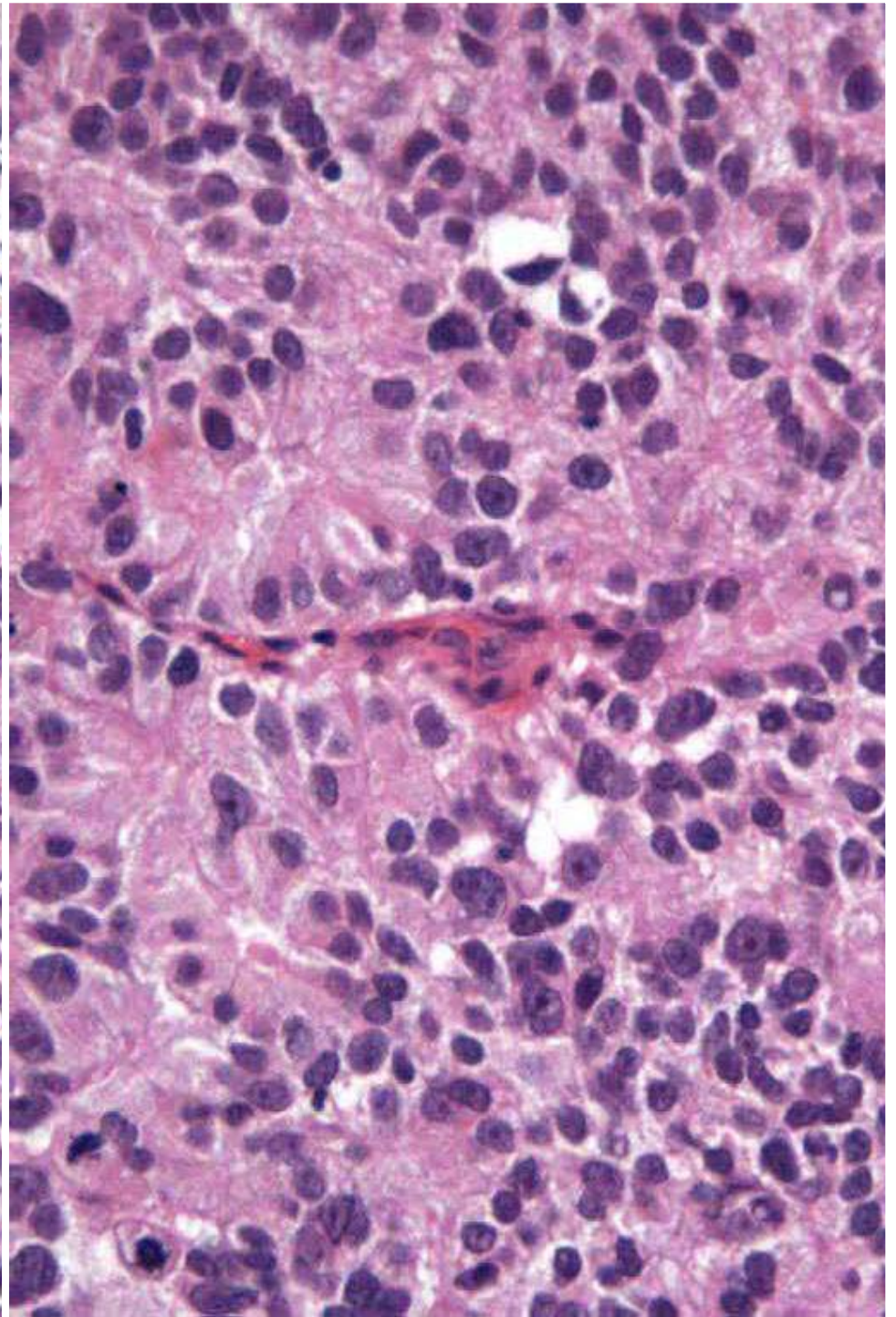
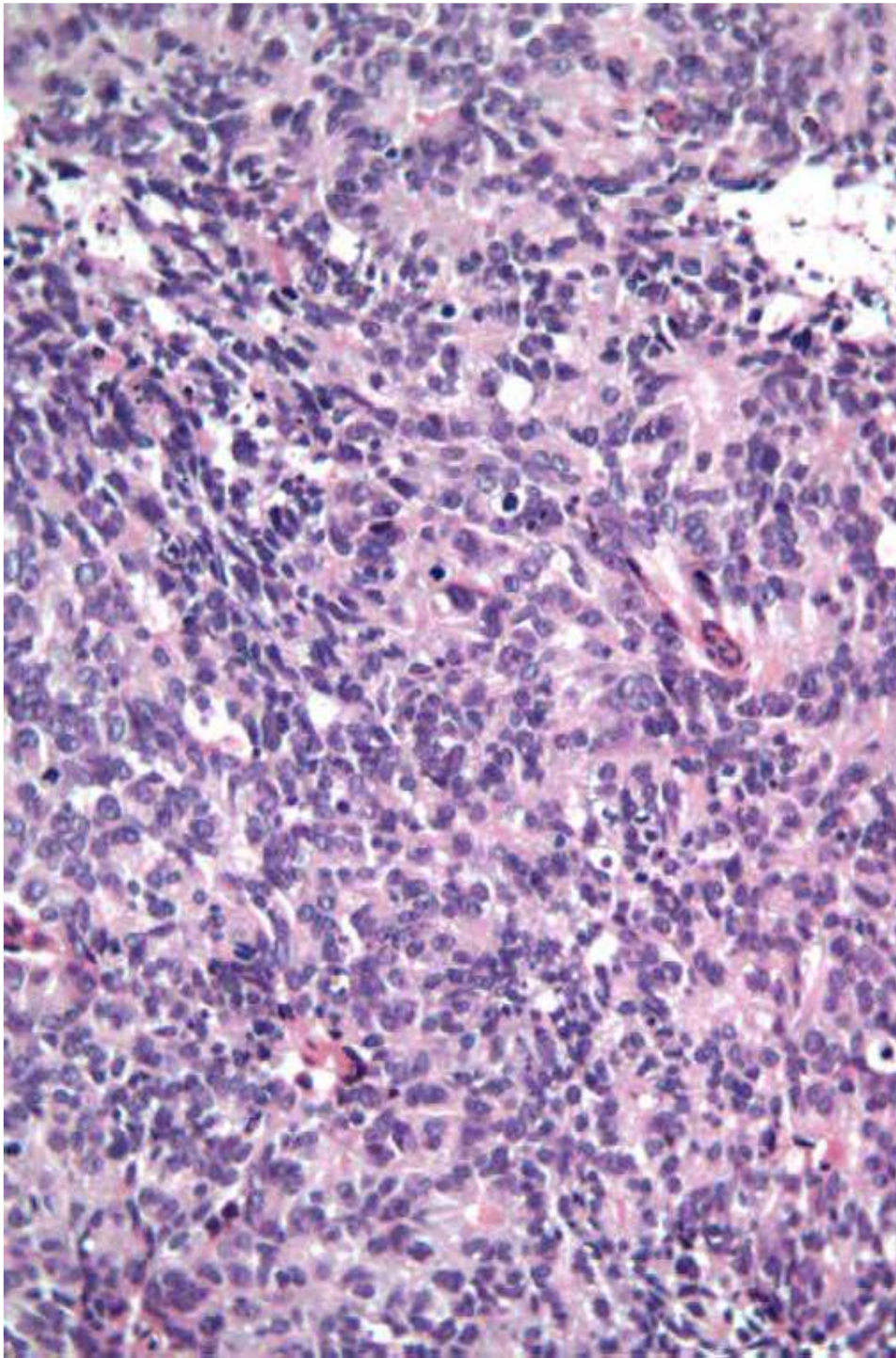
Magnification: 1 x

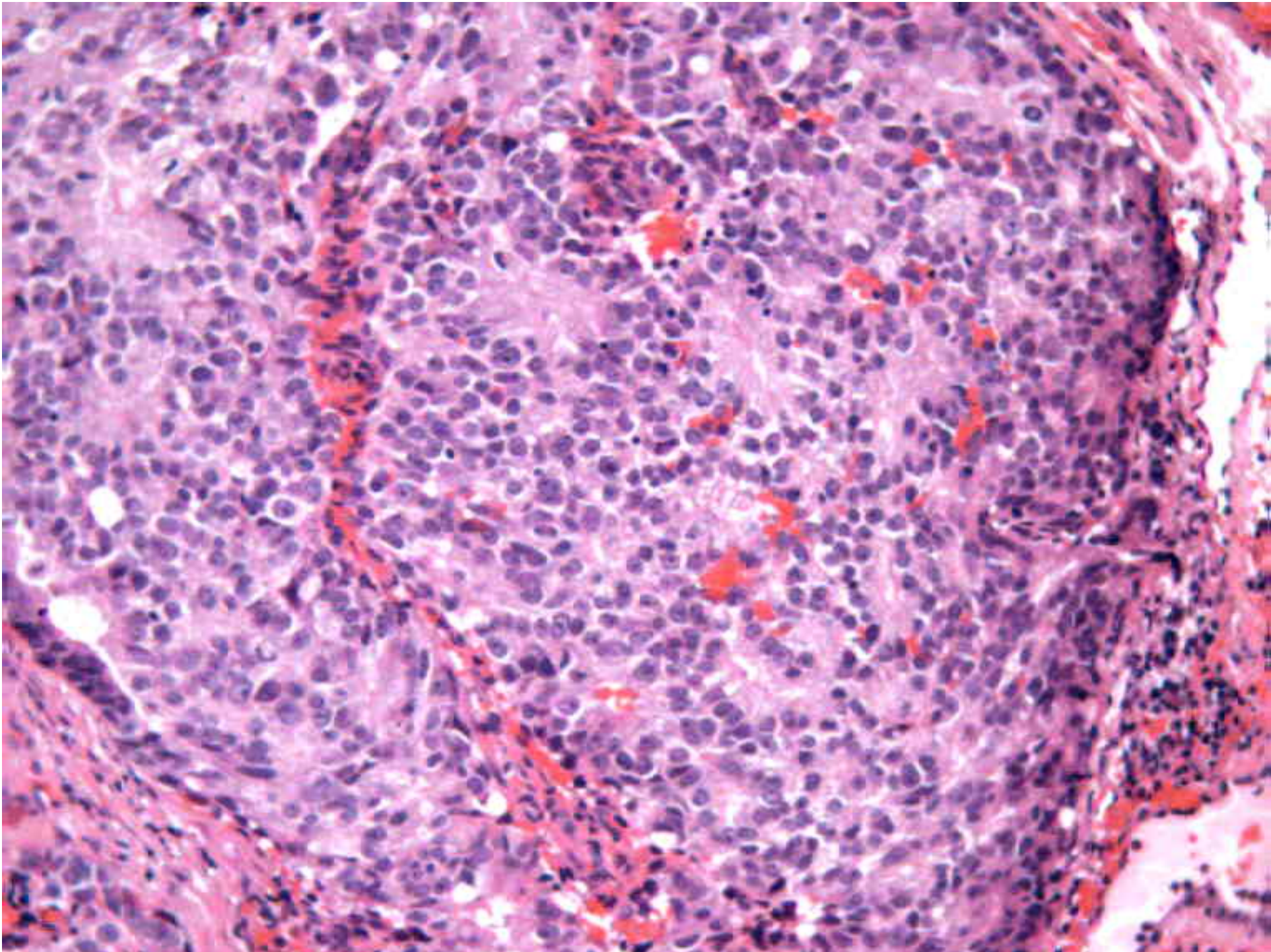
Microcystic carcinoma

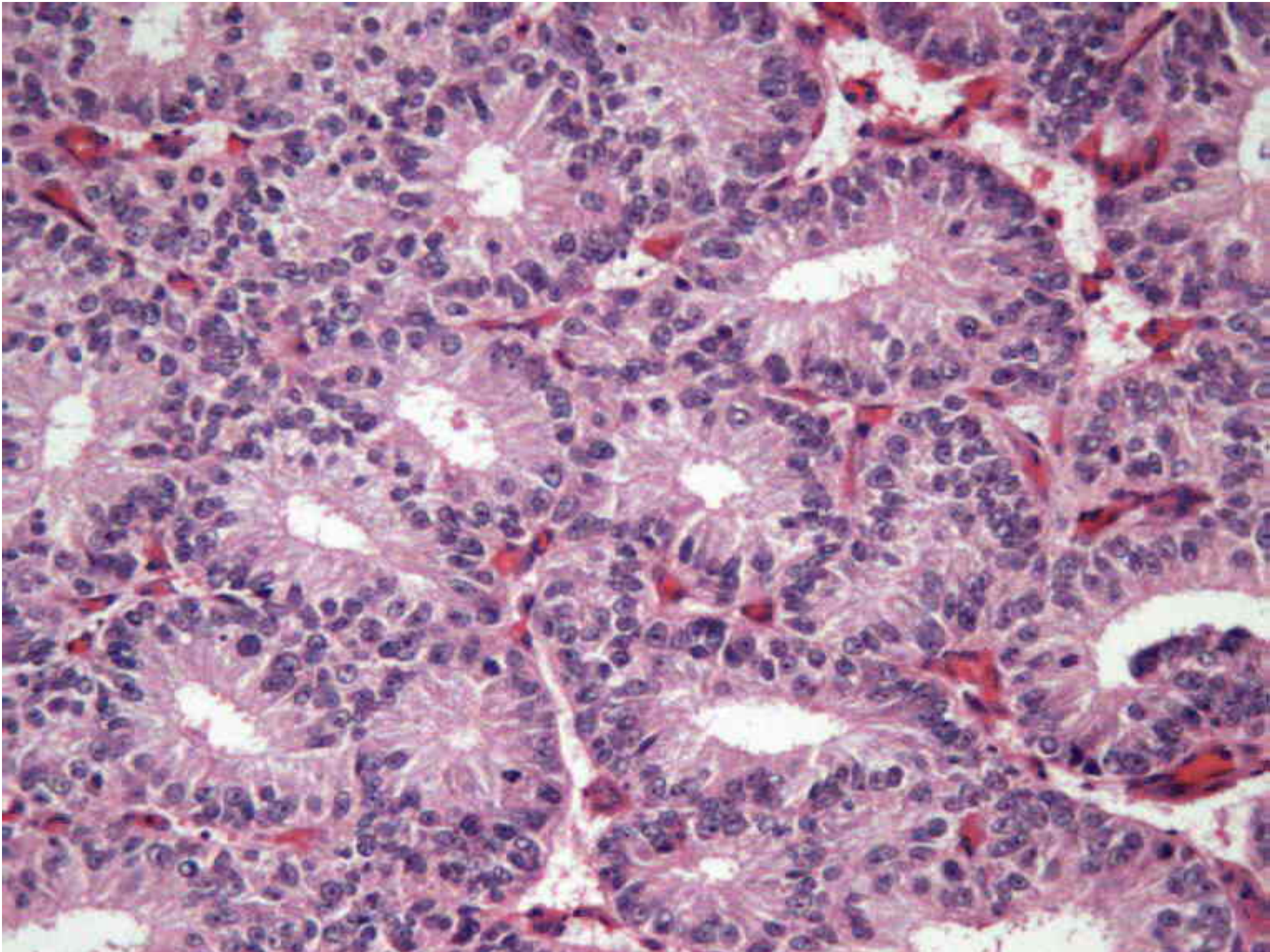


85 years old man
Hematuria
Bladder neck tumor



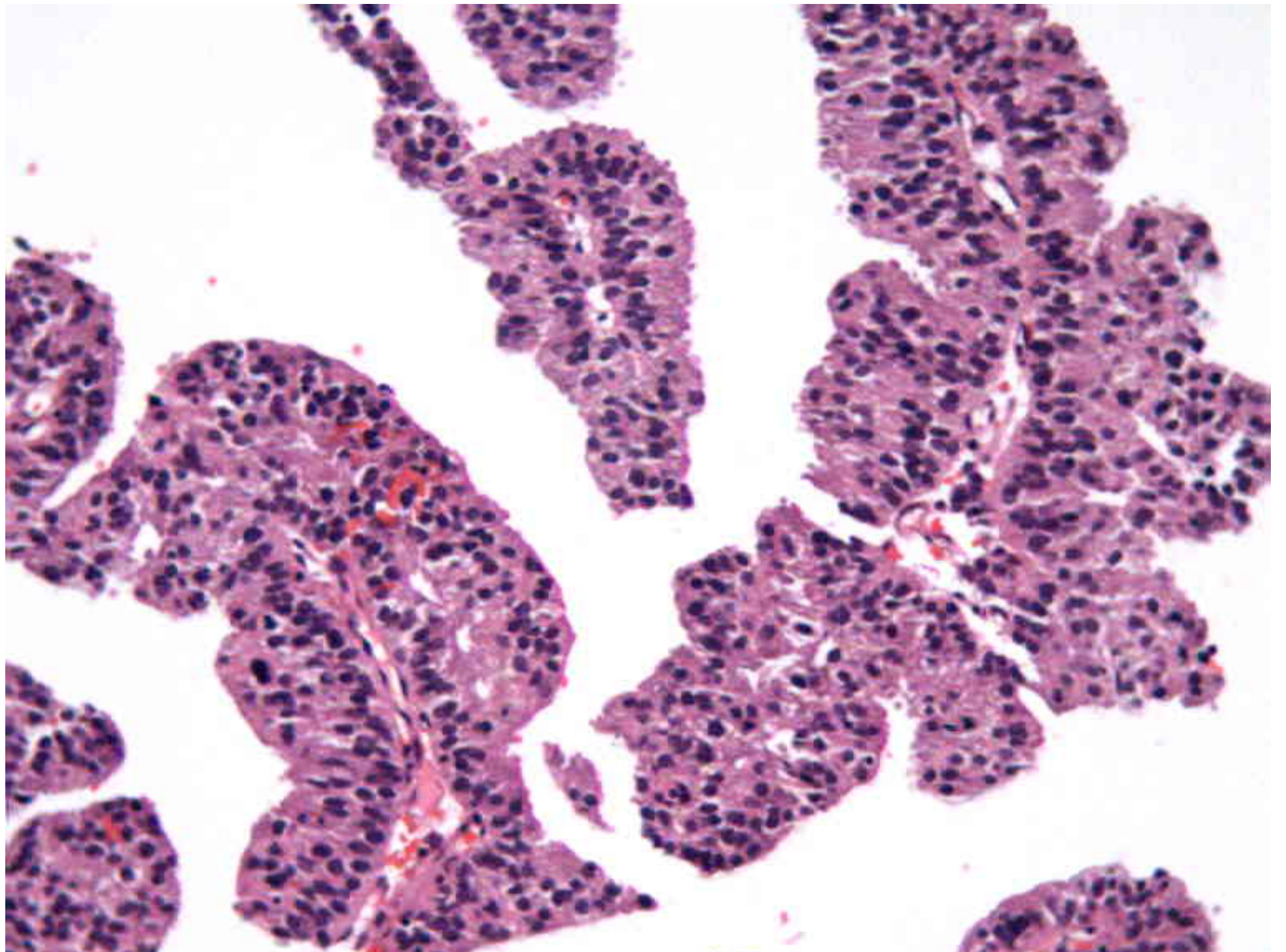


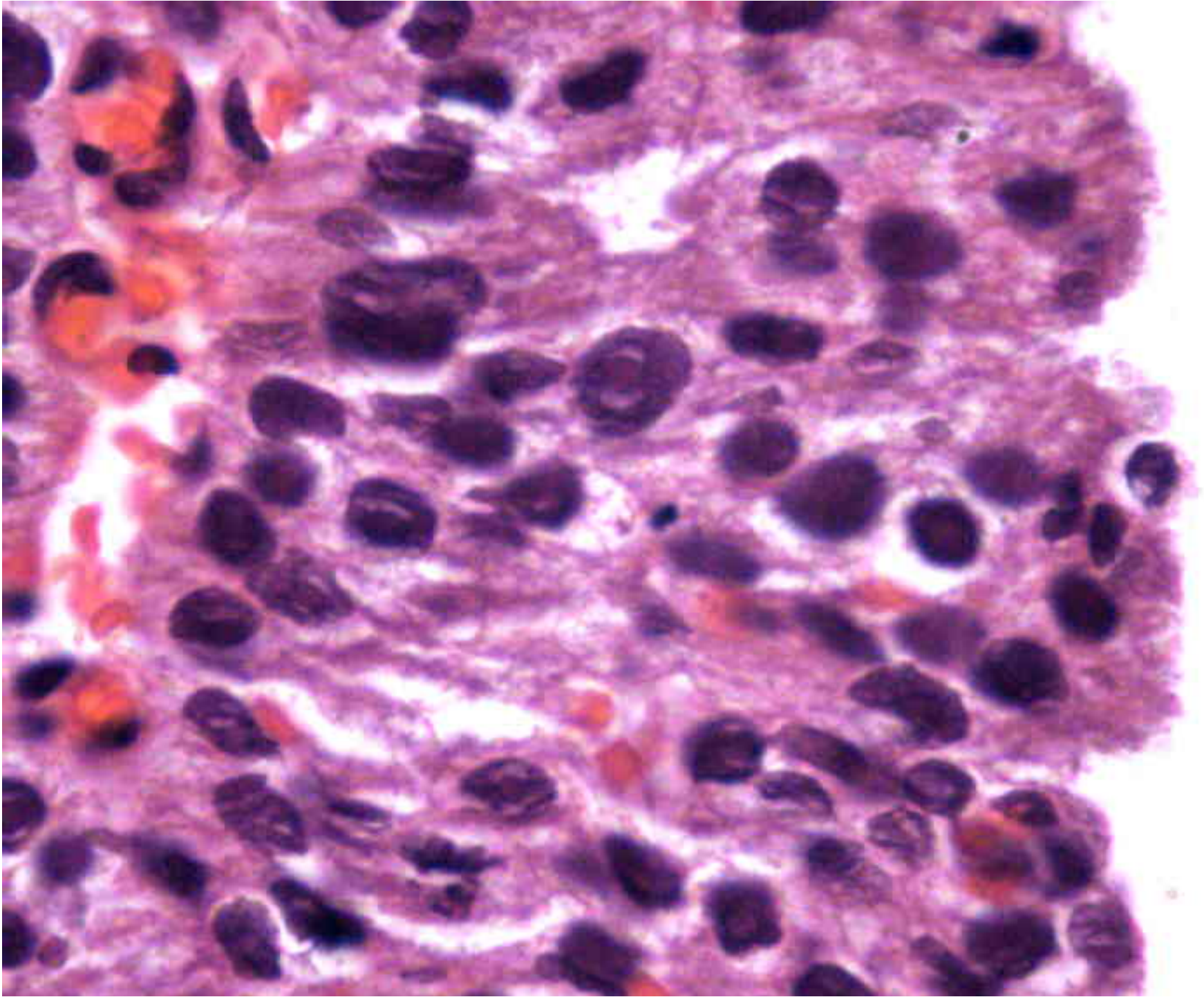




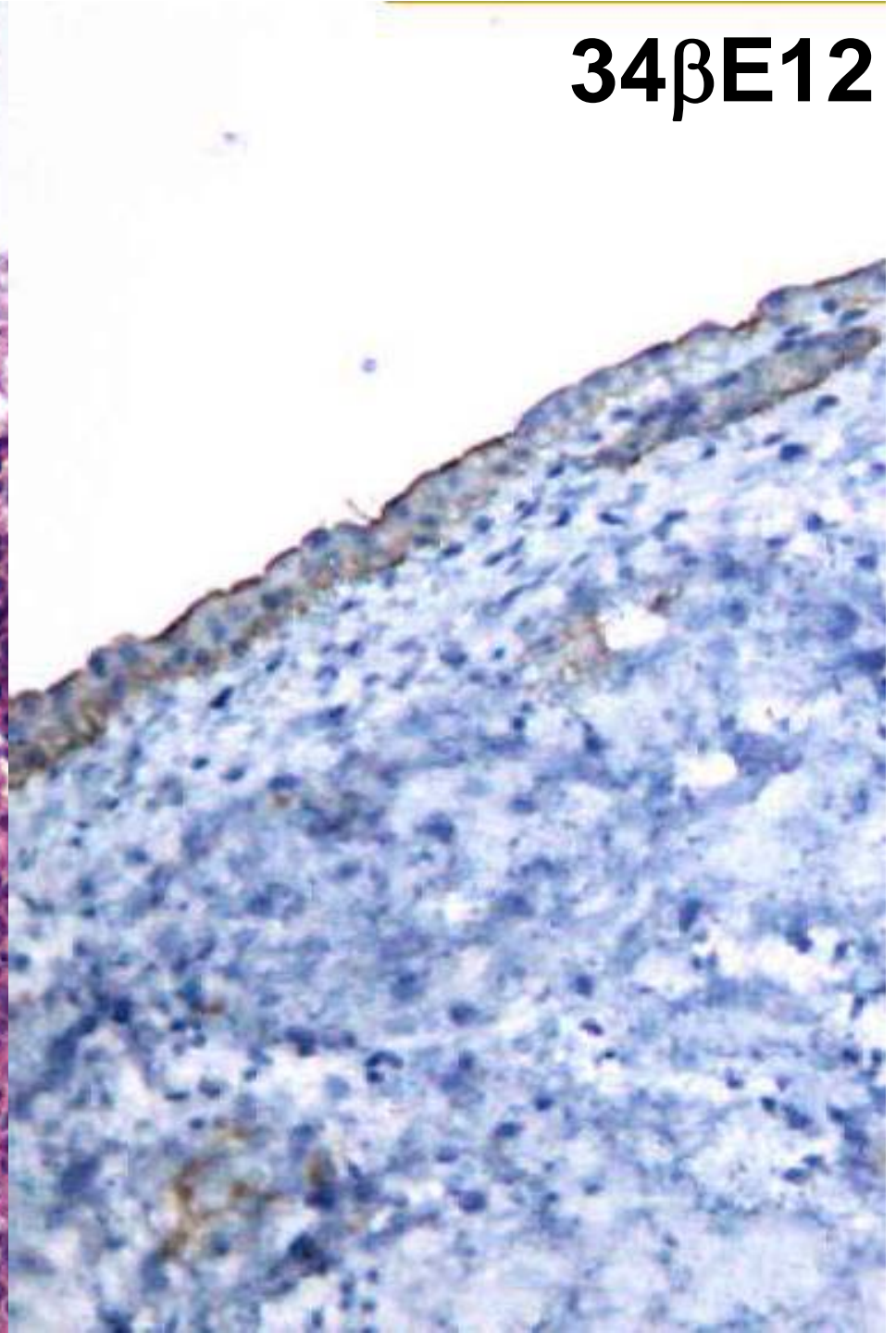
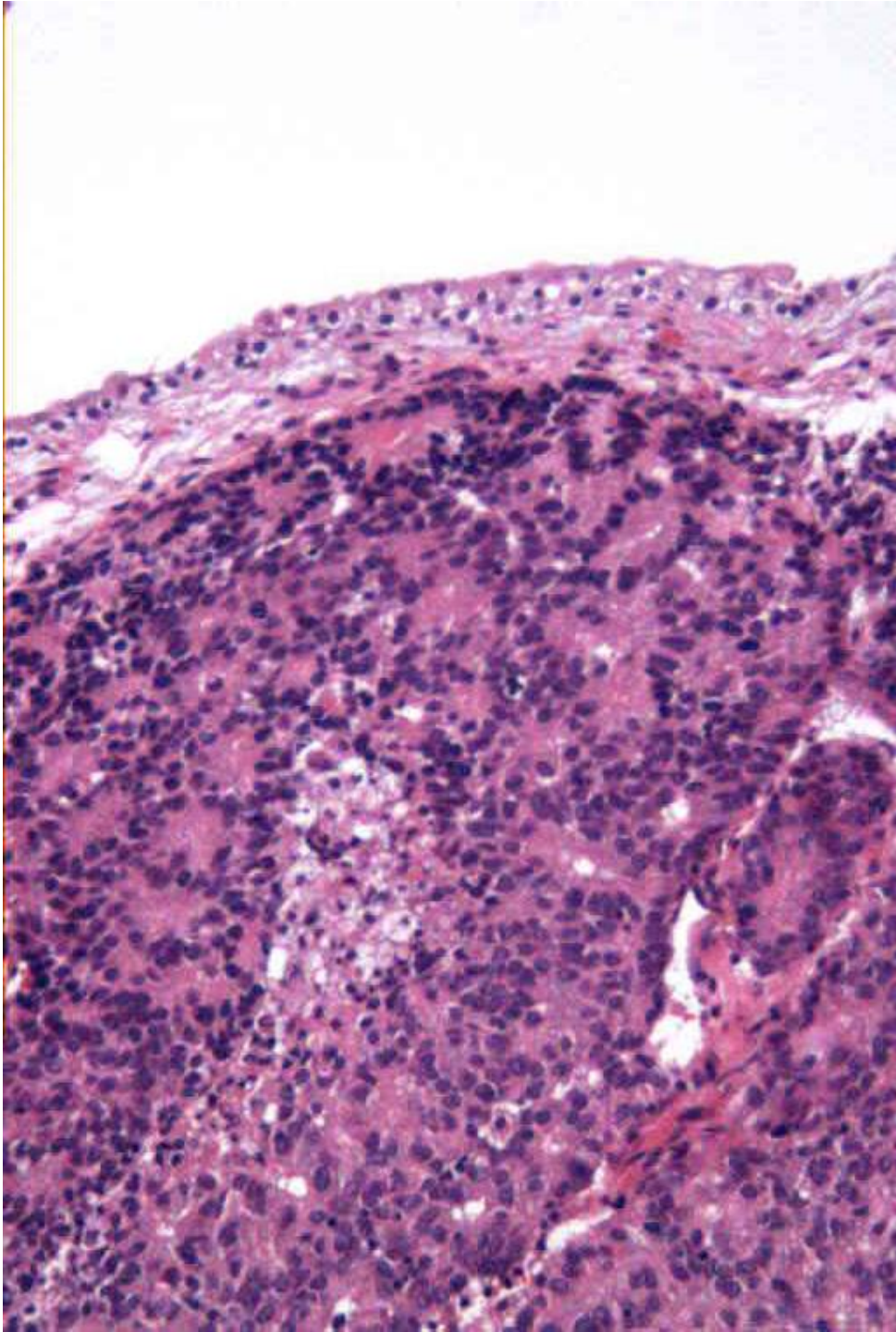


PSA 48 $\mu\text{g/L}$

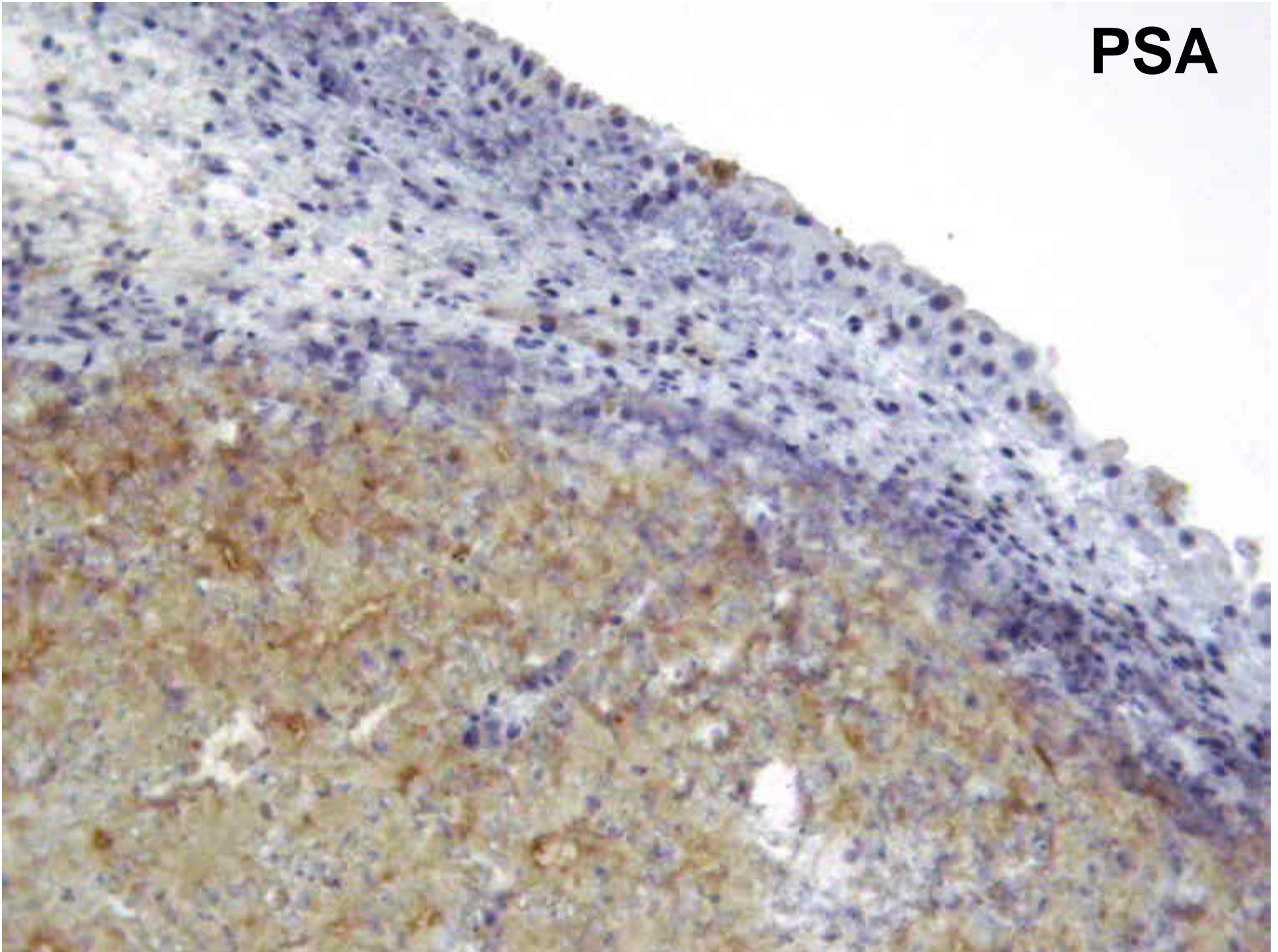




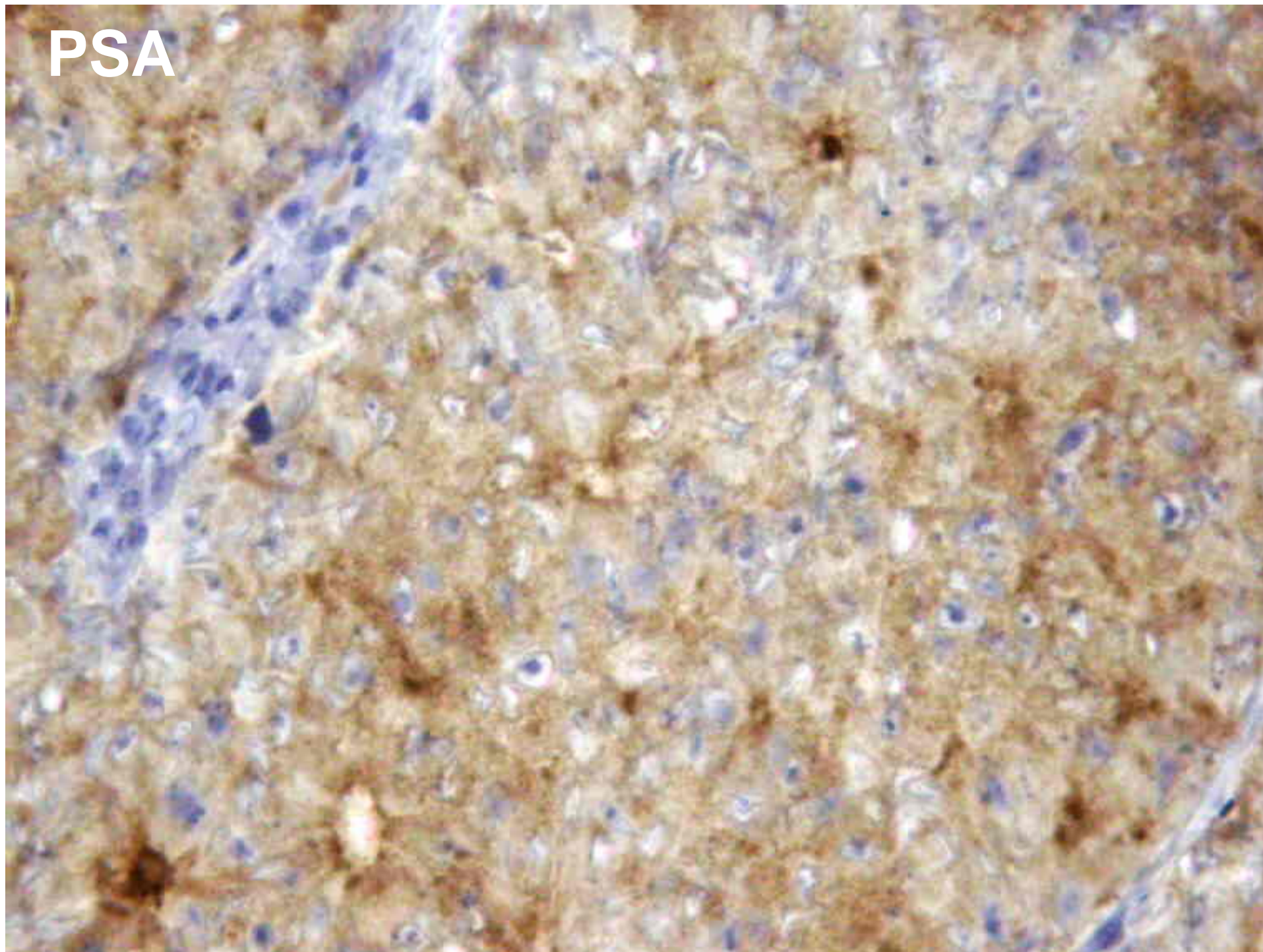
34 β E12

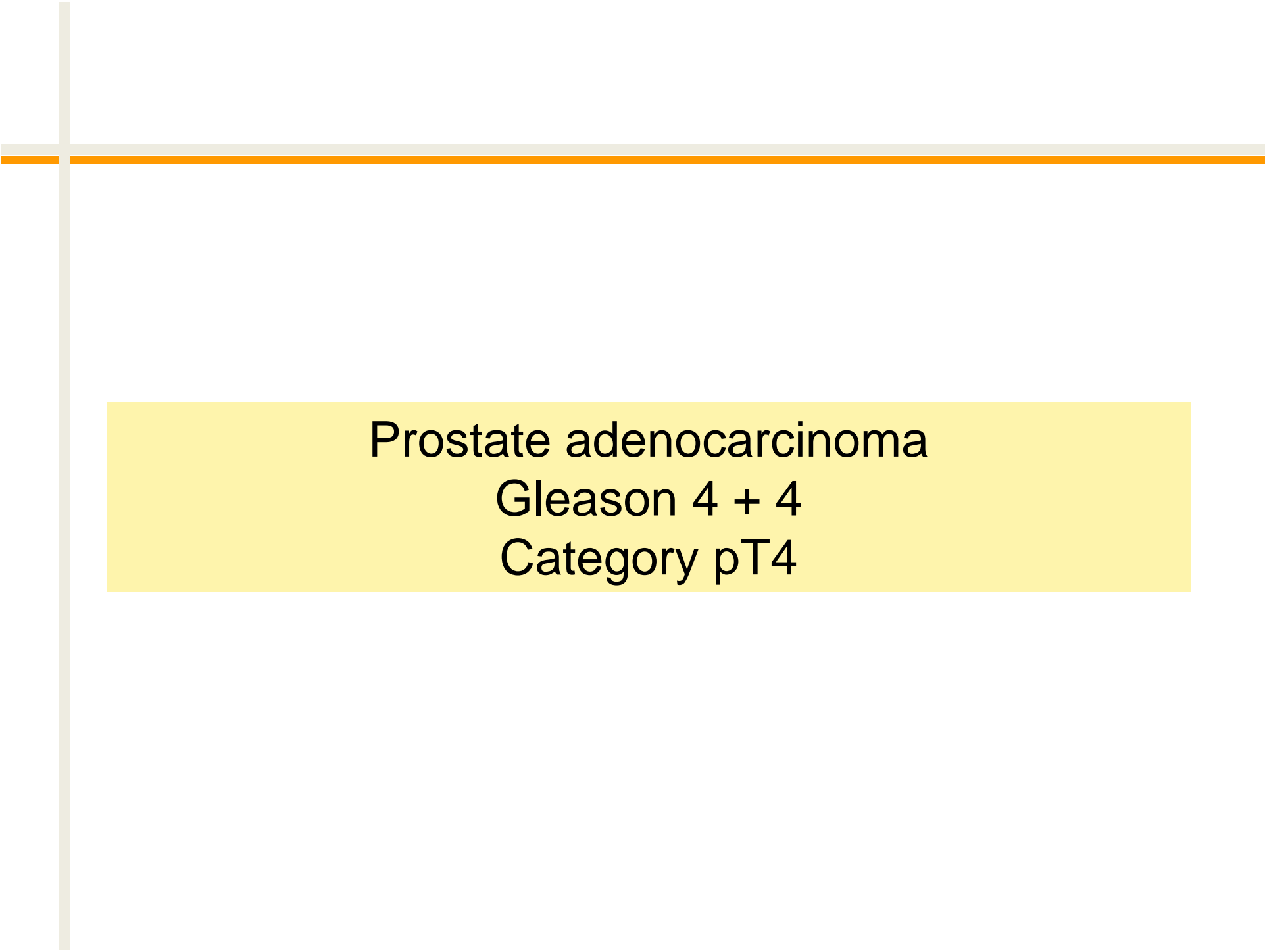


PSA



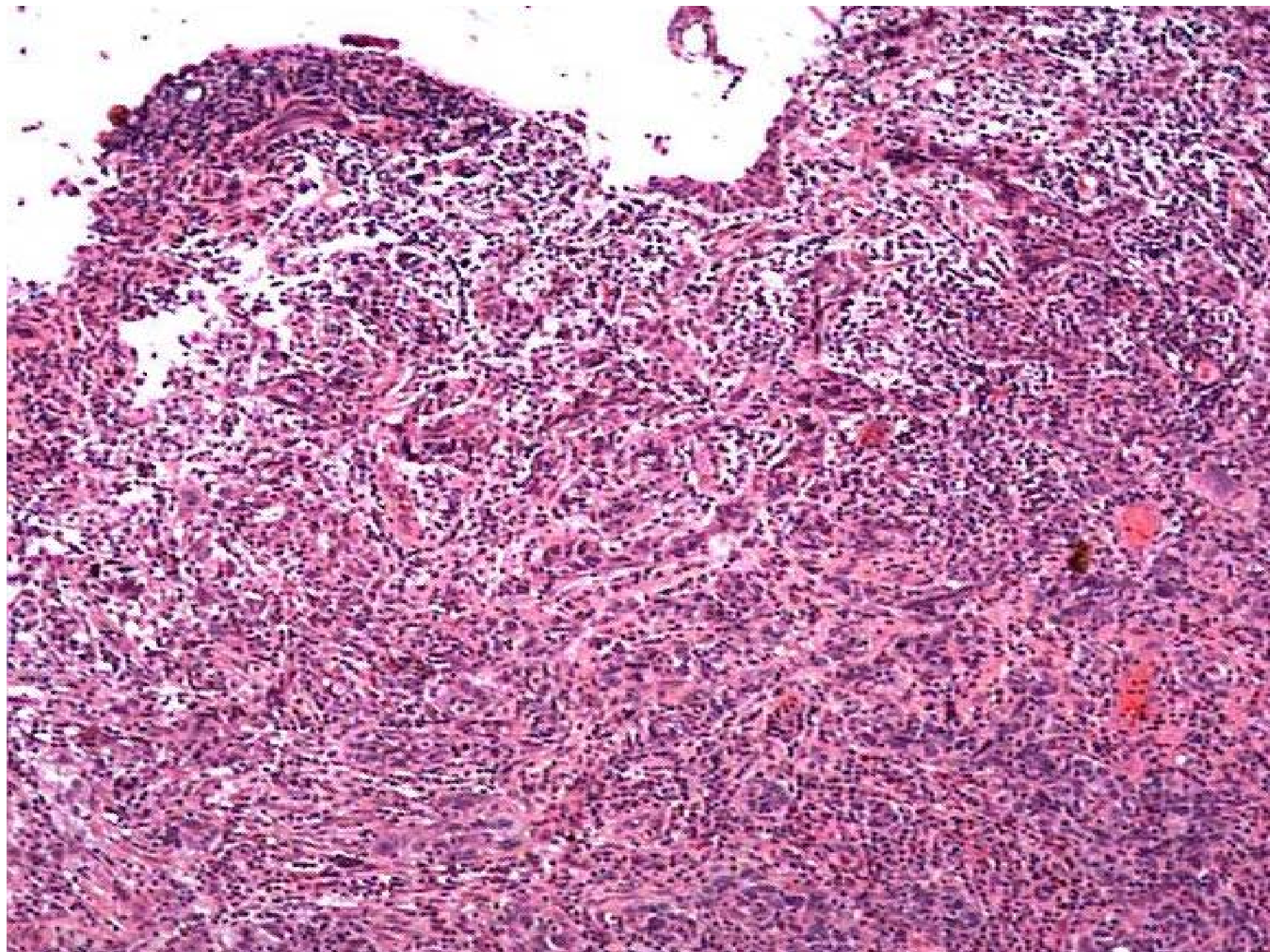
PSA

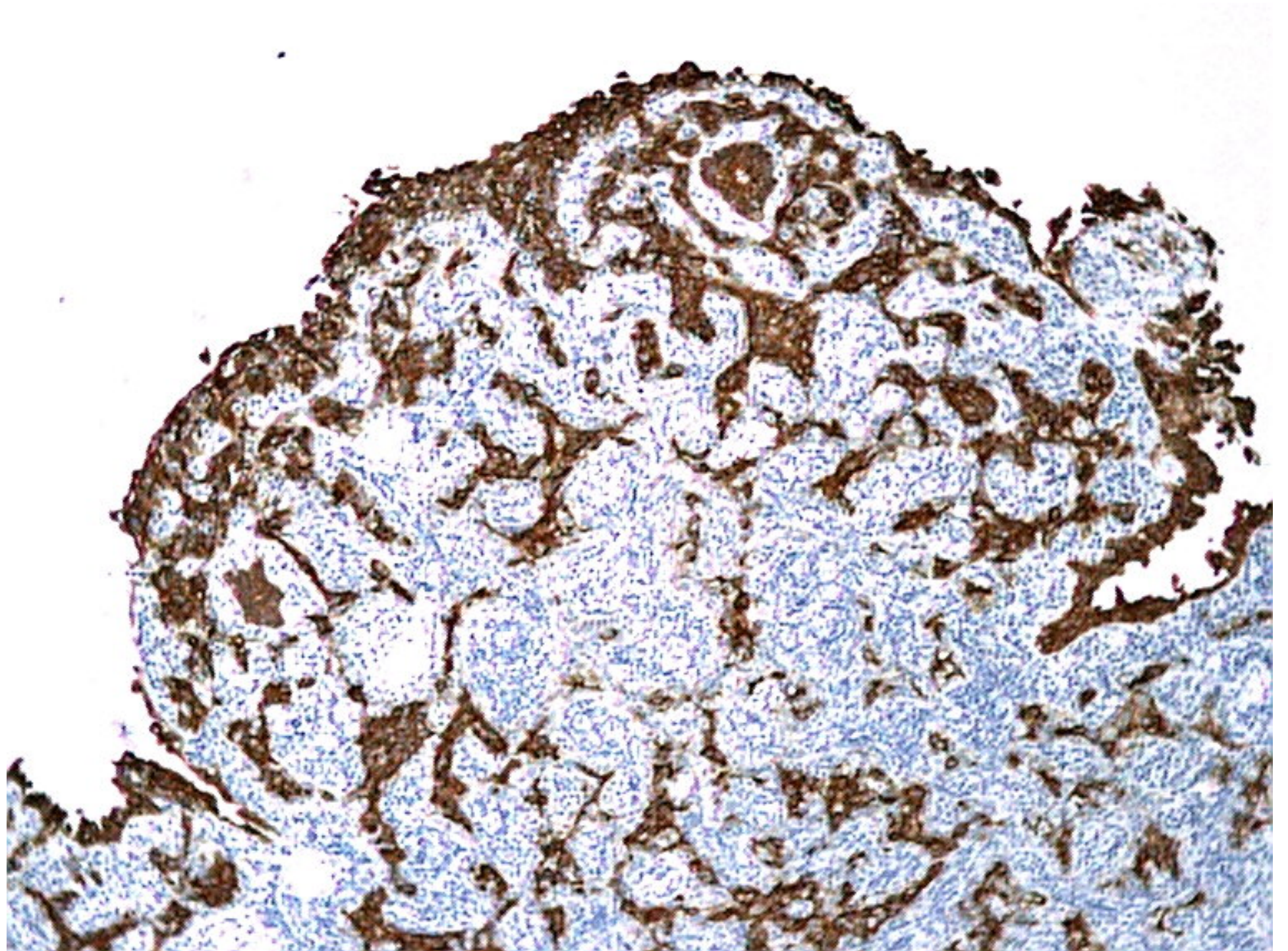




Prostate adenocarcinoma
Gleason 4 + 4
Category pT4

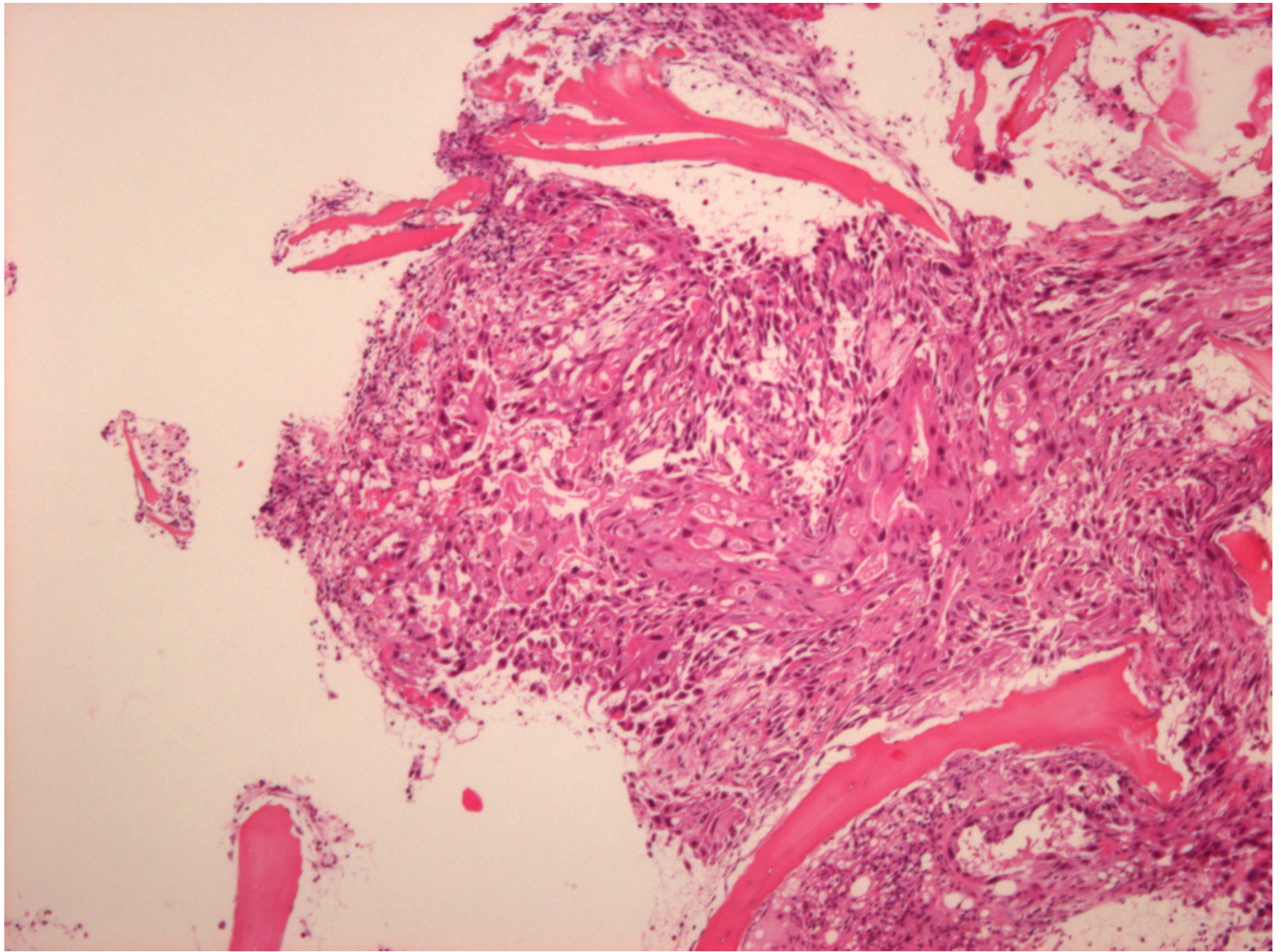
diagnostic

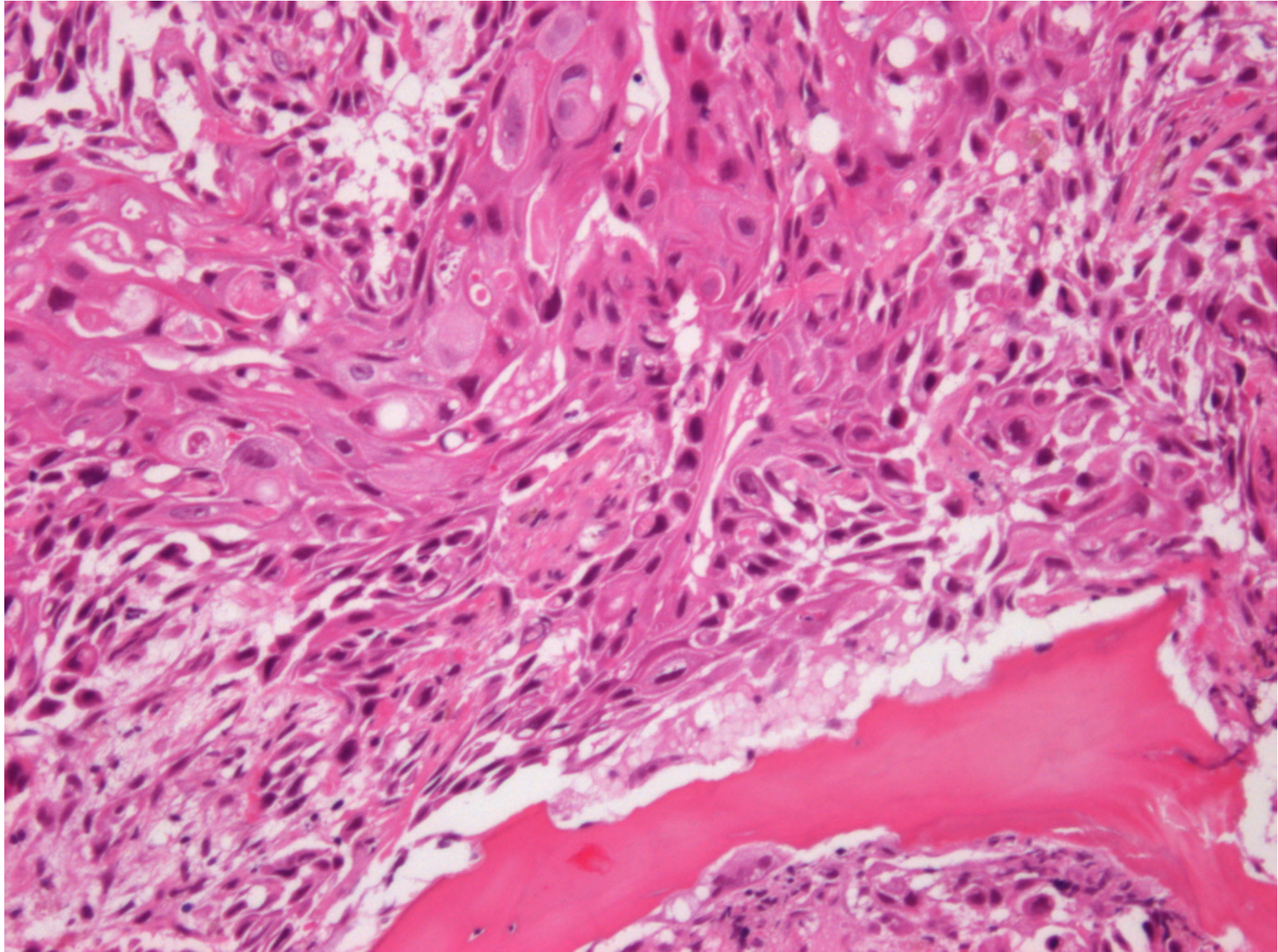


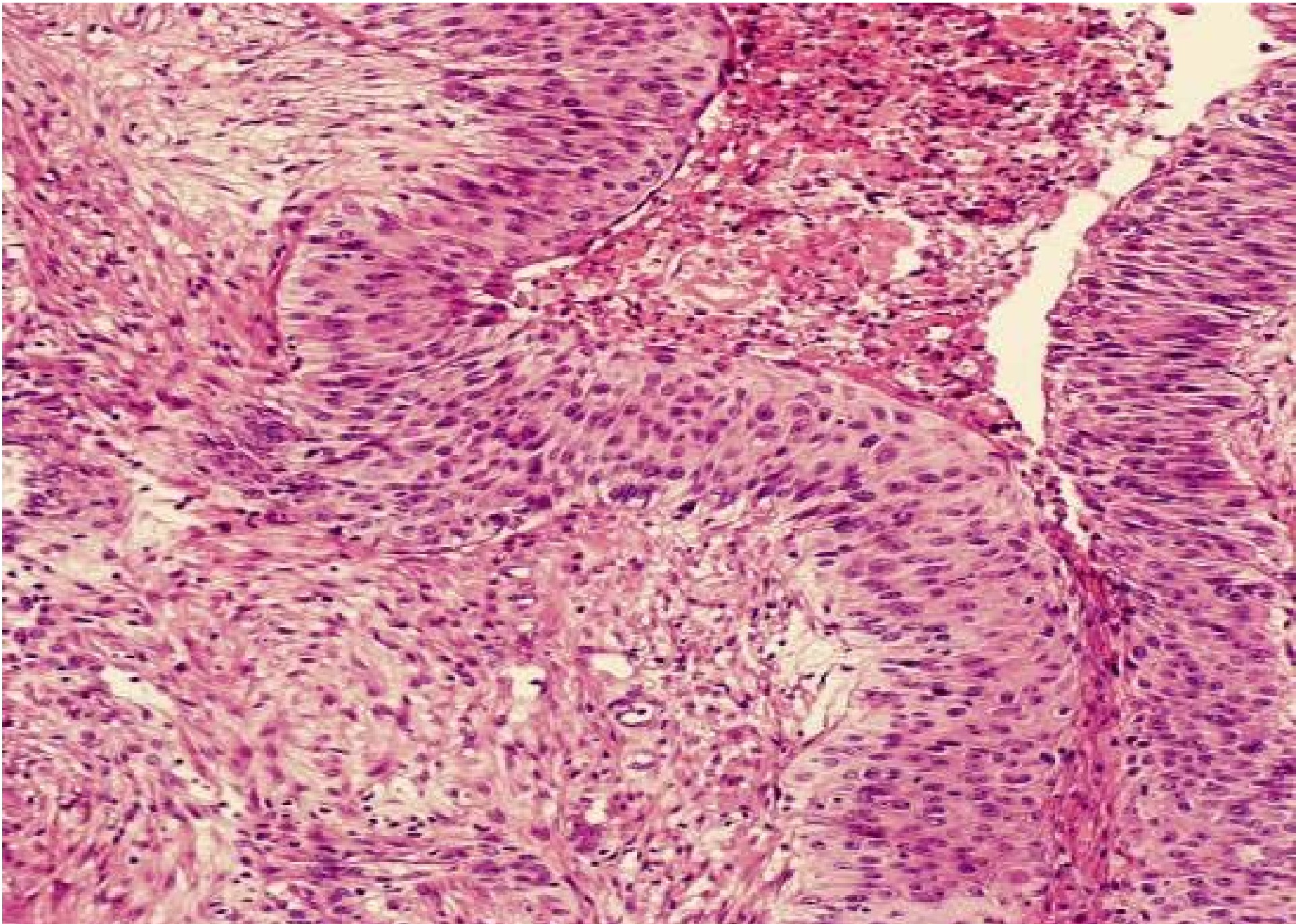


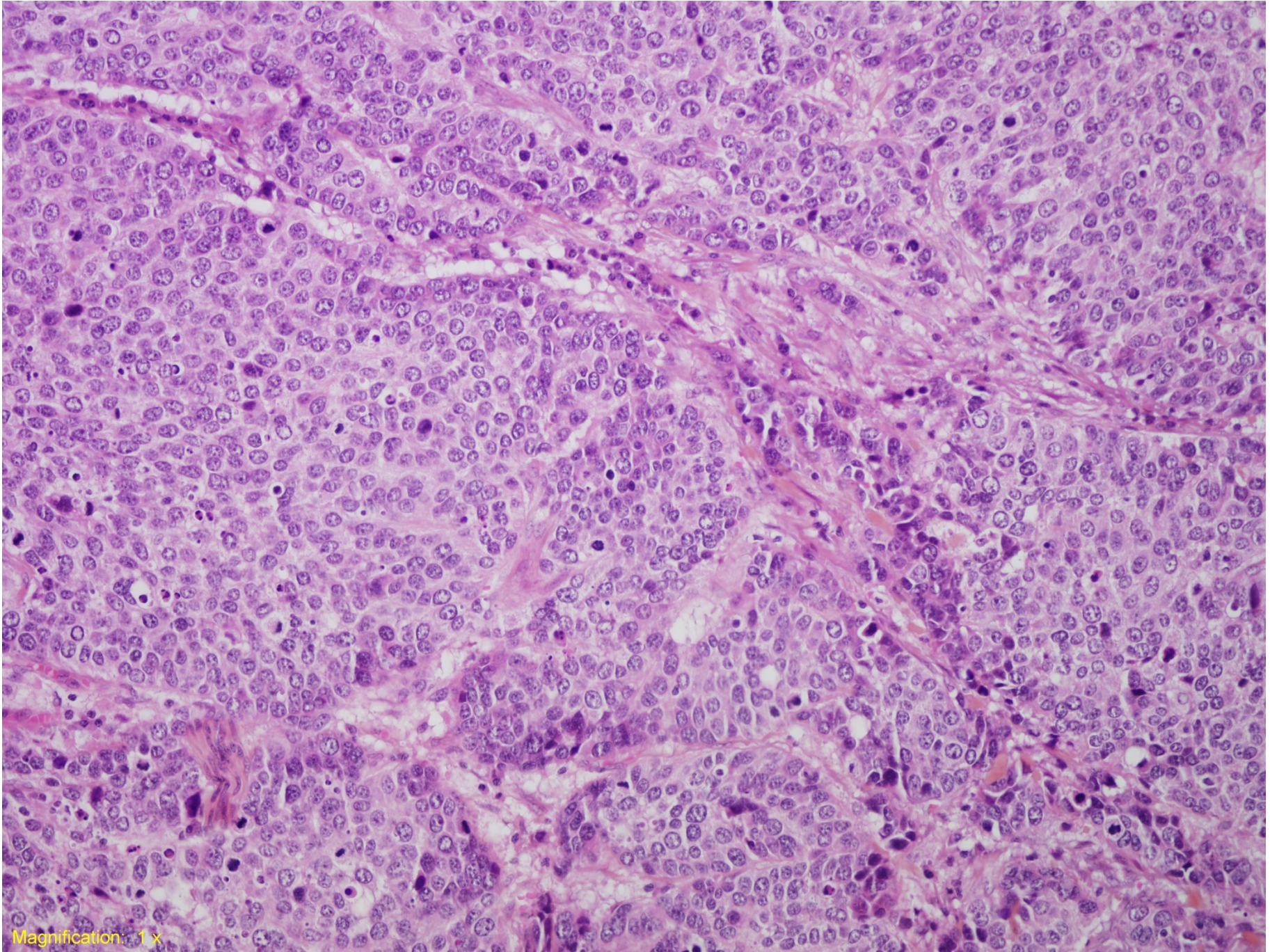
Interest of immunohistochemistry

- When there is a huge inflammatory infiltrate to unmask invasive carcinoma

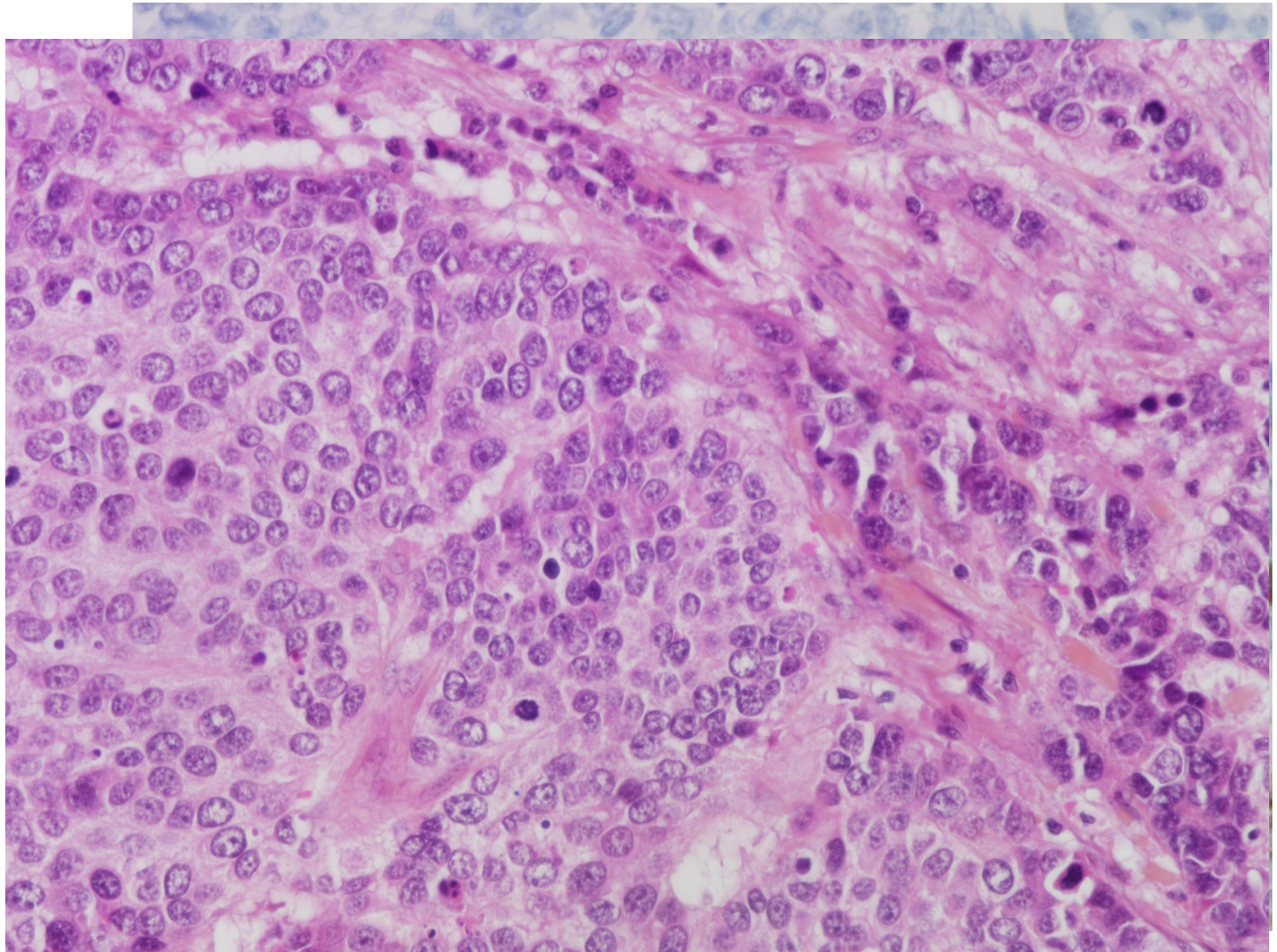


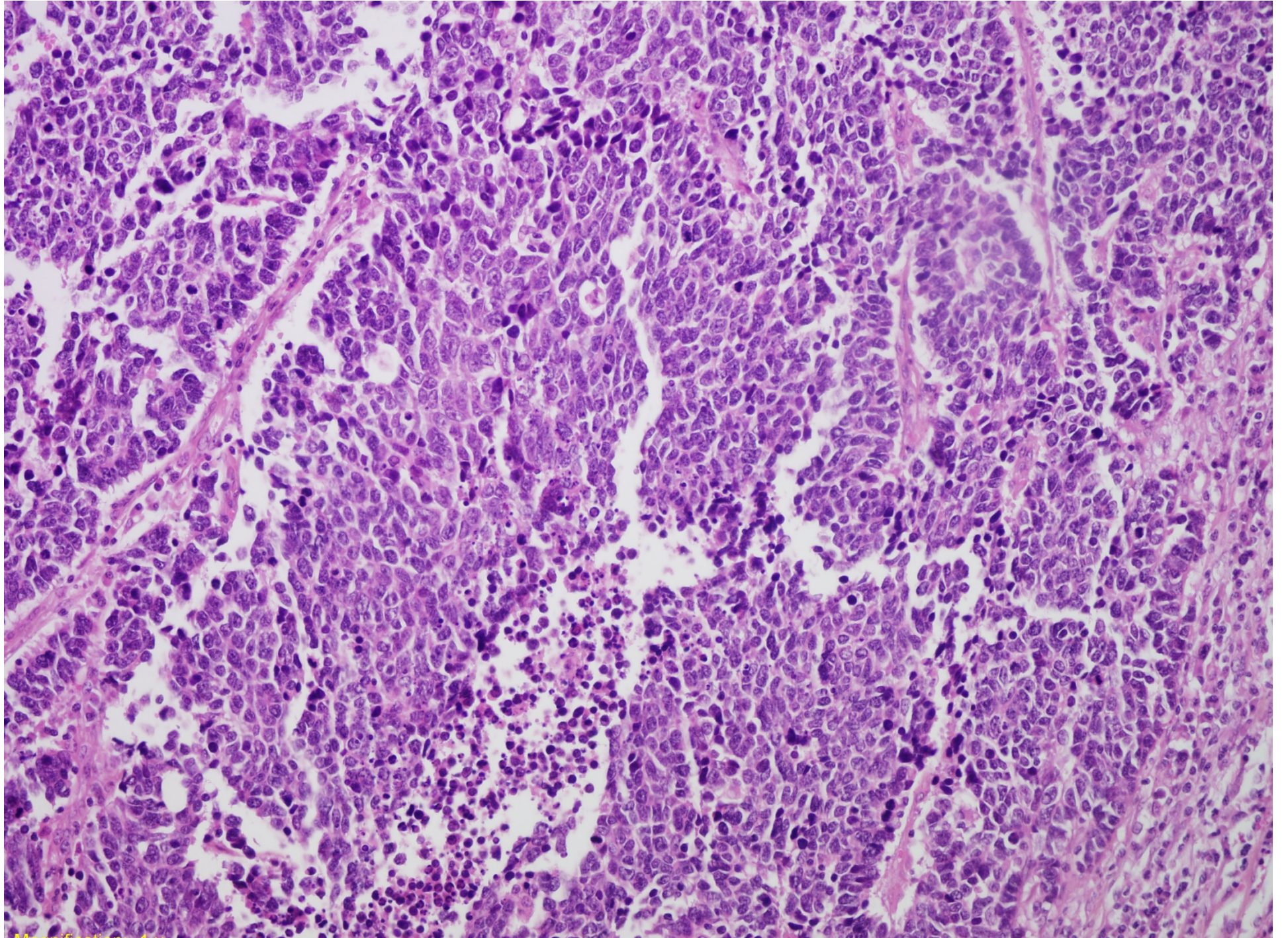


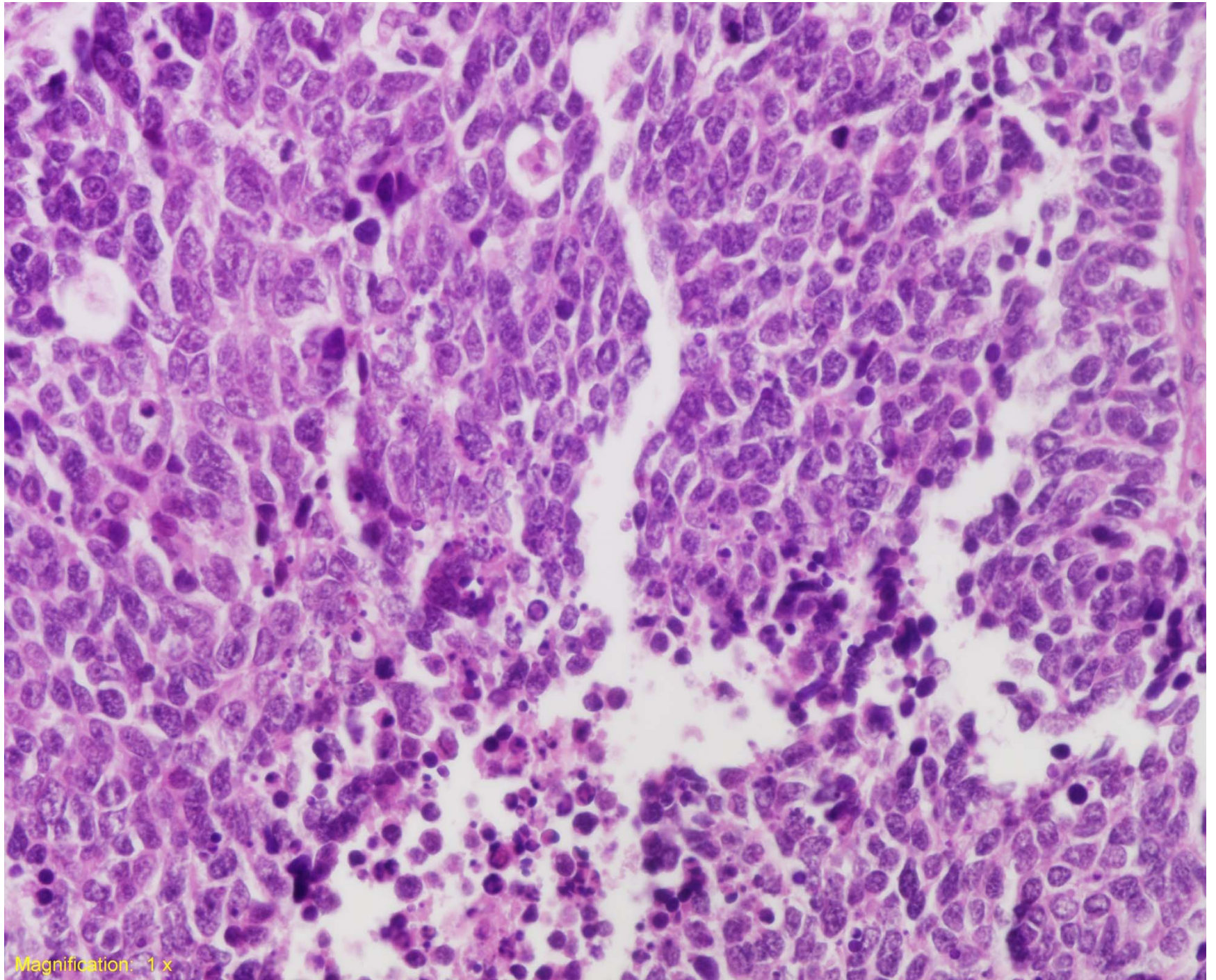




Magnification: 1 x

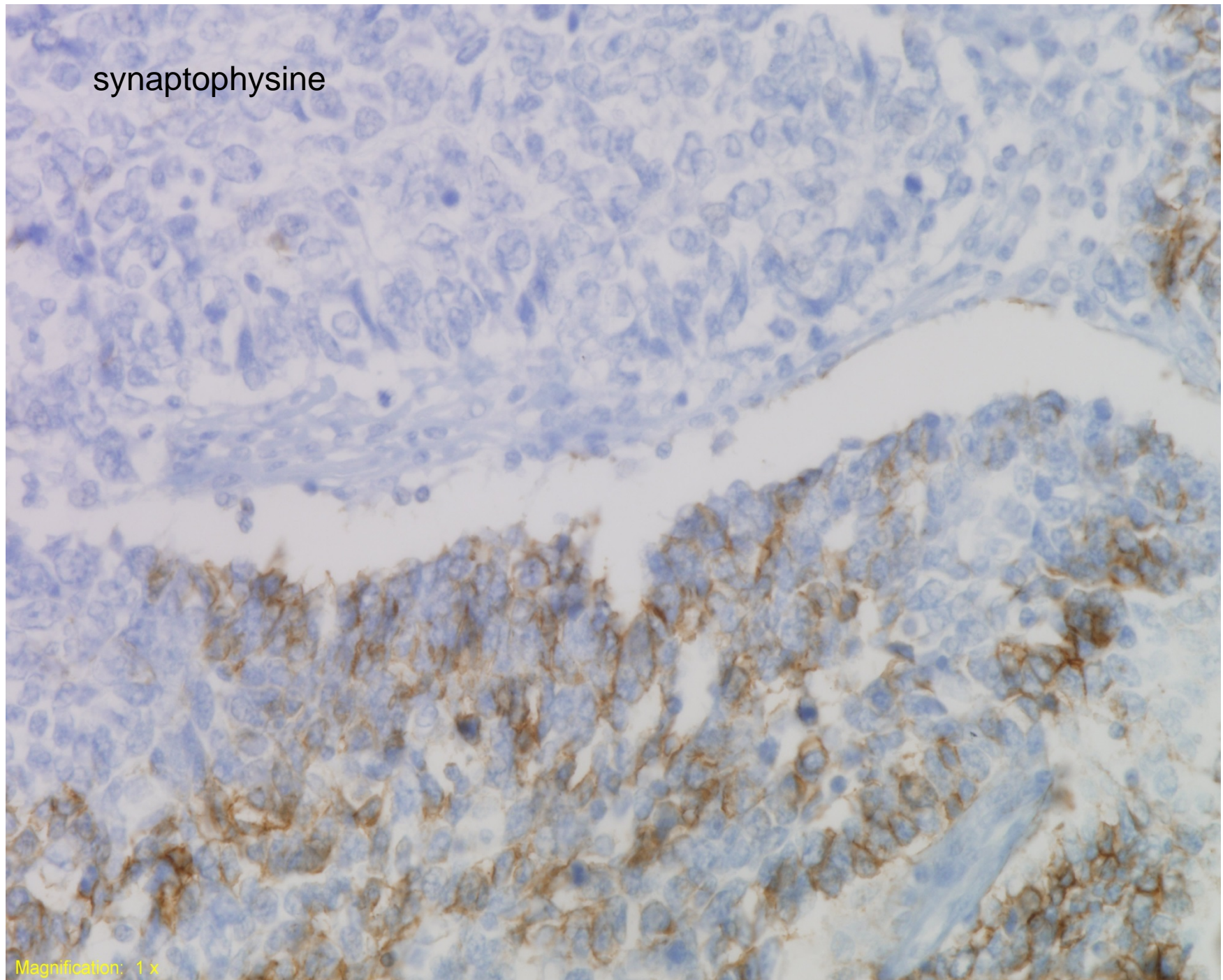






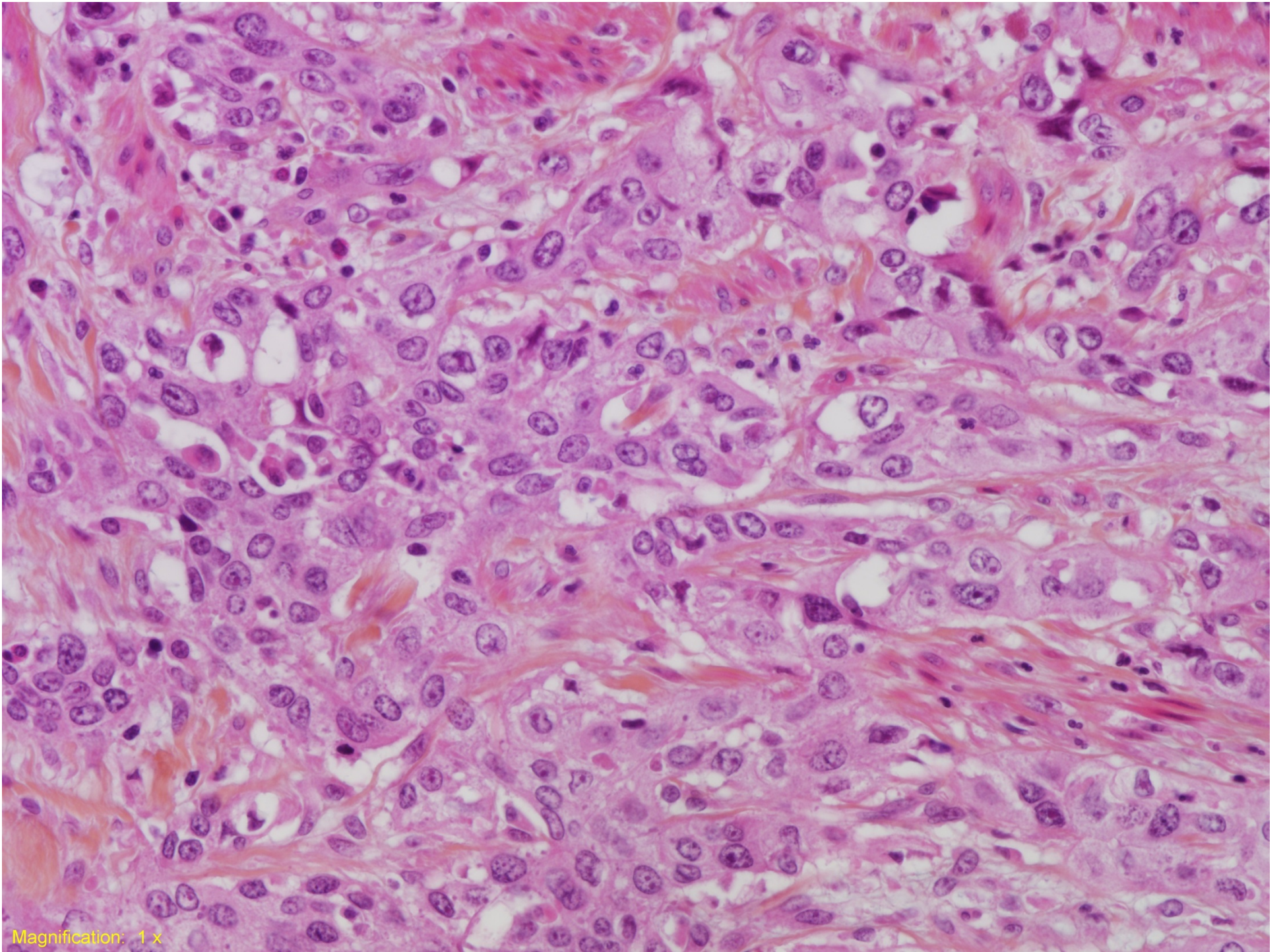
Magnification: 1 x

synaptophysine

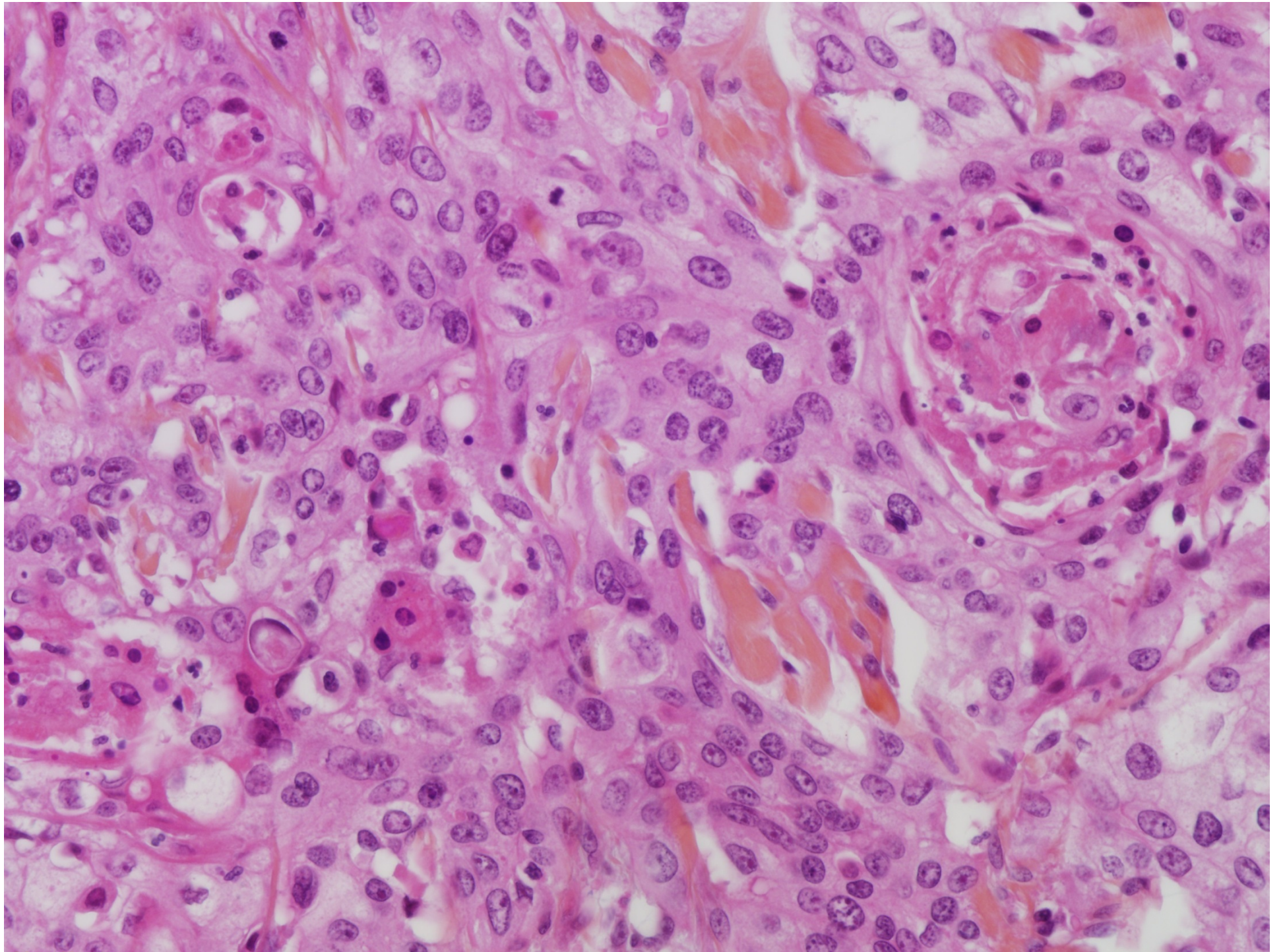


Magnification: 1 x

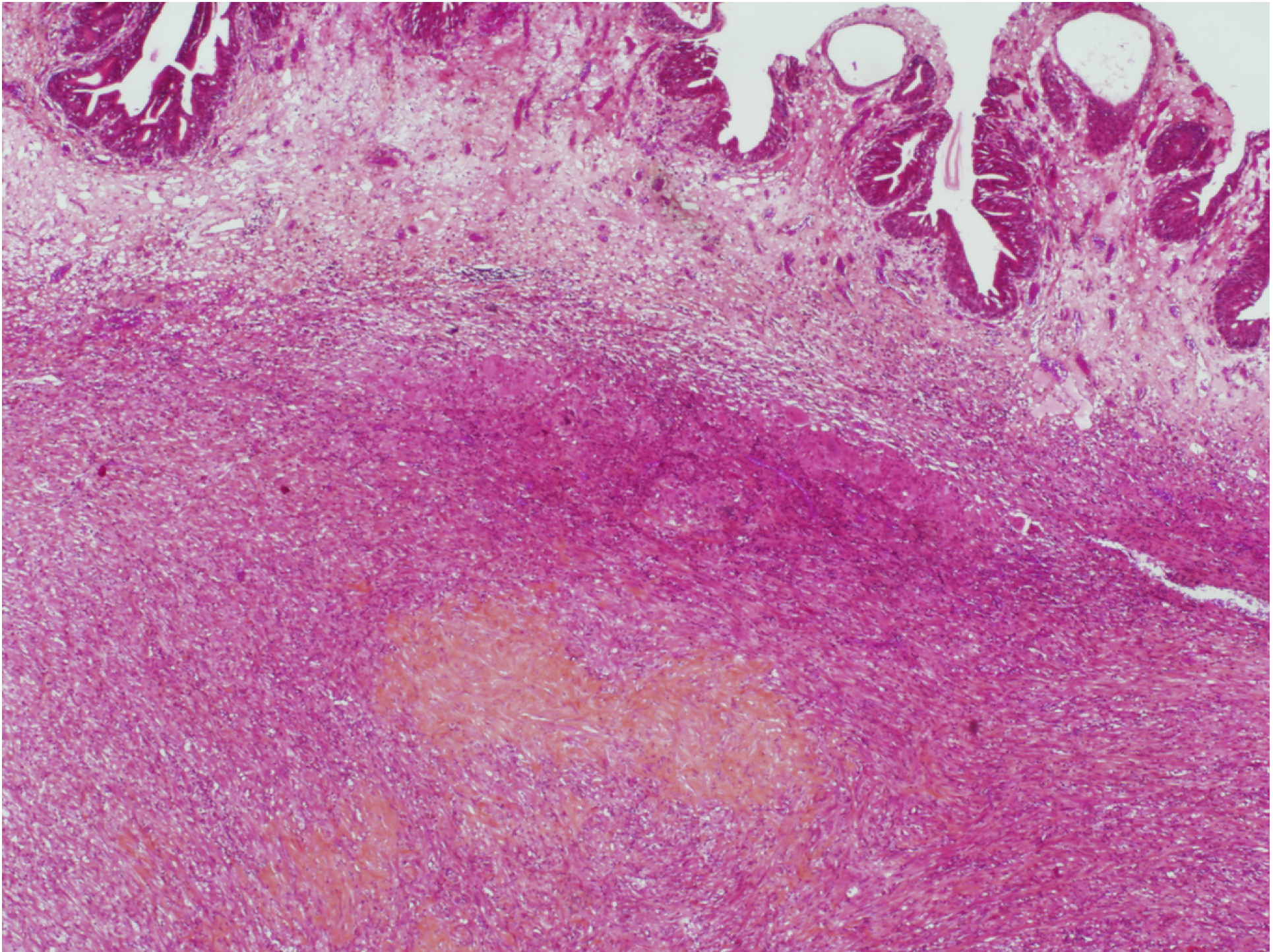
Neuroendocrine carcinoma poorly differentiated
associated with urothelial carcinoma

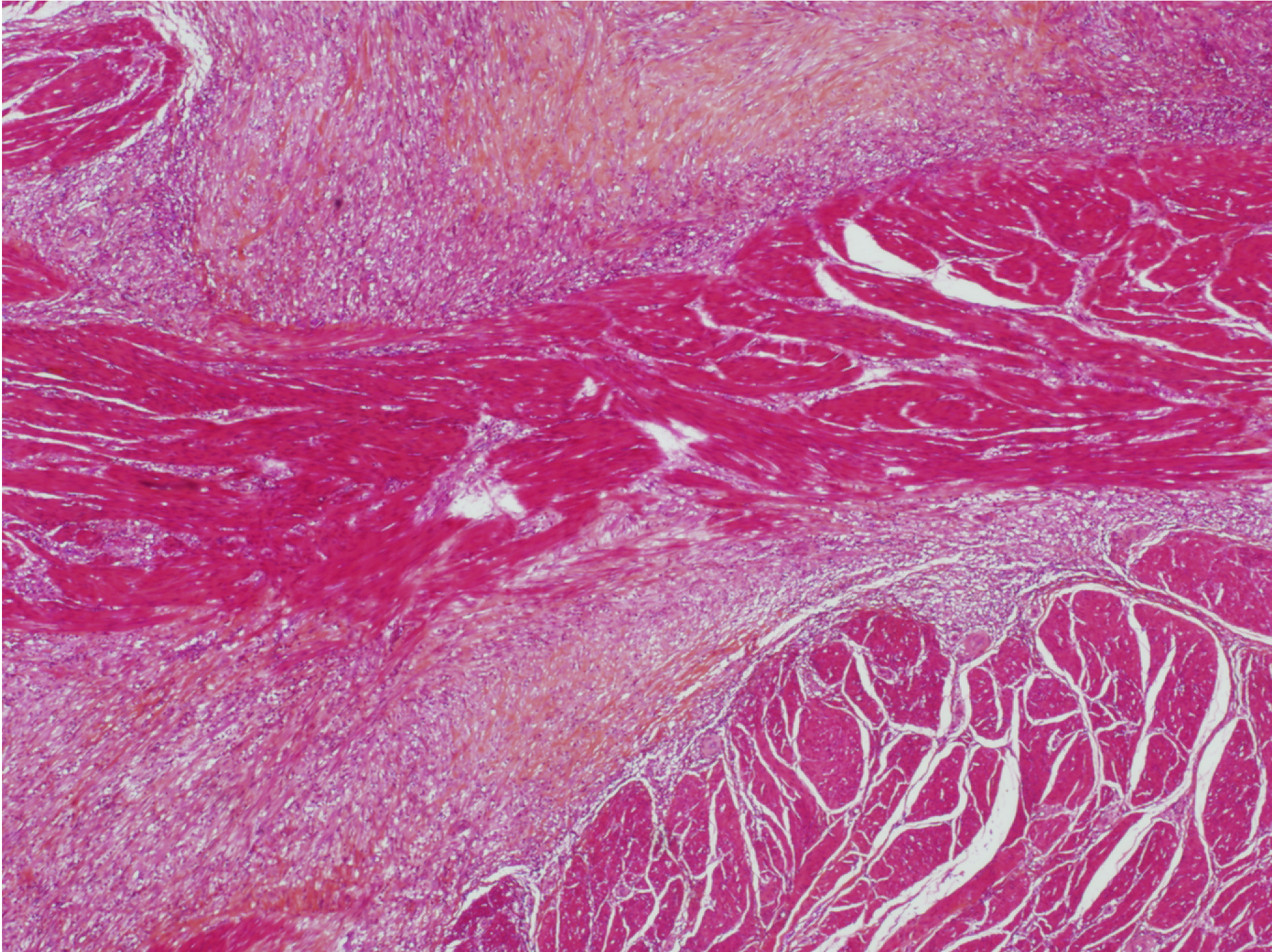


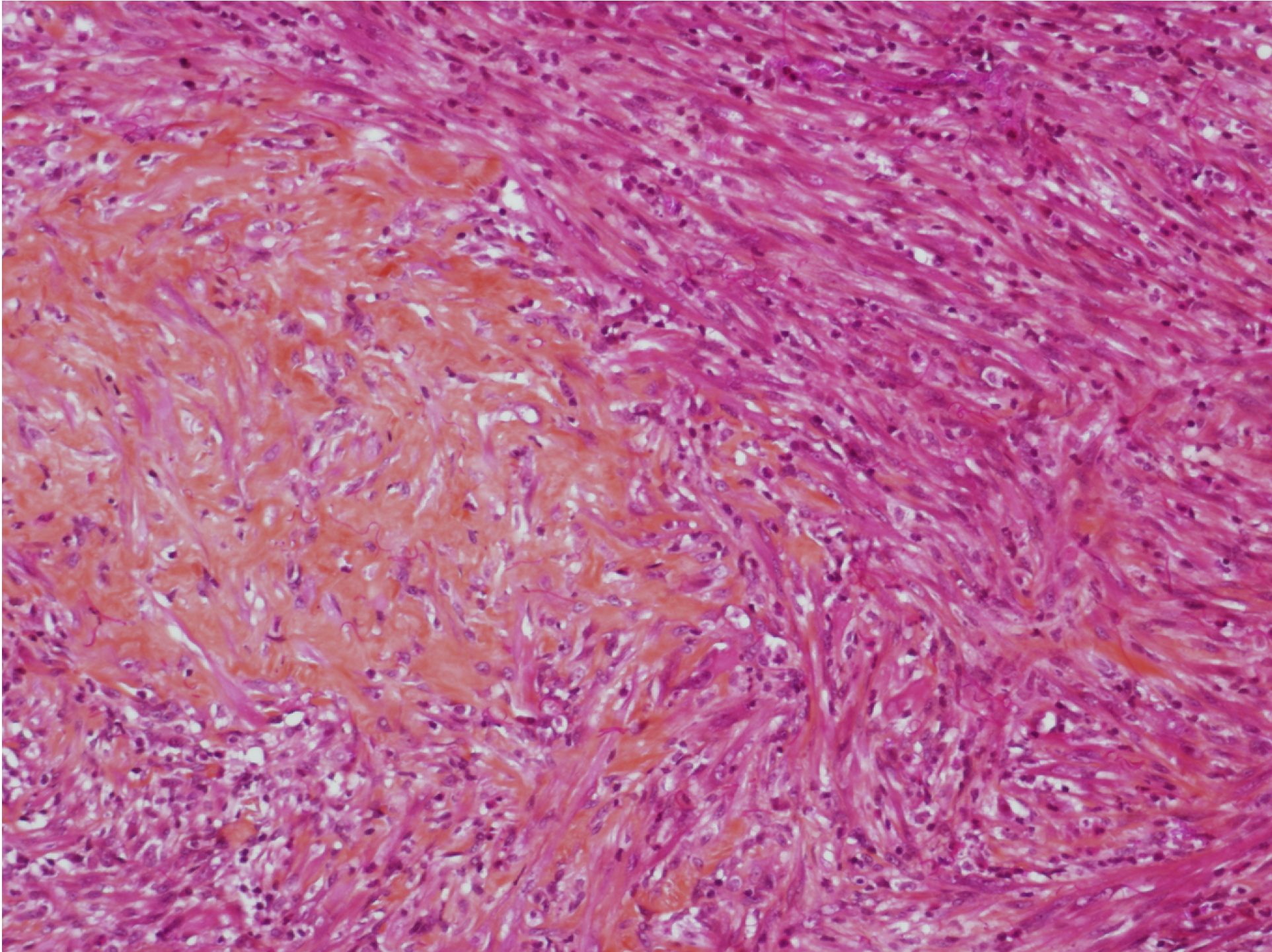
Magnification: 1 x

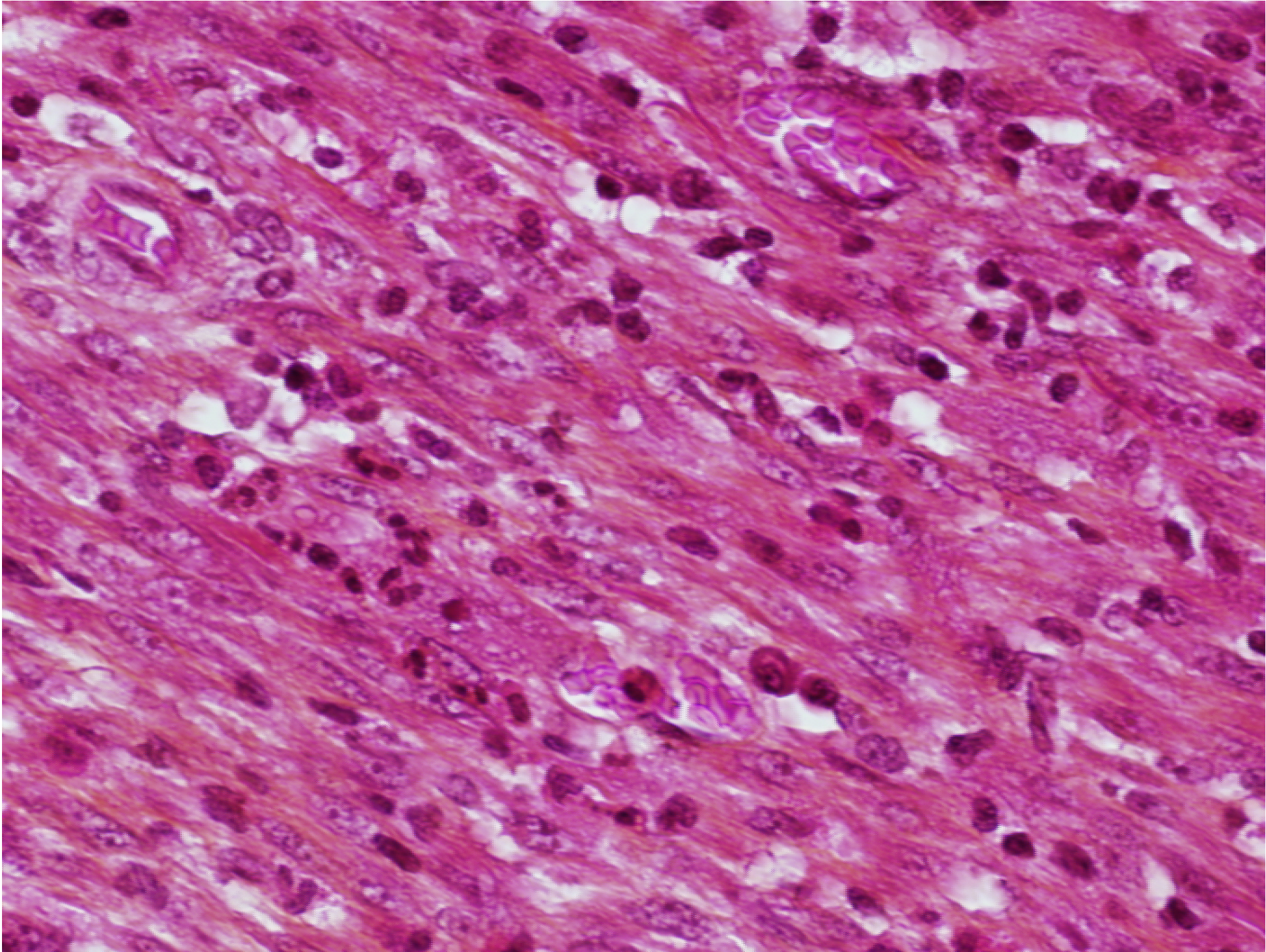


Urothelial carcinoma with squamous differentiation

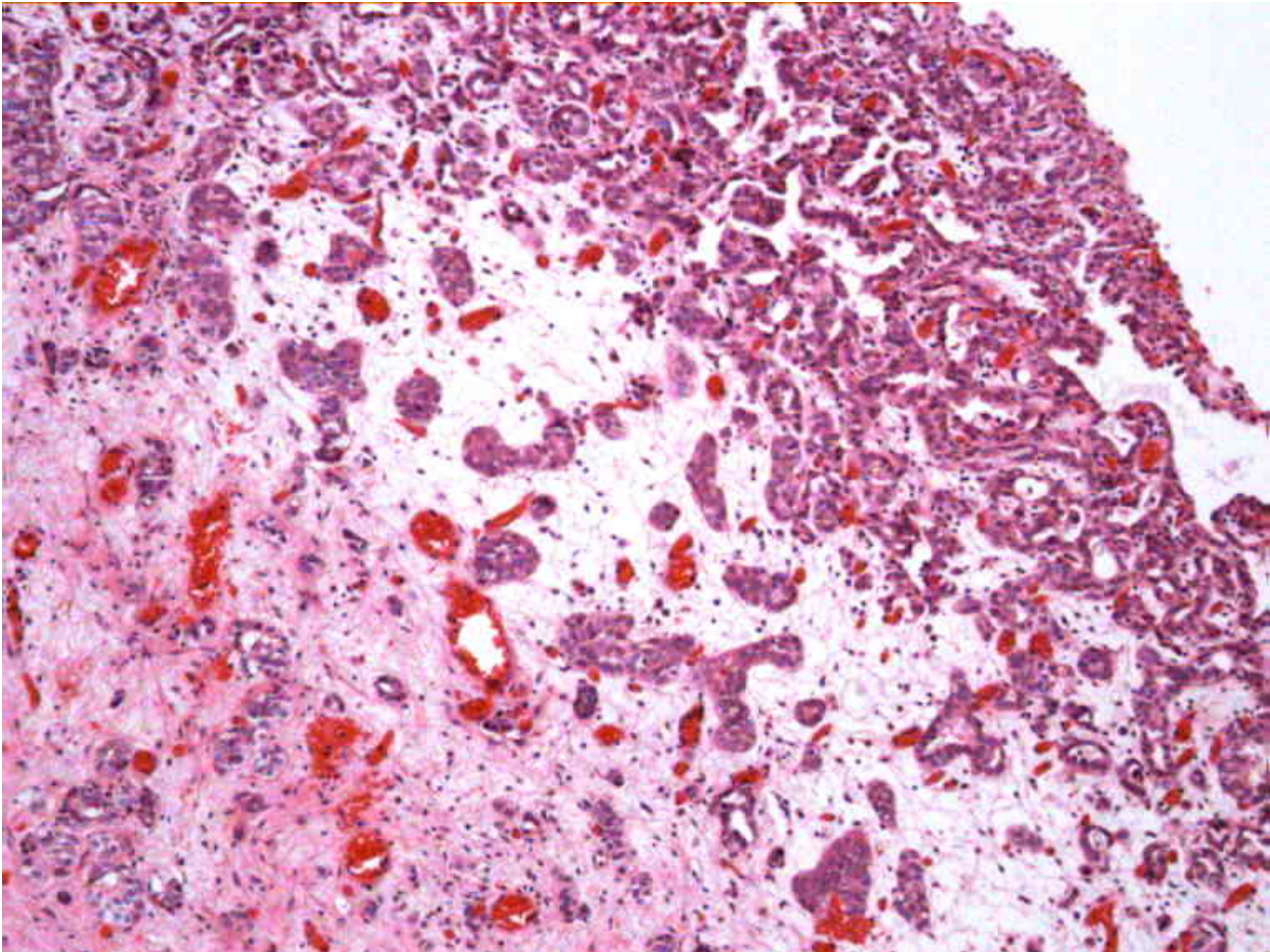


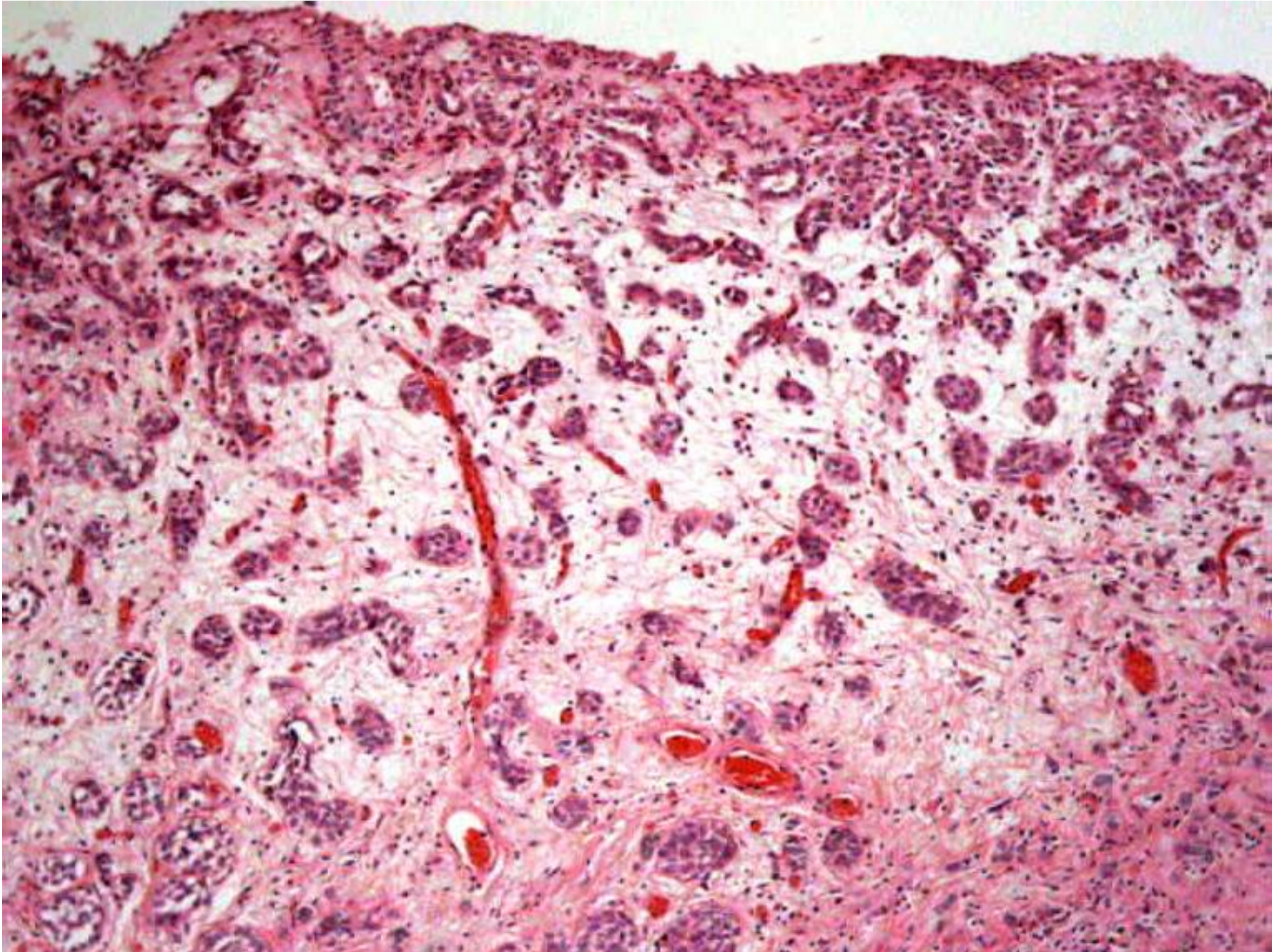


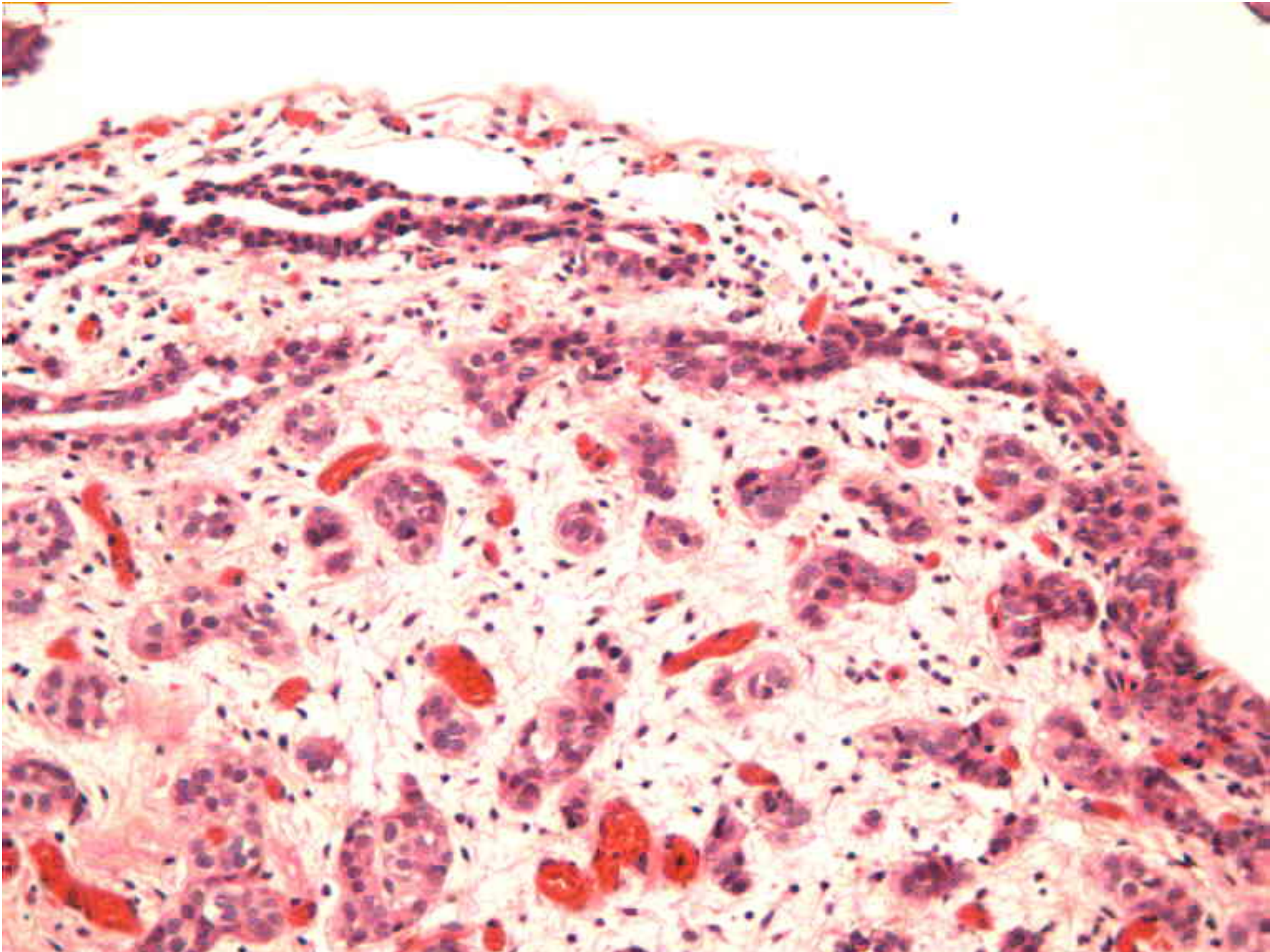


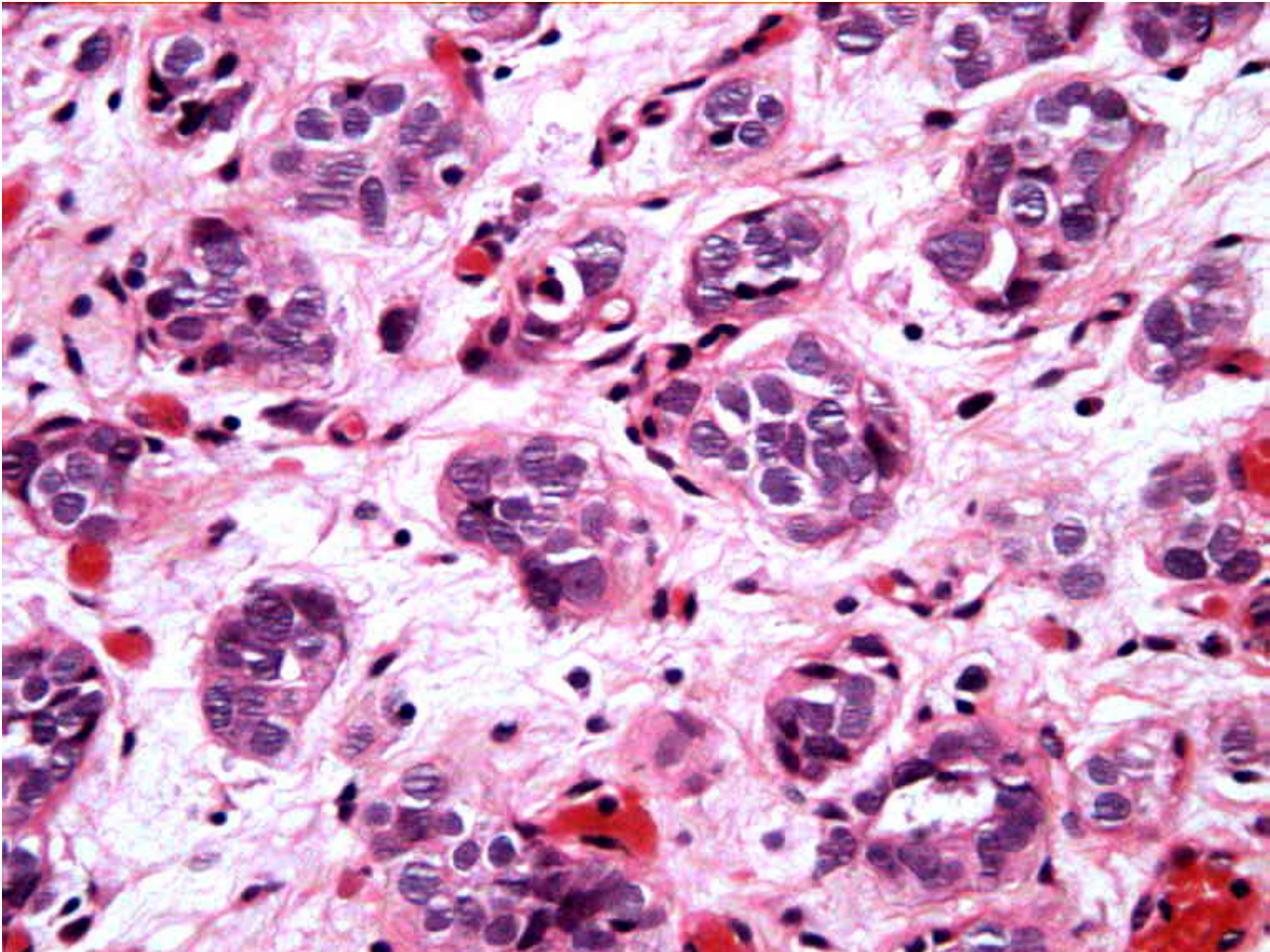


Myofibroblastic proliferation

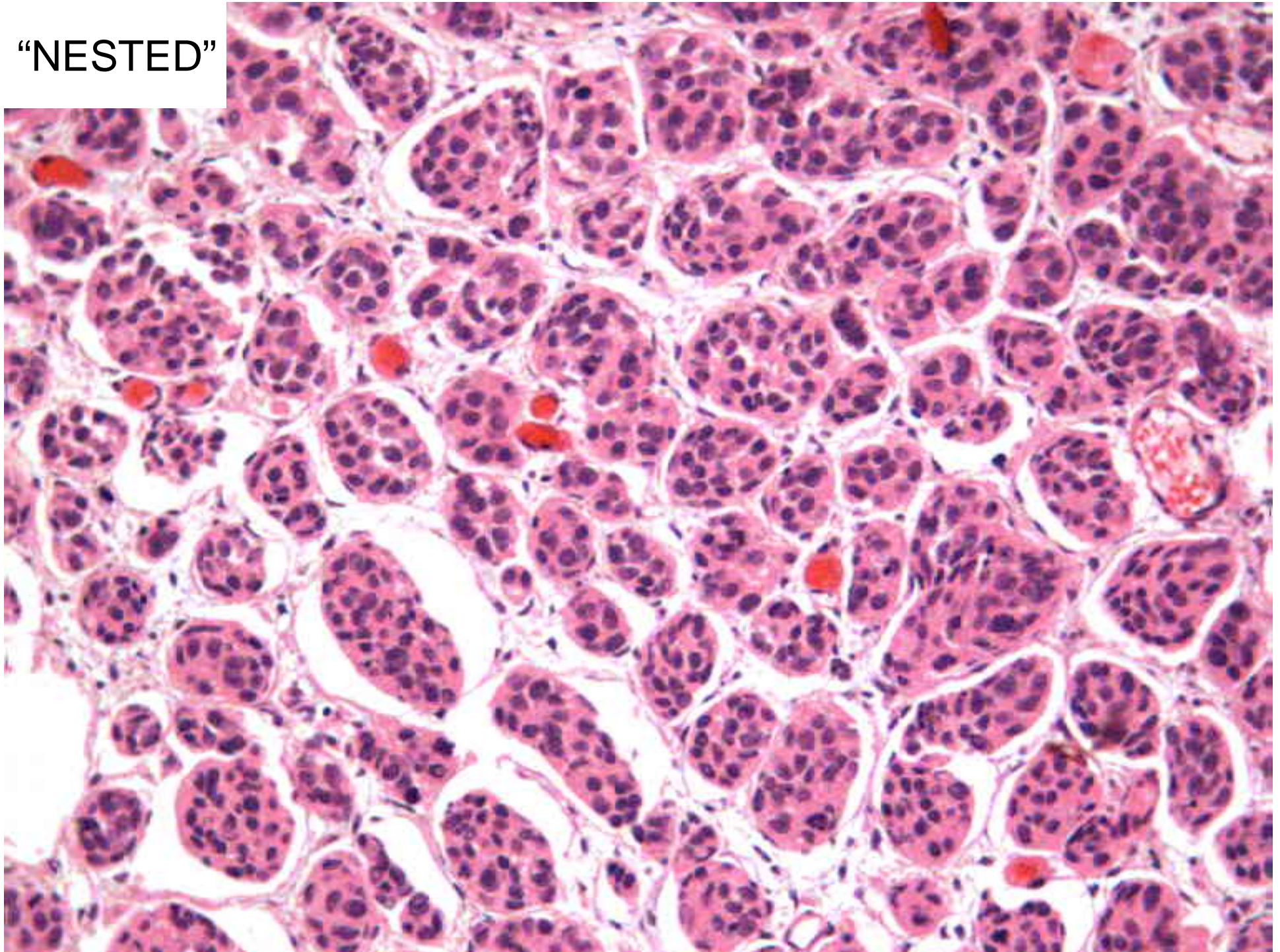




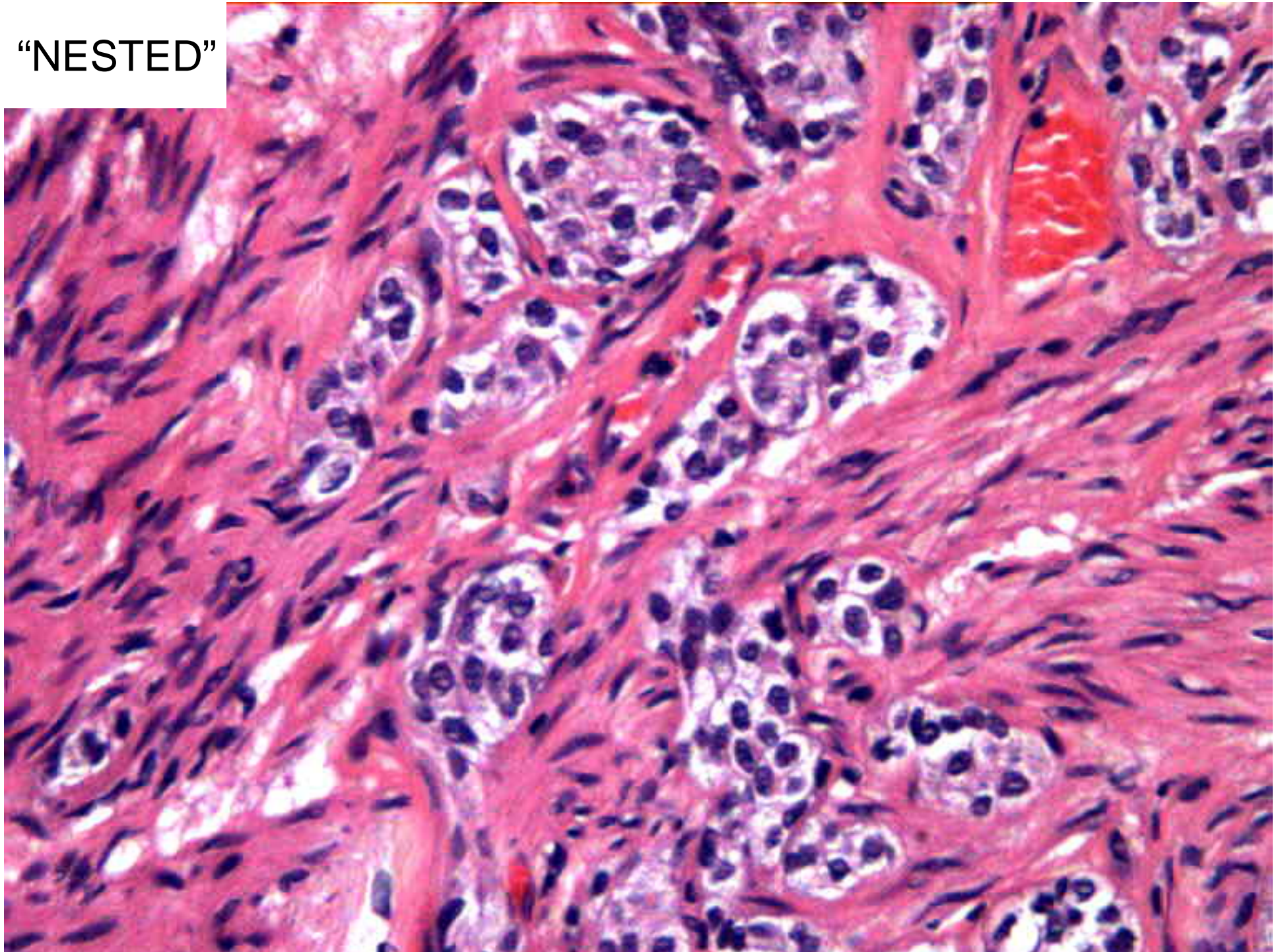




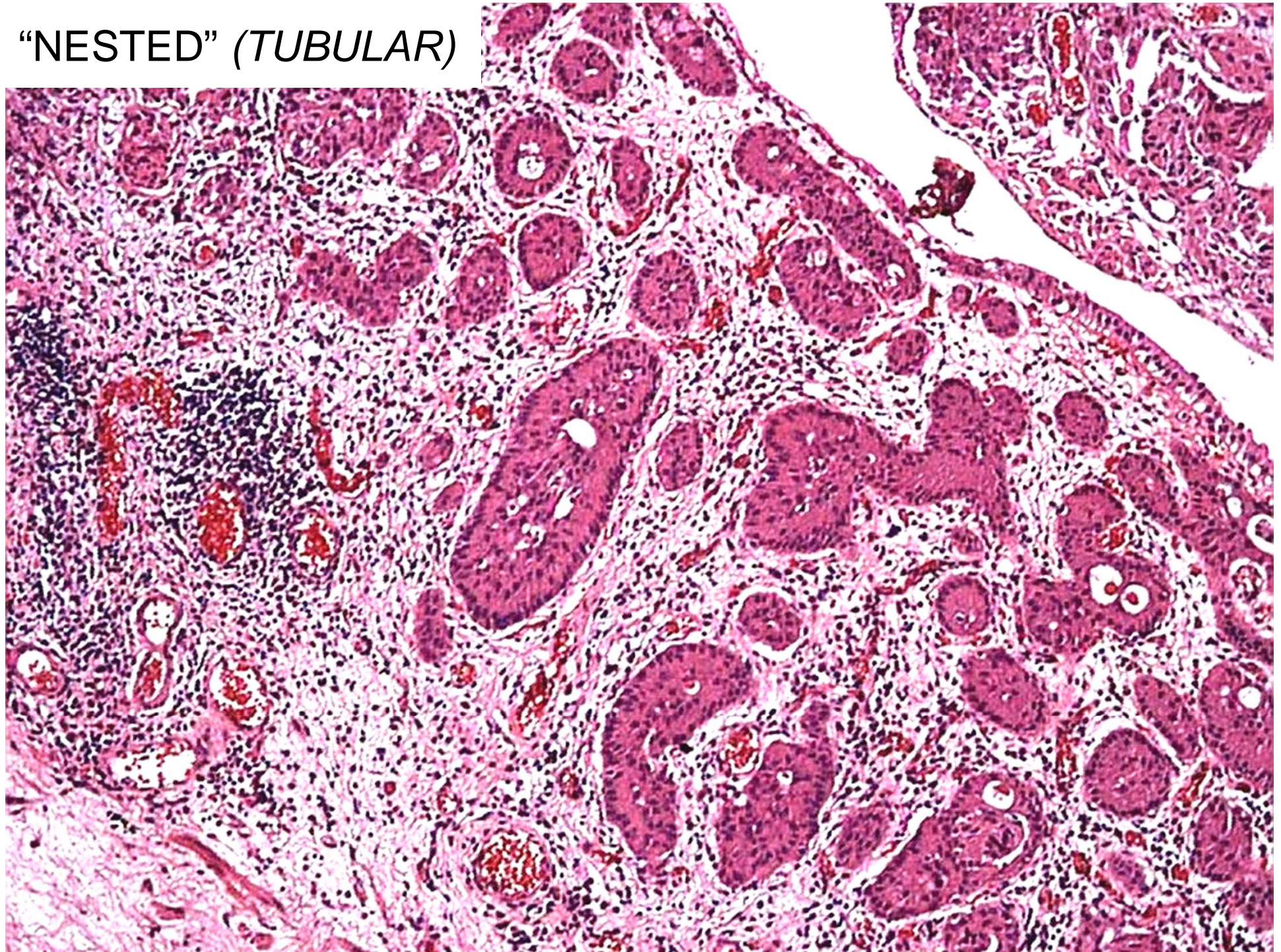
“NESTED”



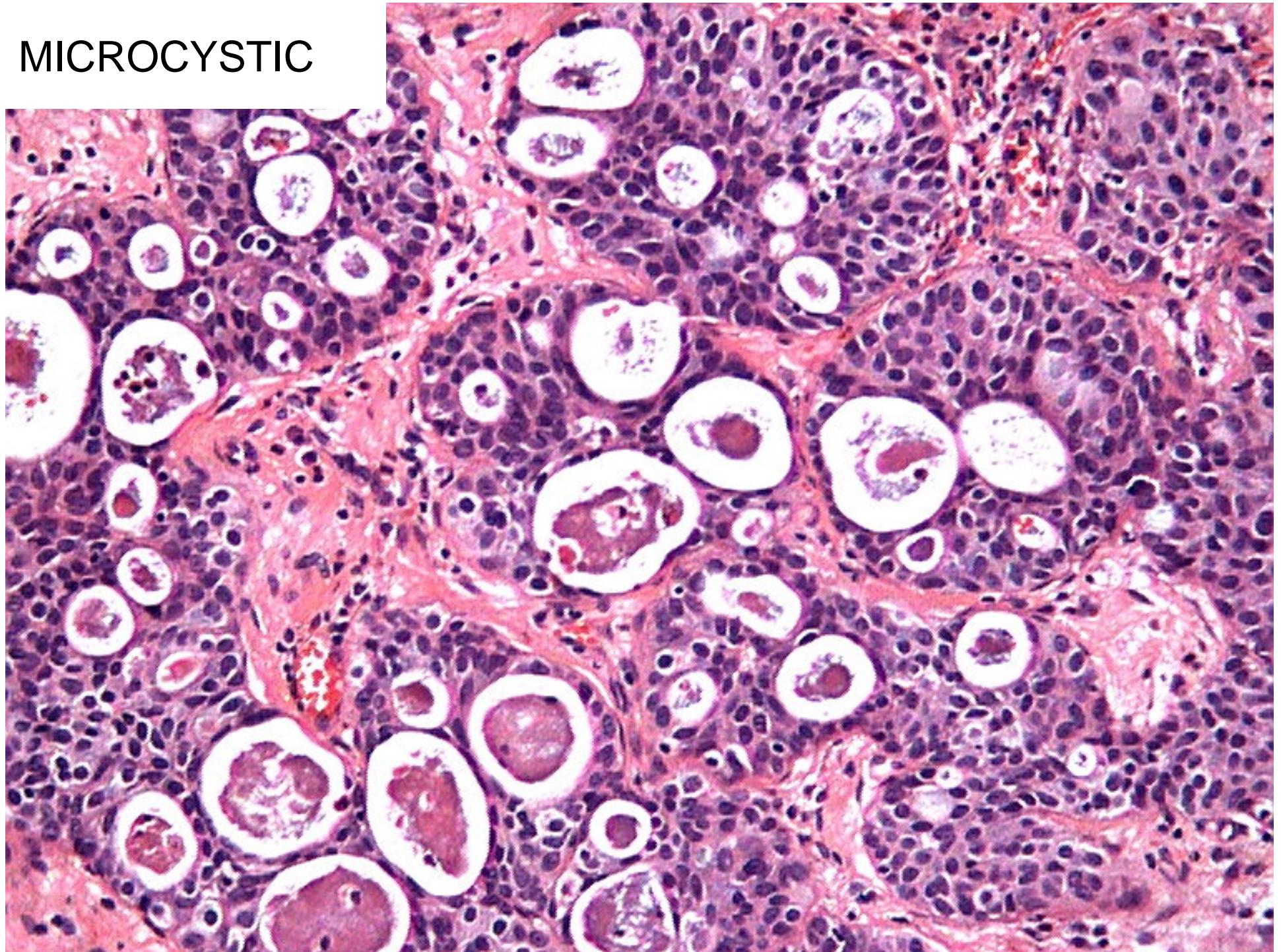
“NESTED”



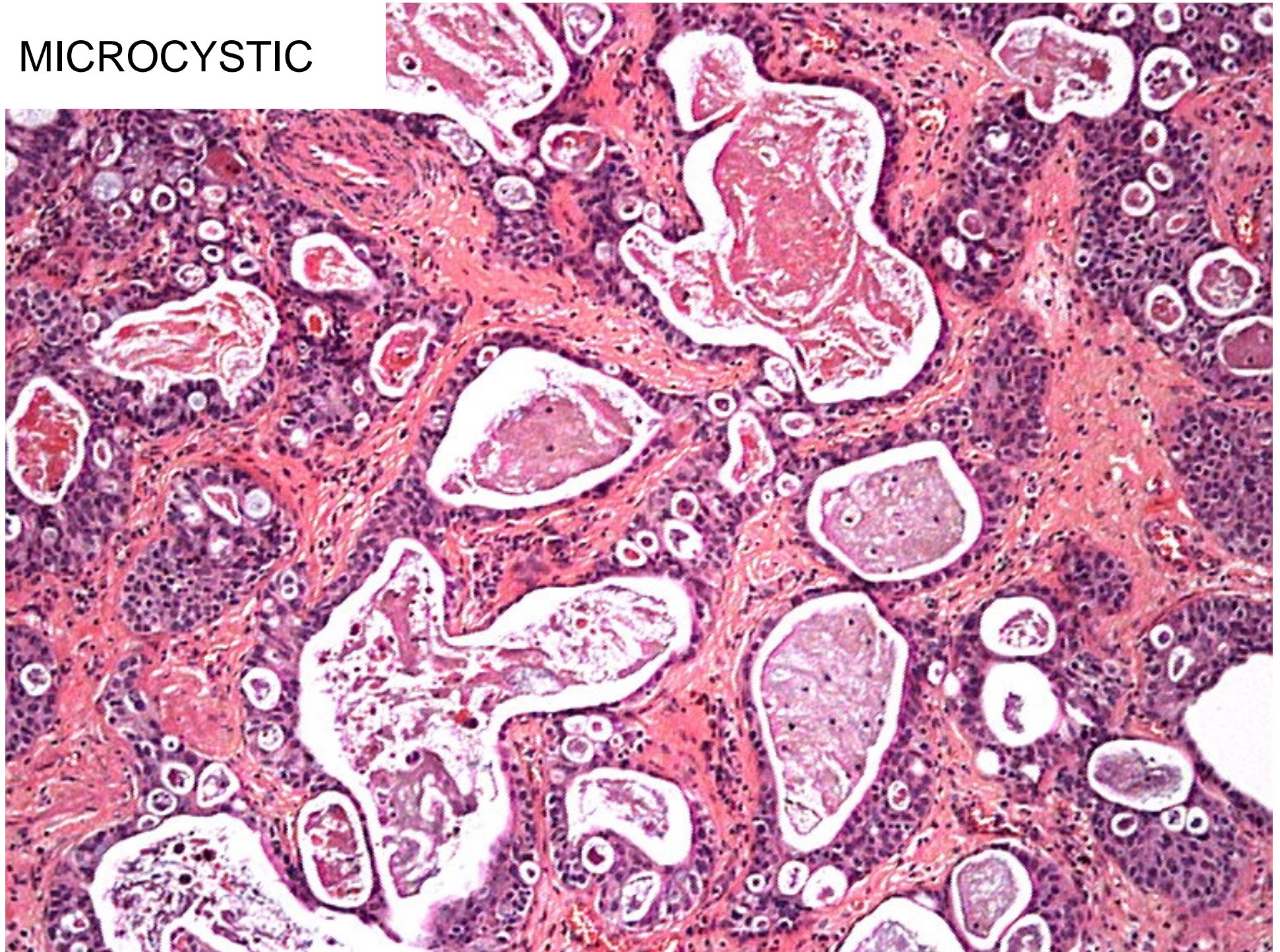
“NESTED” (*TUBULAR*)



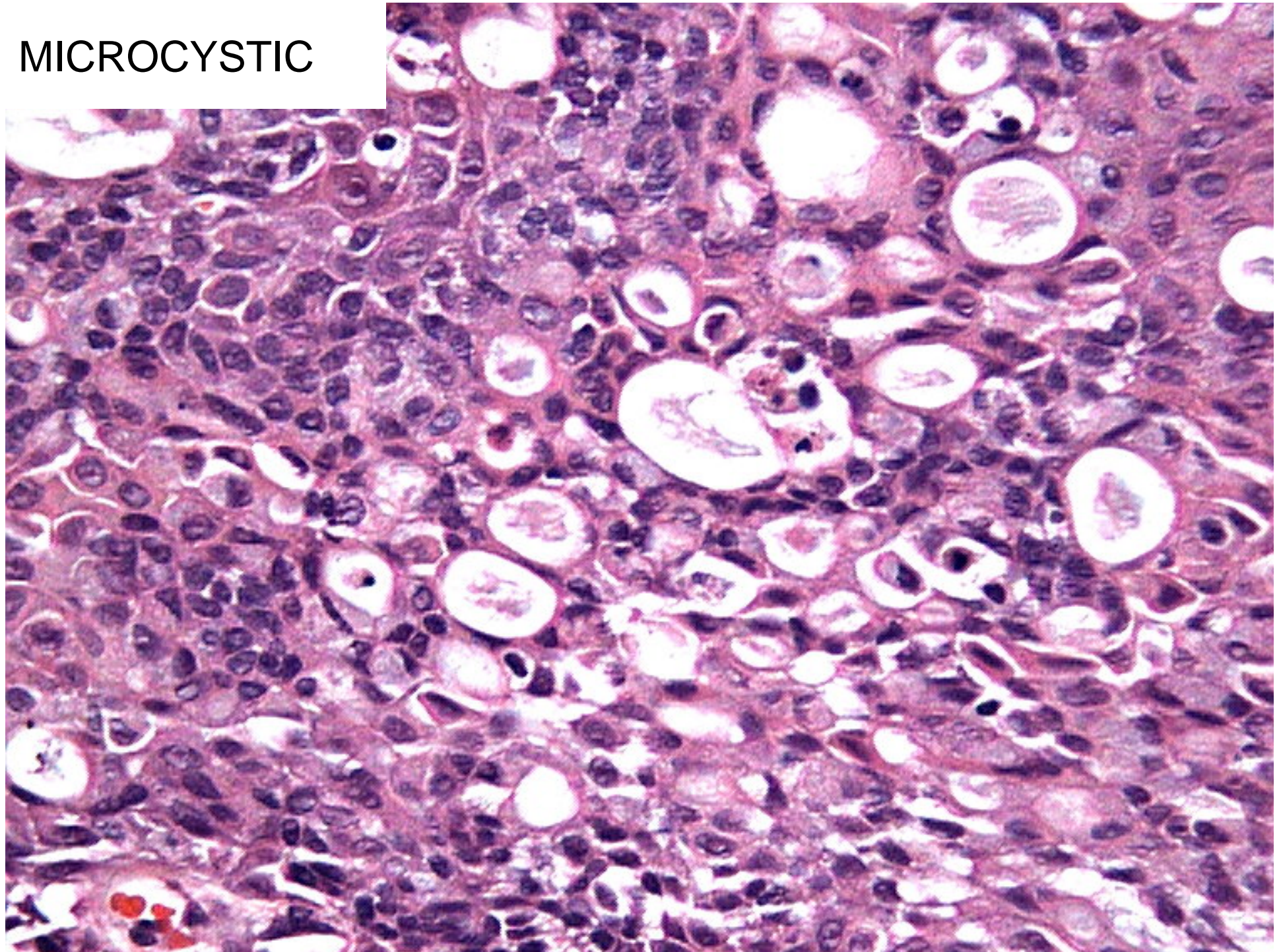
MICROCYSTIC

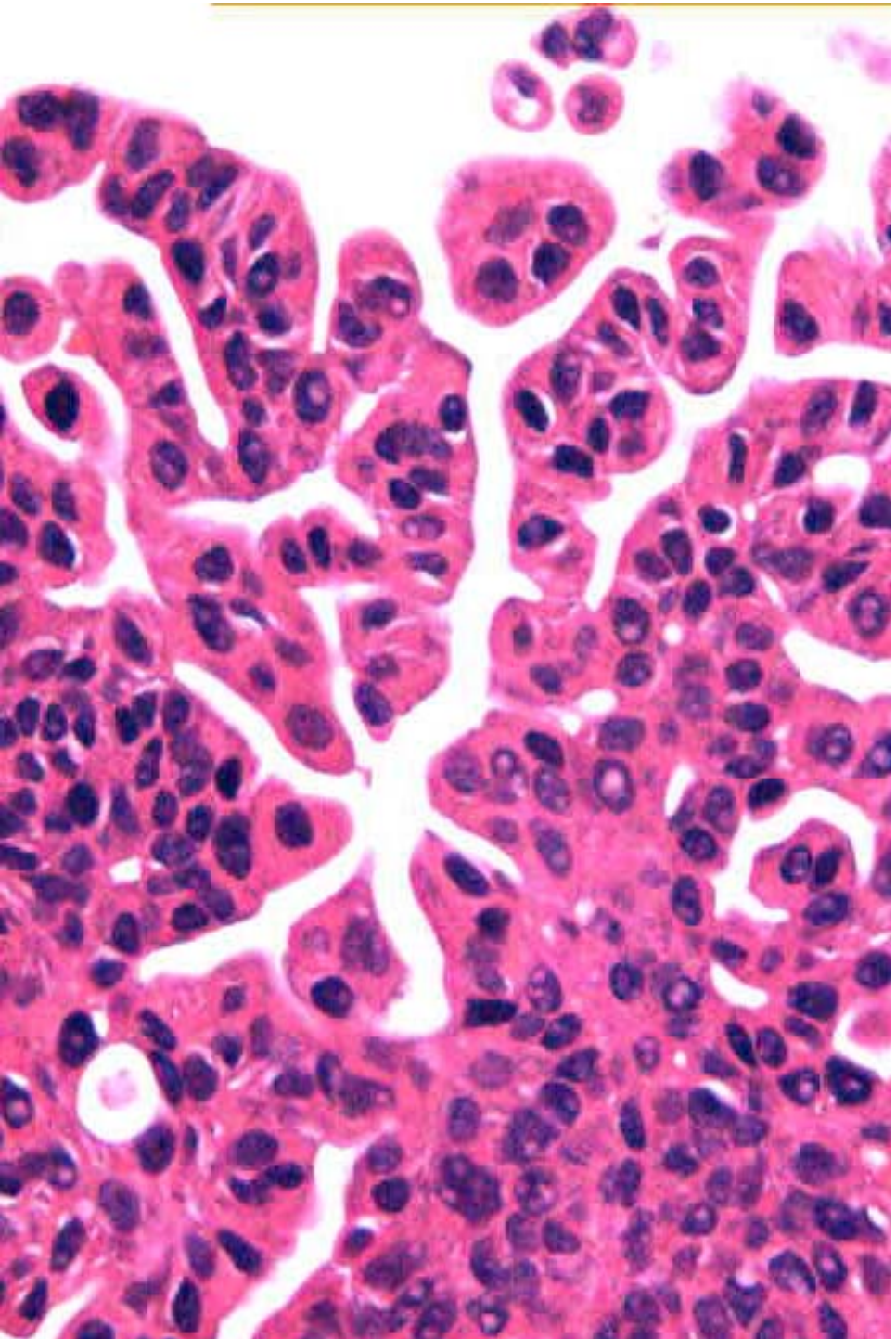
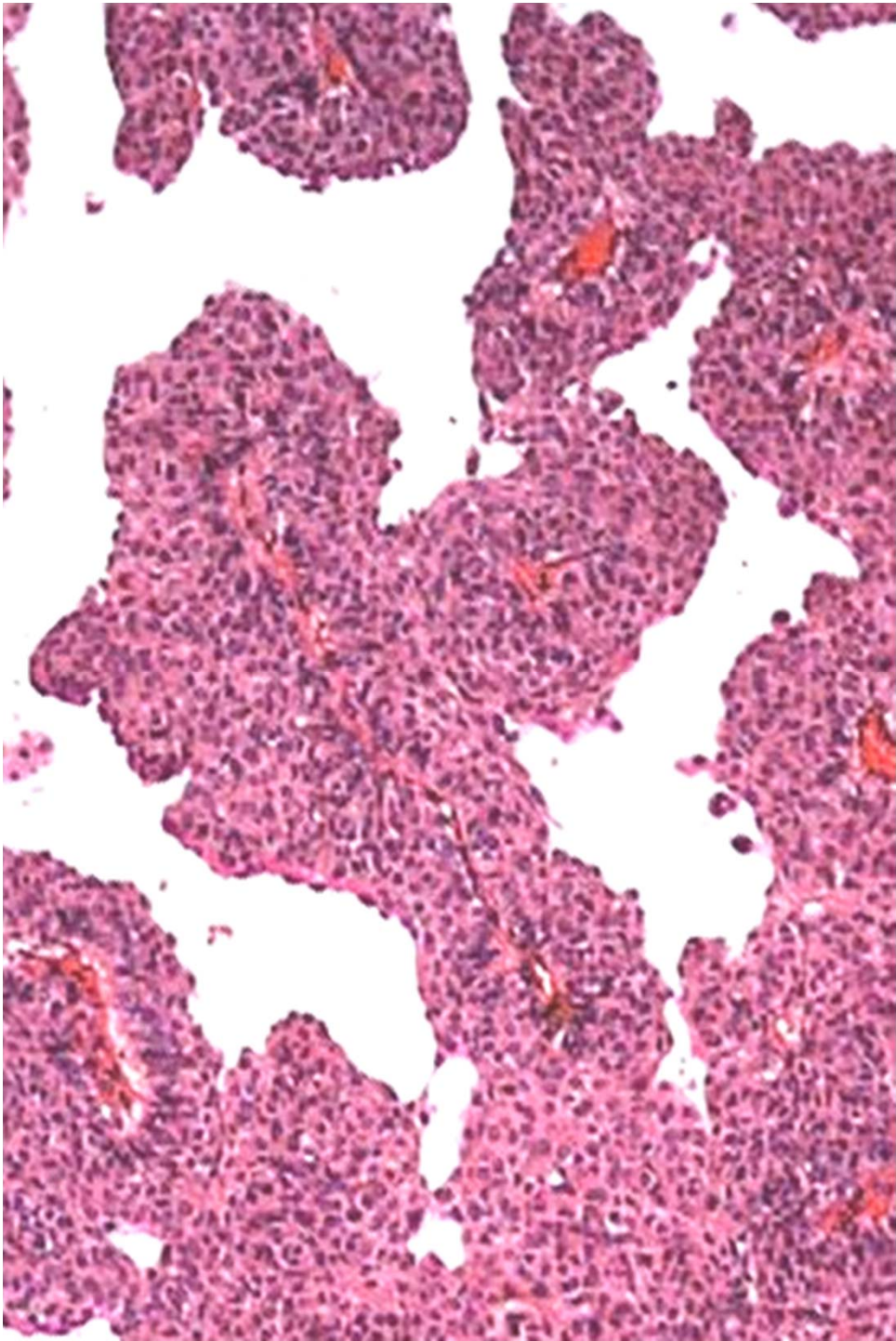


MICROCYSTIC

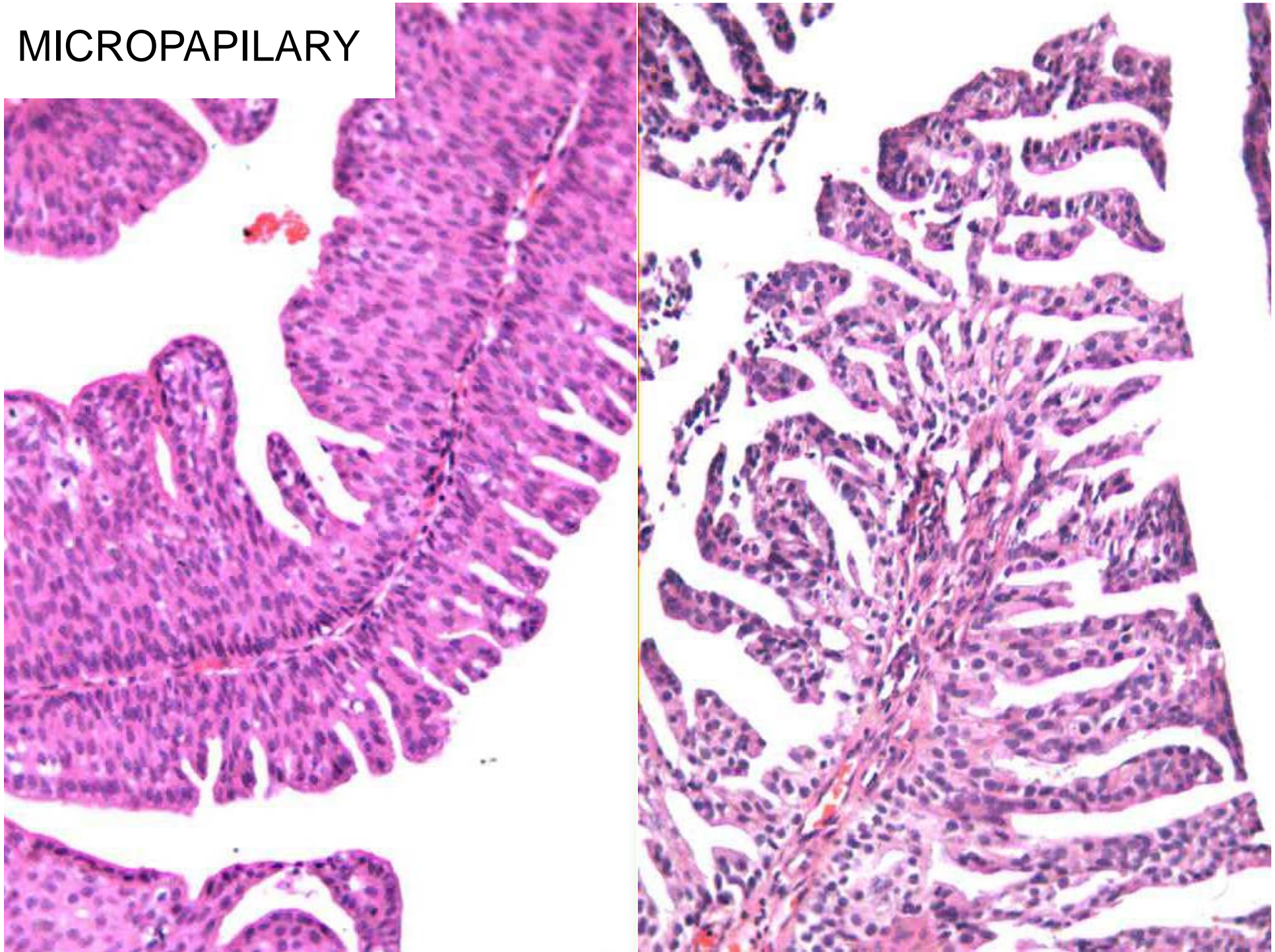


MICROCYSTIC

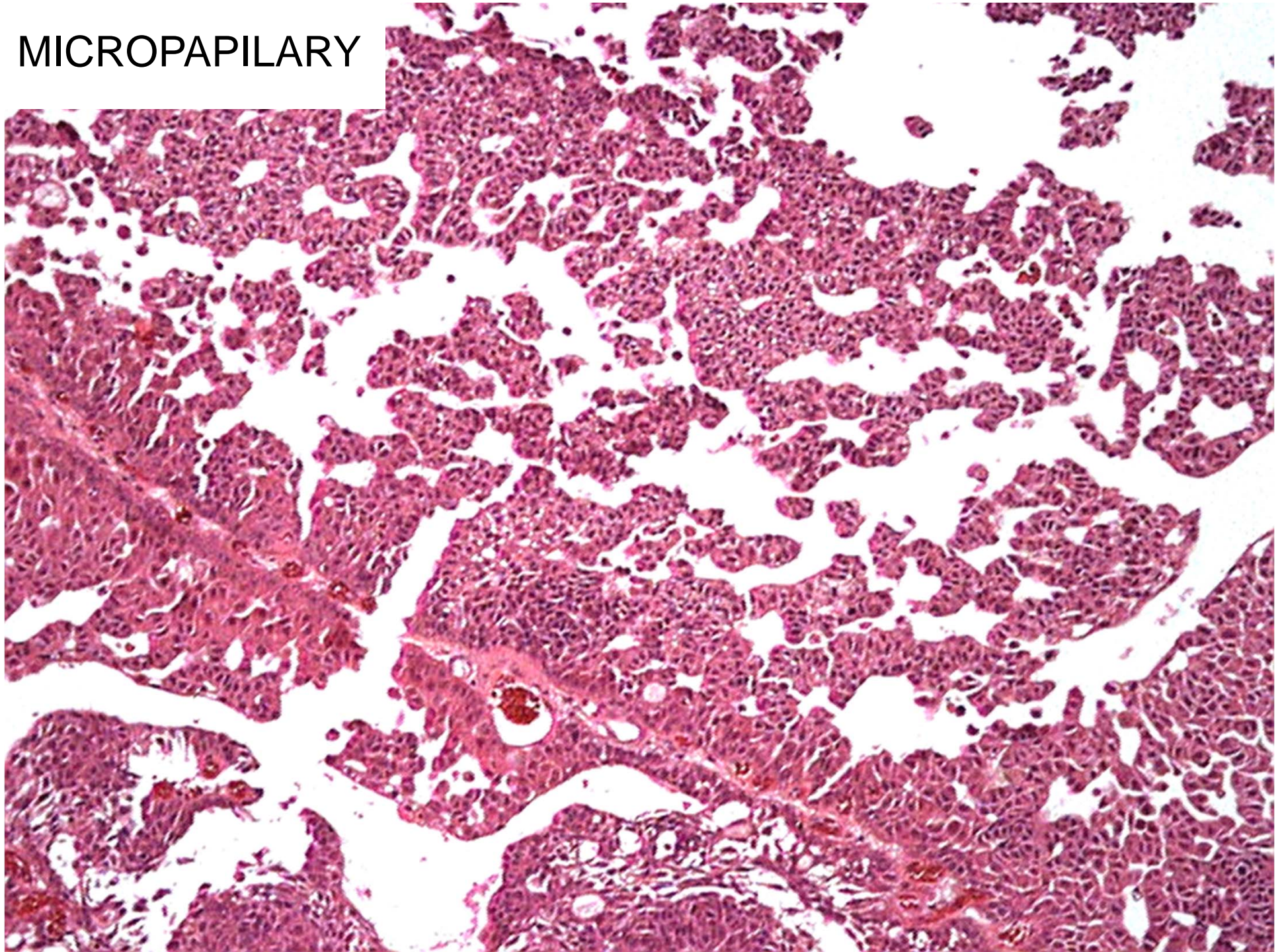




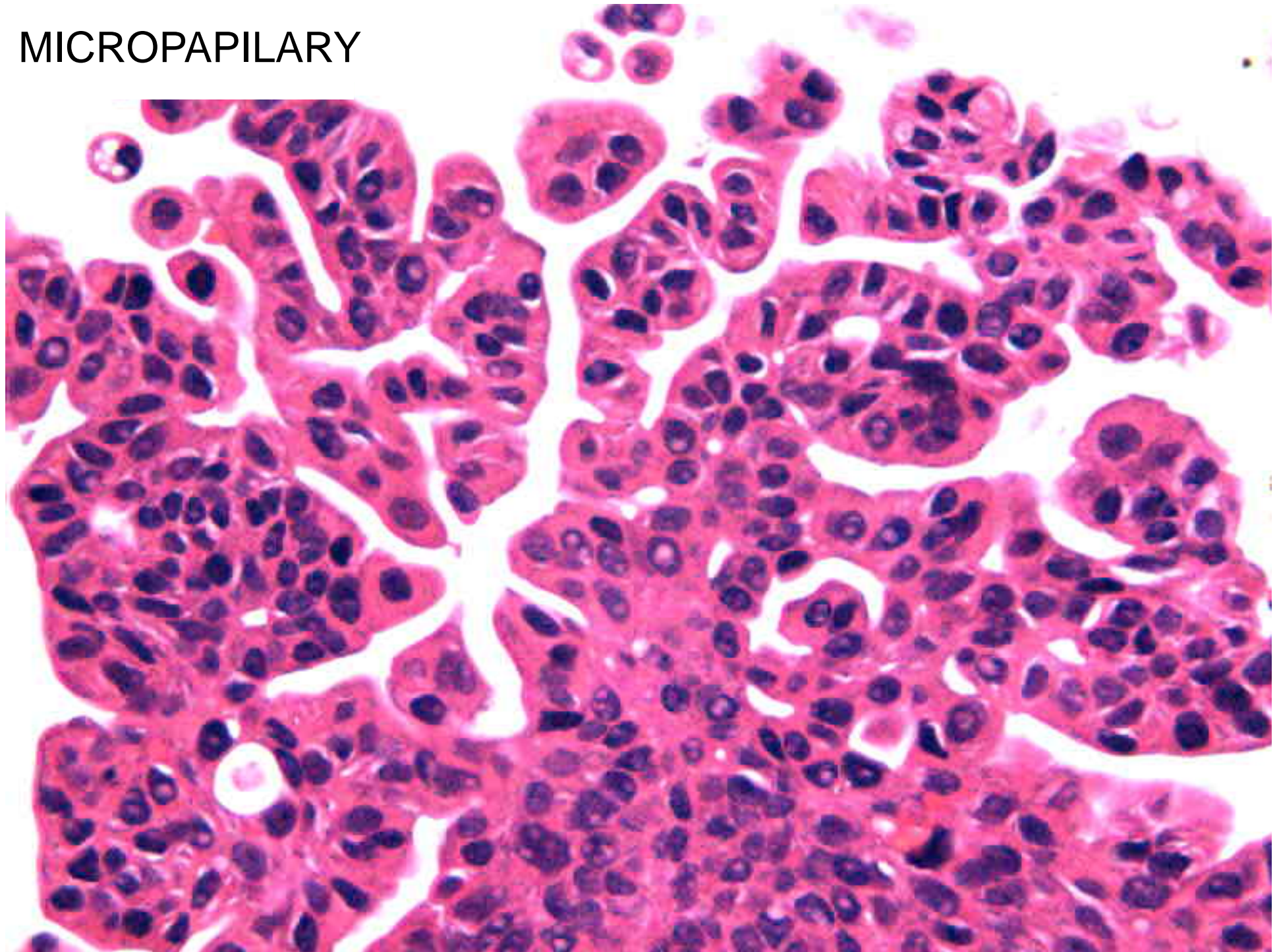
MICROPAPILARY



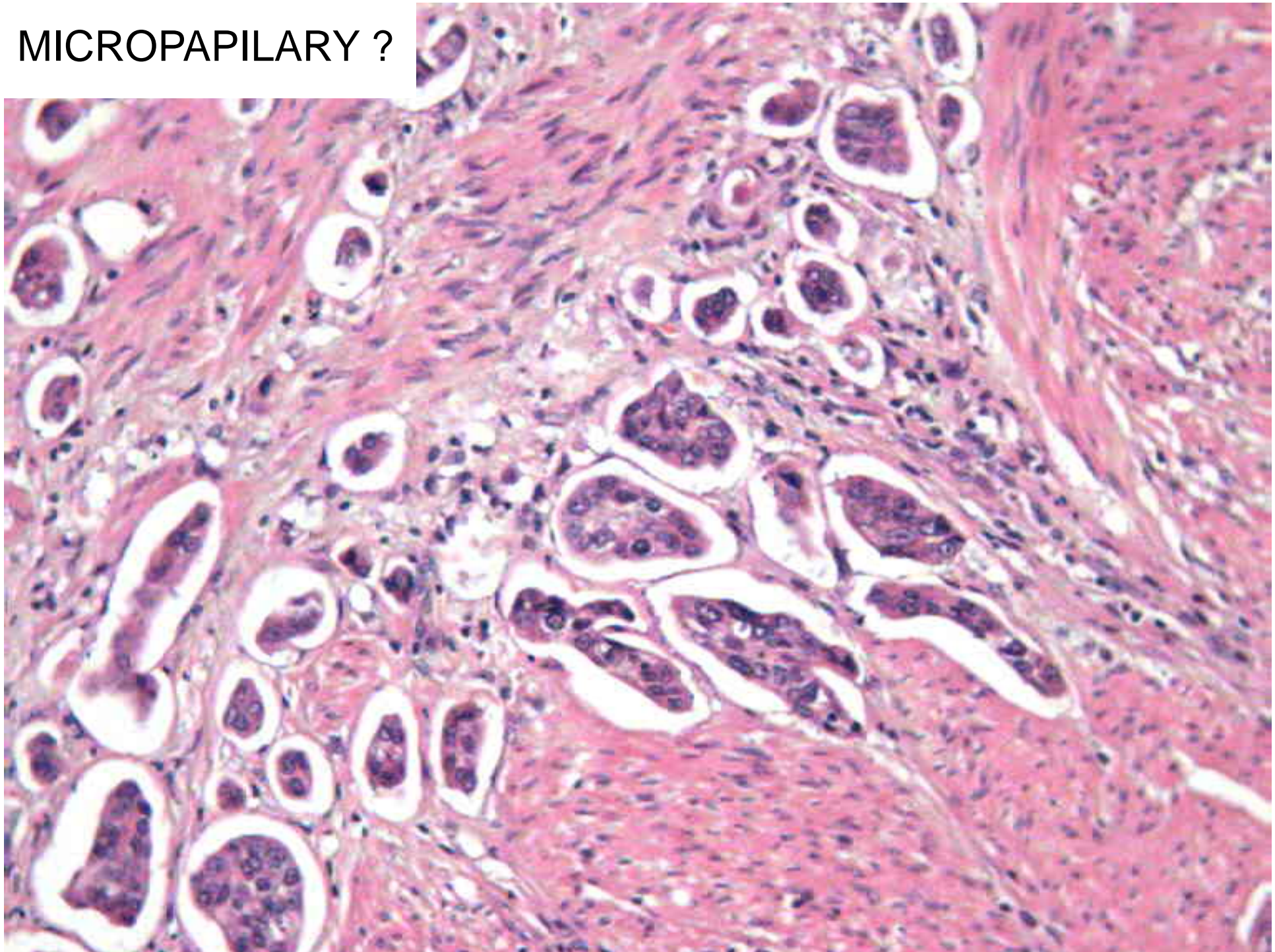
MICROPAPILARY



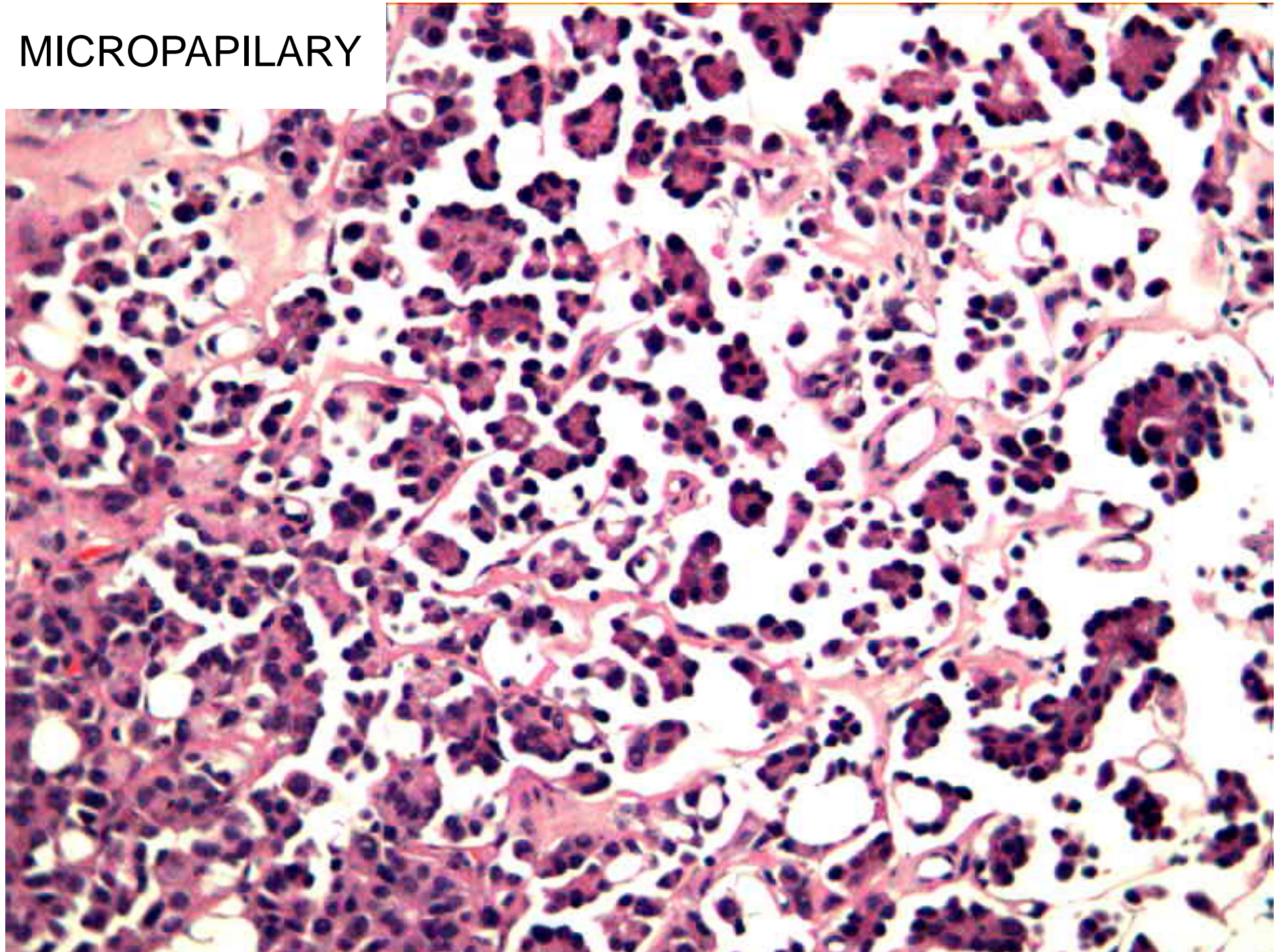
MICROPAPILARY



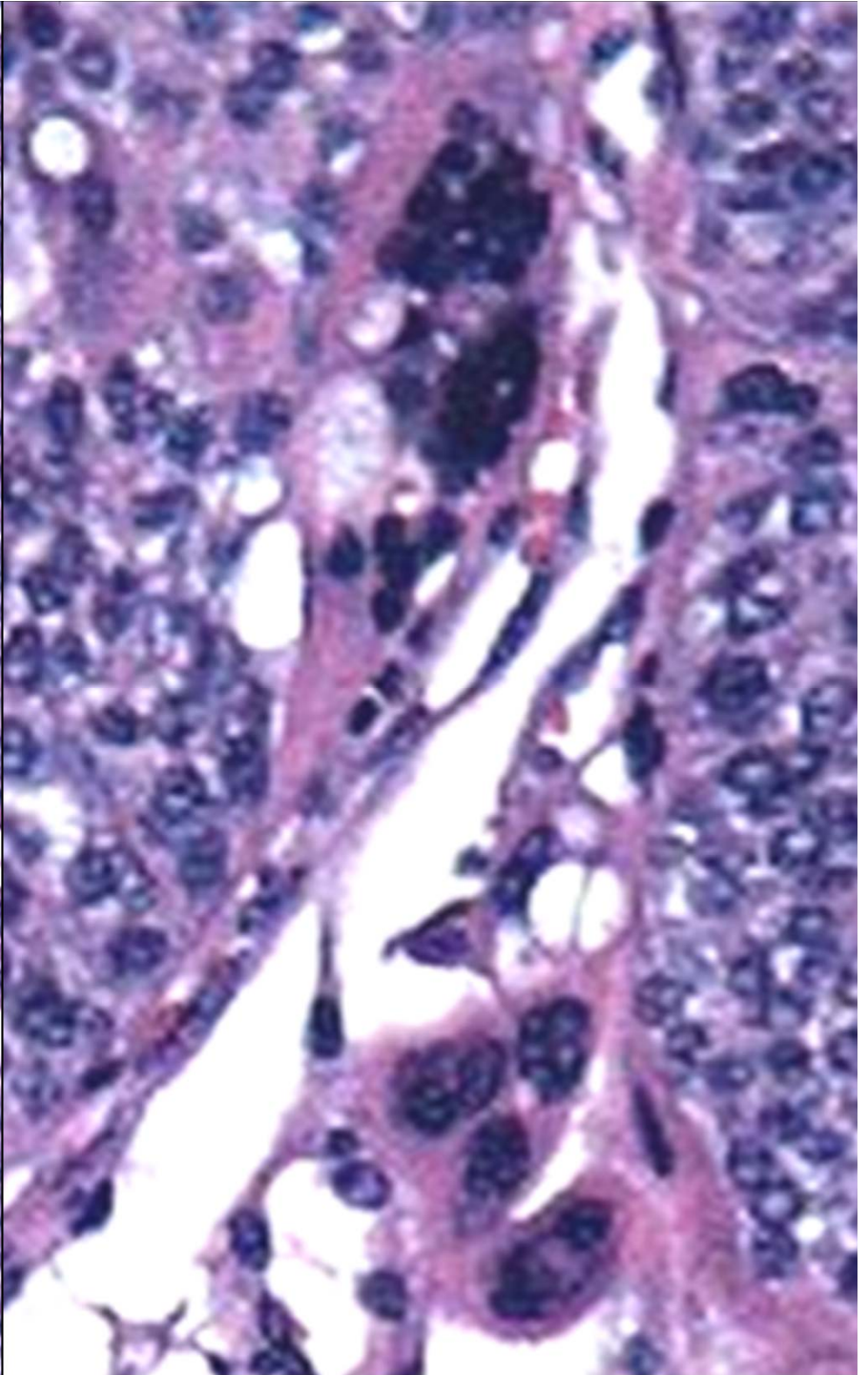
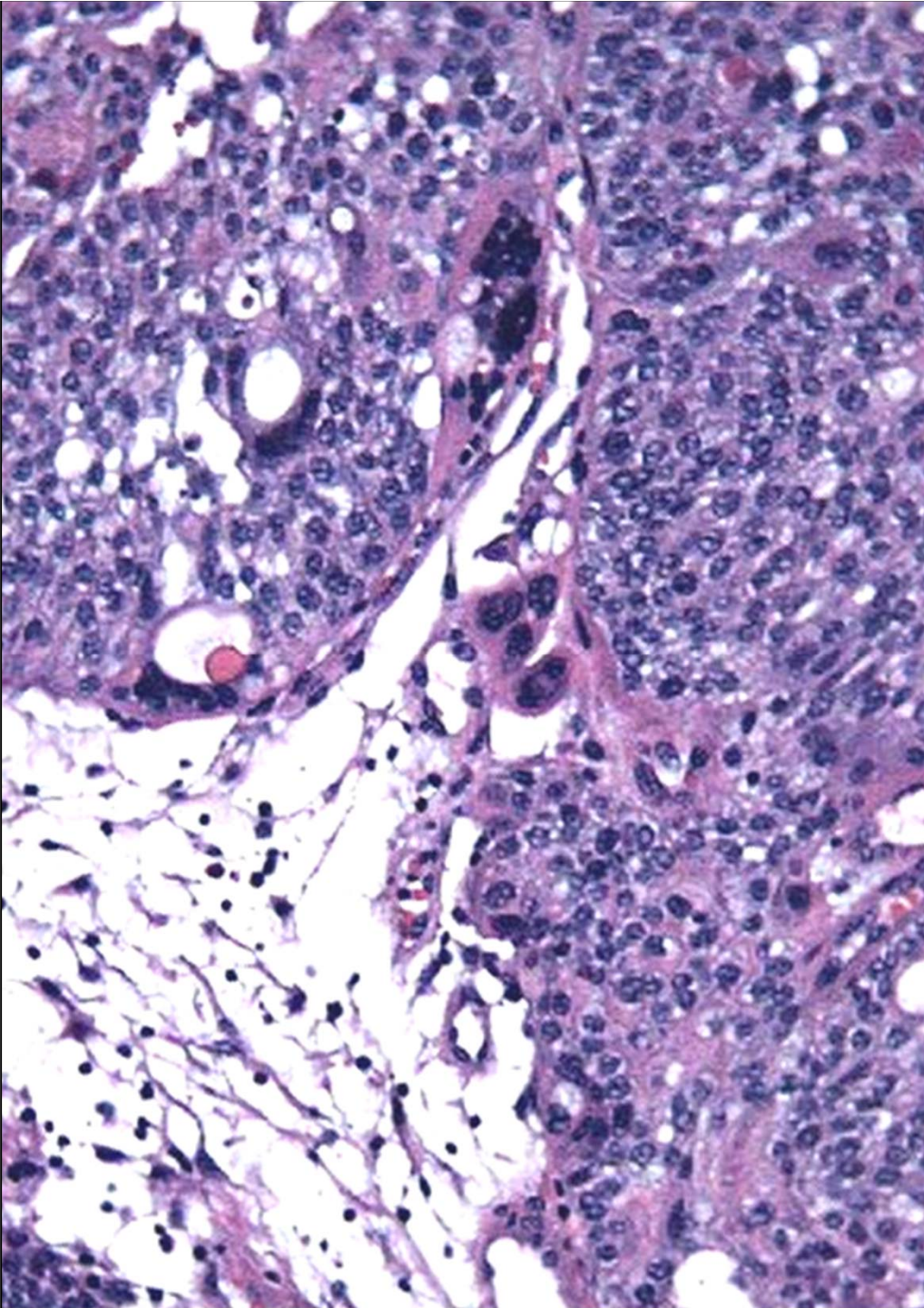
MICROPAPILARY ?

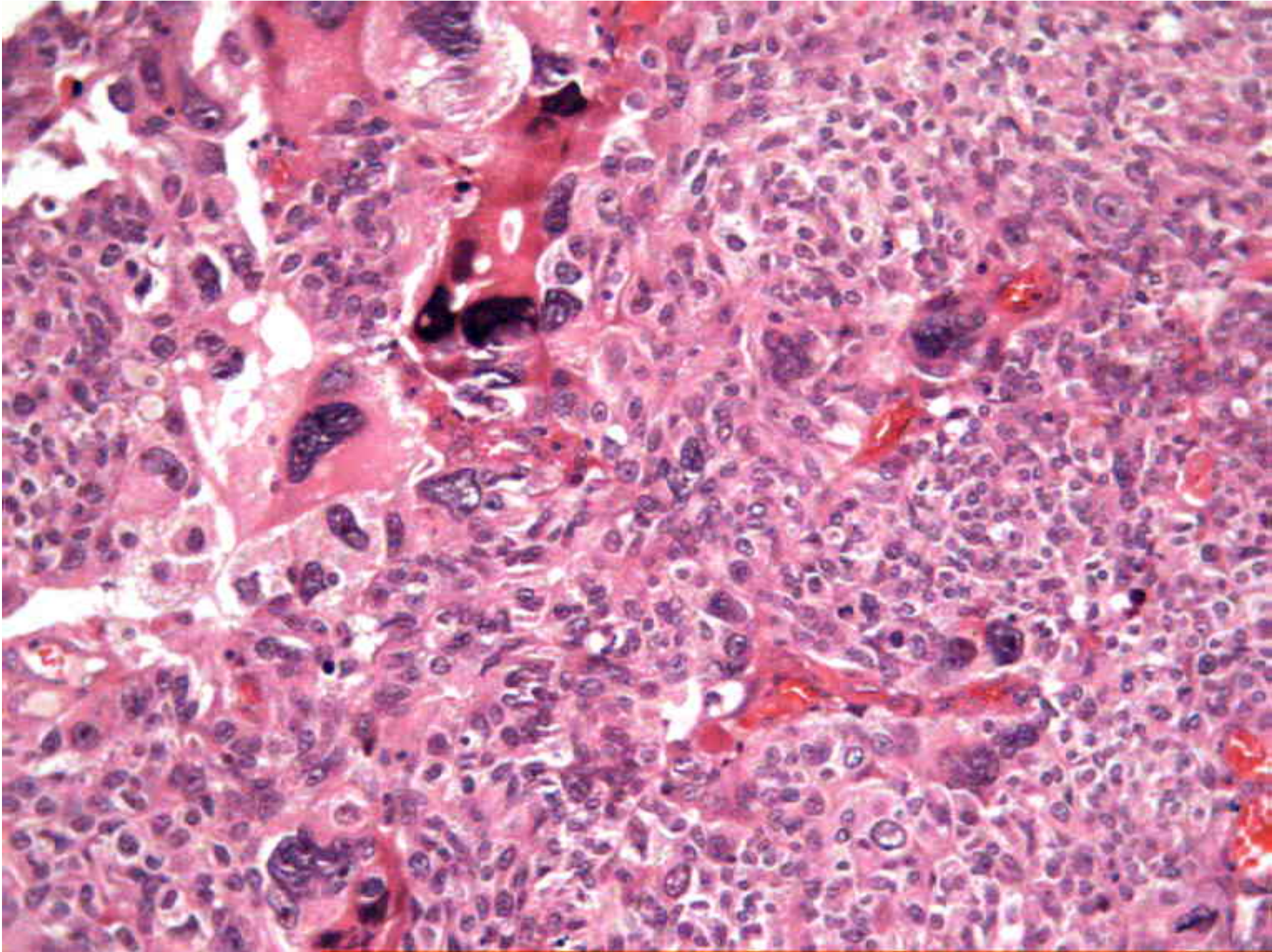


MICROPAPILARY

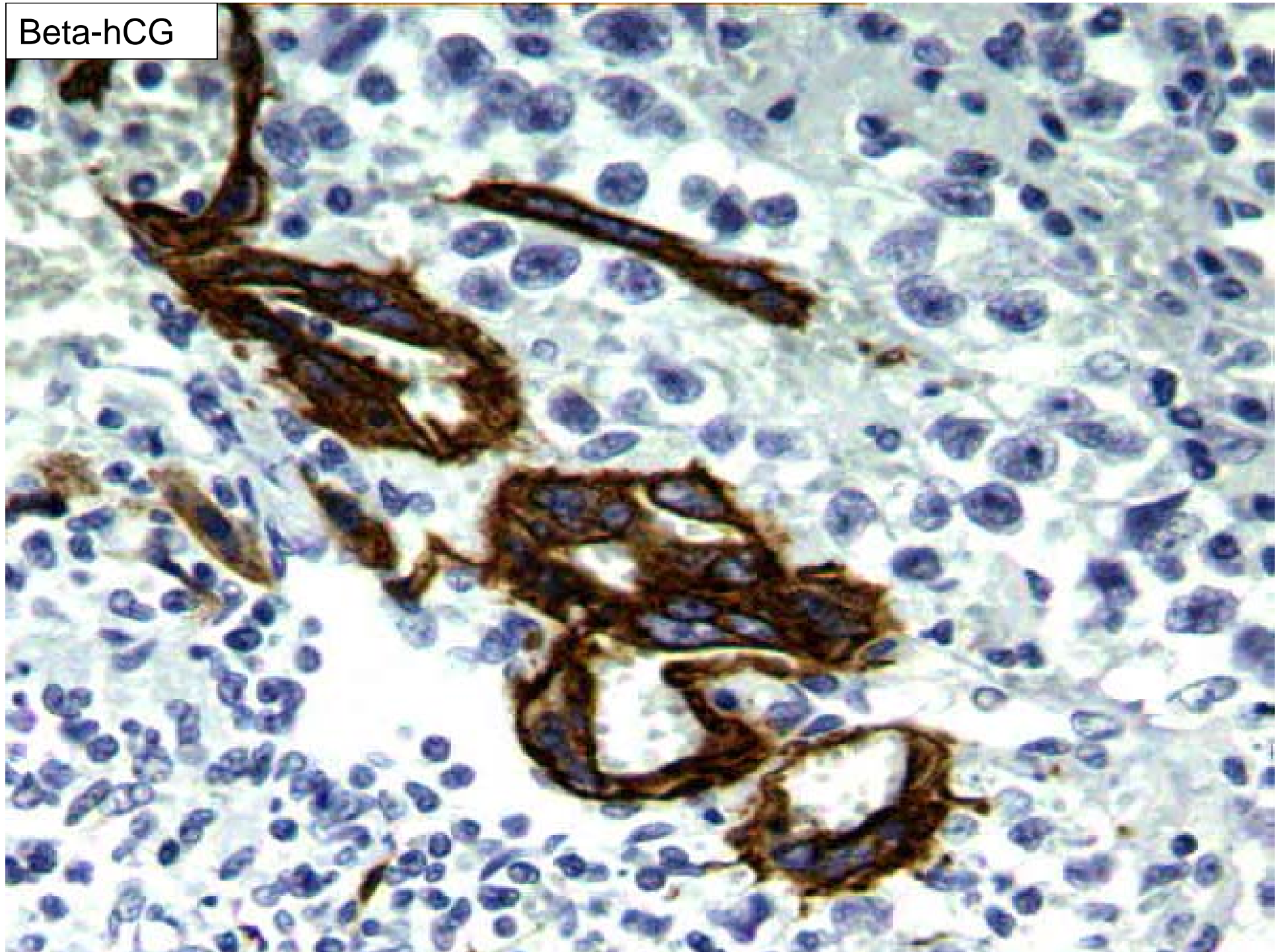


Micropapillary carcinoma

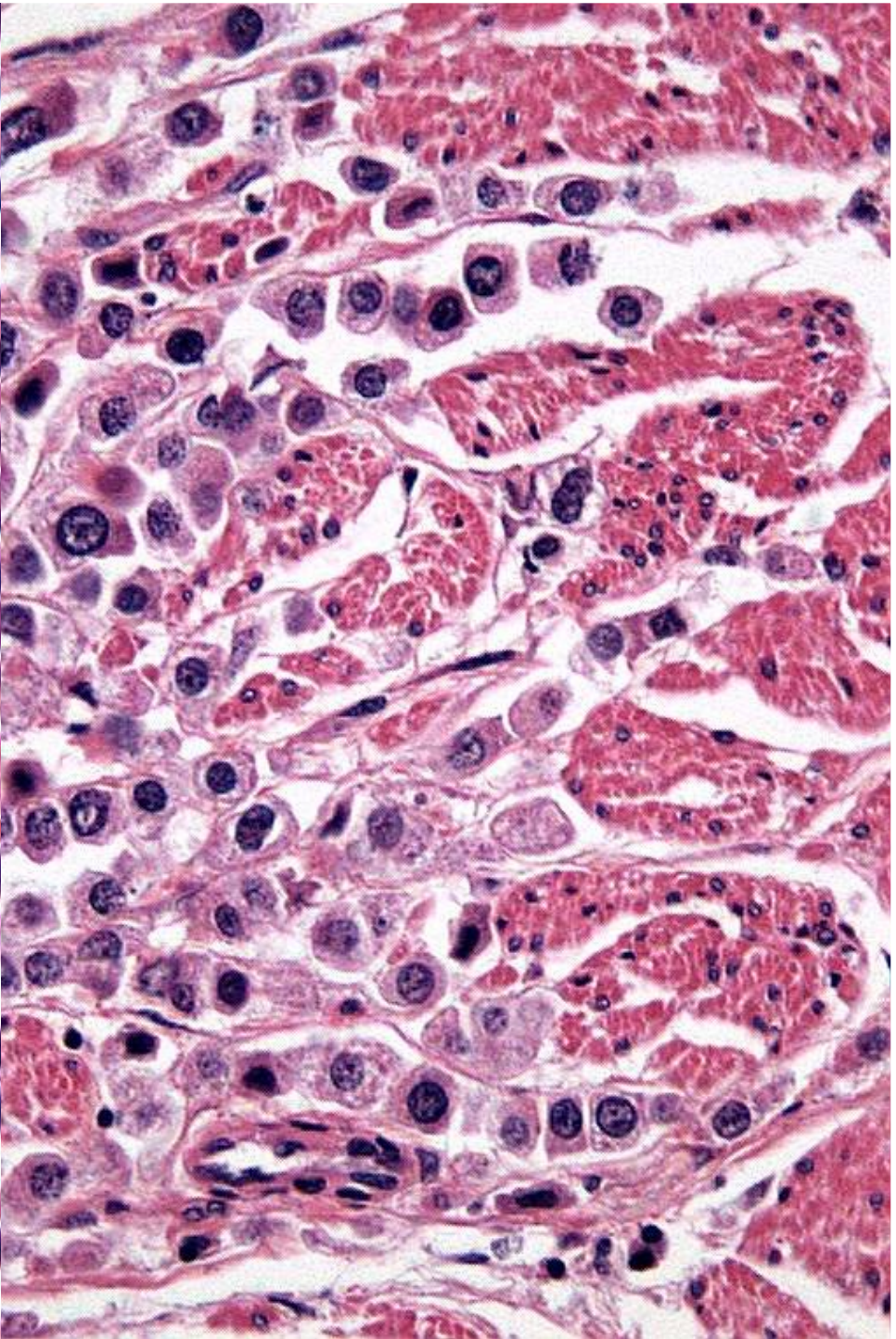
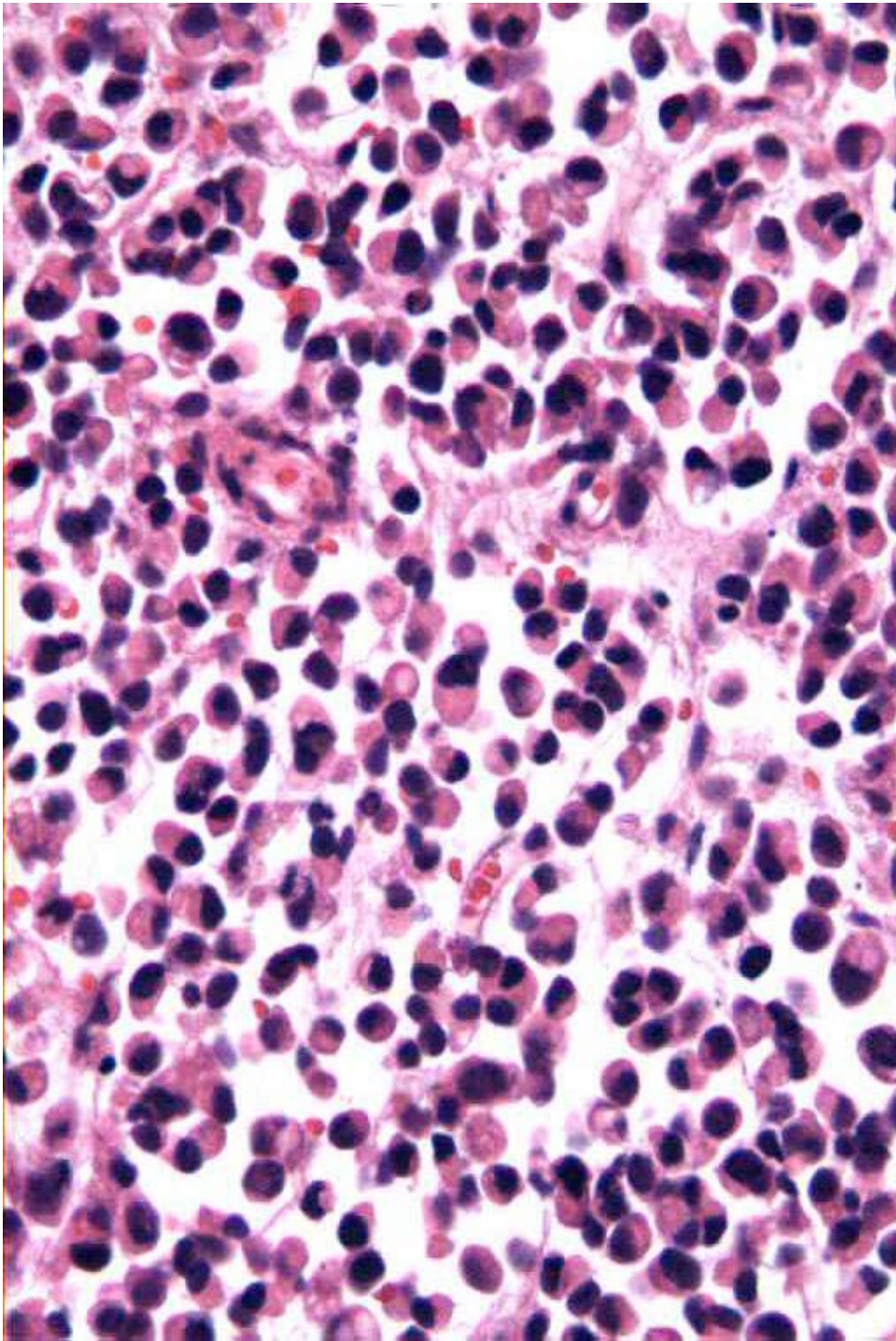




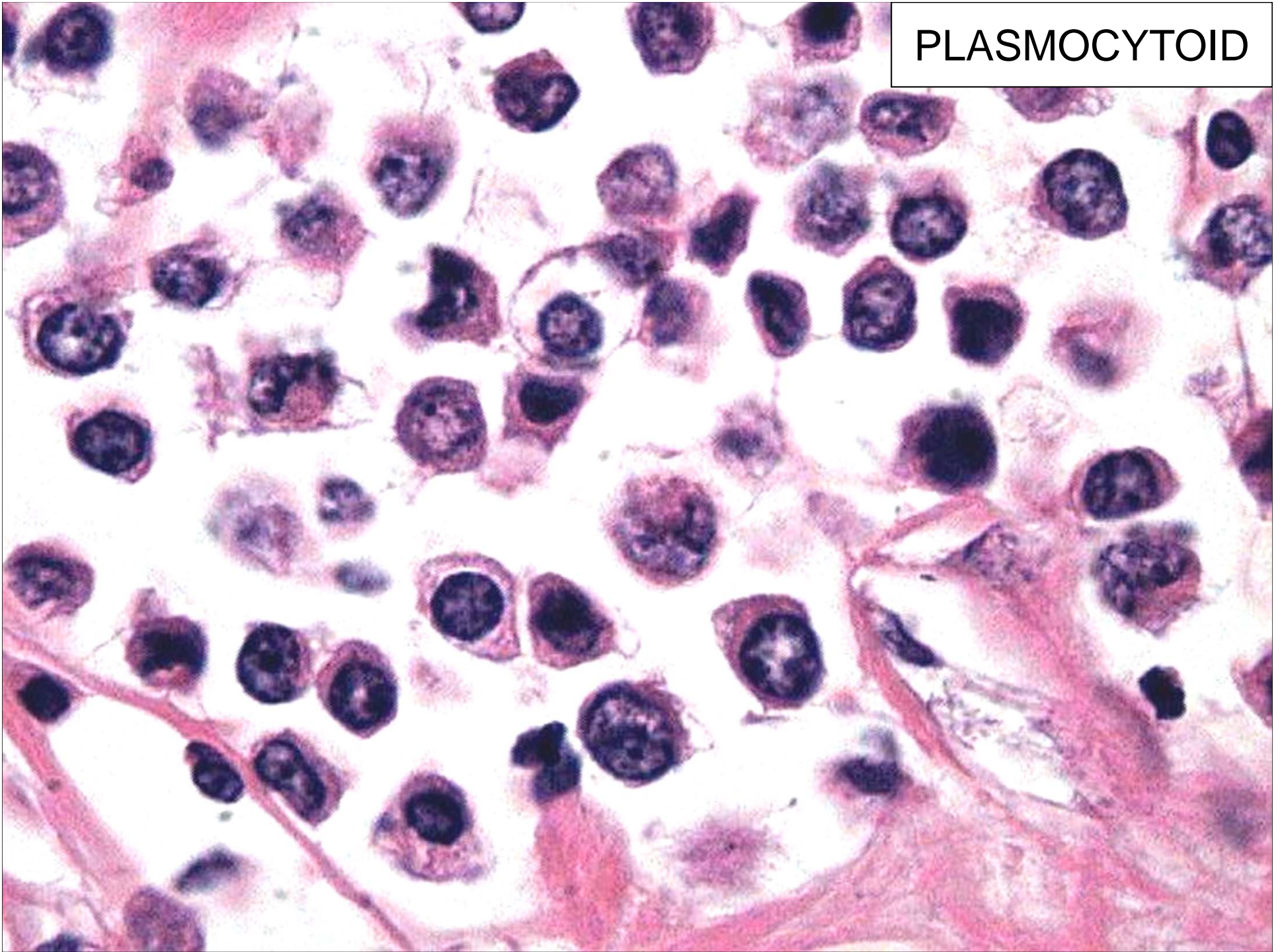
Beta-hCG



Urothelial carcinoma with trophoblastic differentiation



PLASMOCYTOID



Plasmocytoid carcinoma