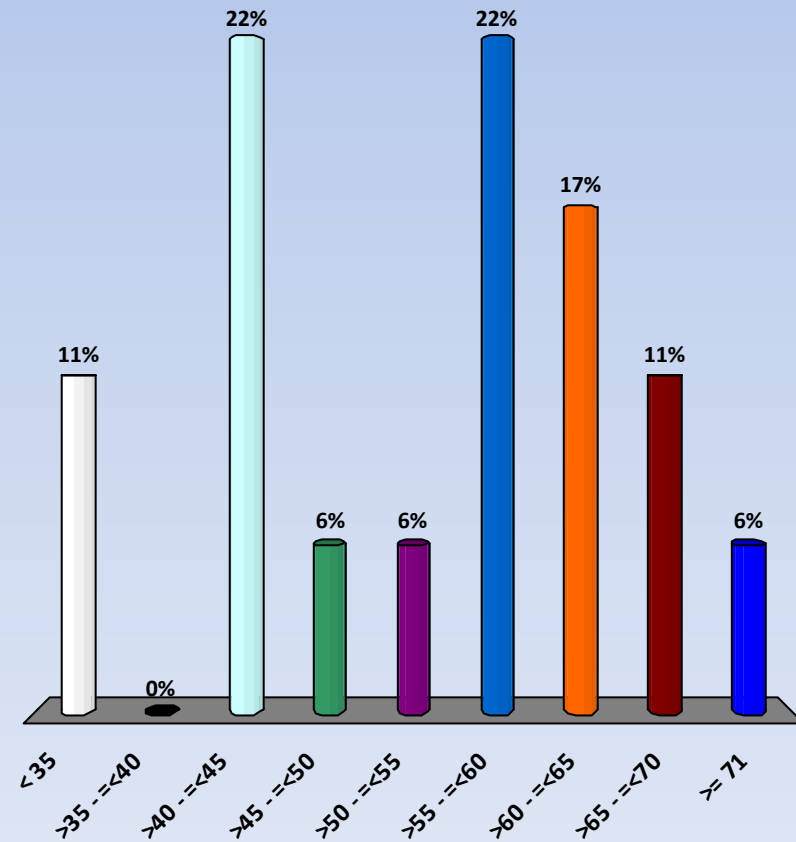




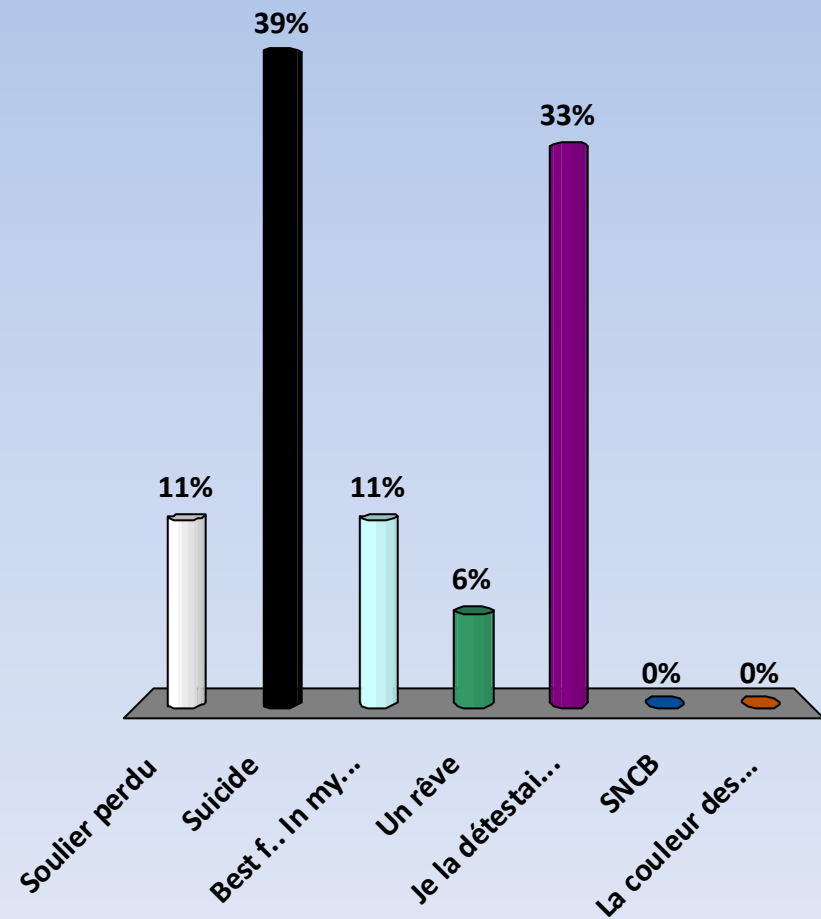
Age?

1. < 35
2. >35 - =<40
3. >40 - =<45
4. >45 - =<50
5. >50 - =<55
6. >55 - =<60
7. >60 - =<65
8. >65 - =<70
9. >= 71

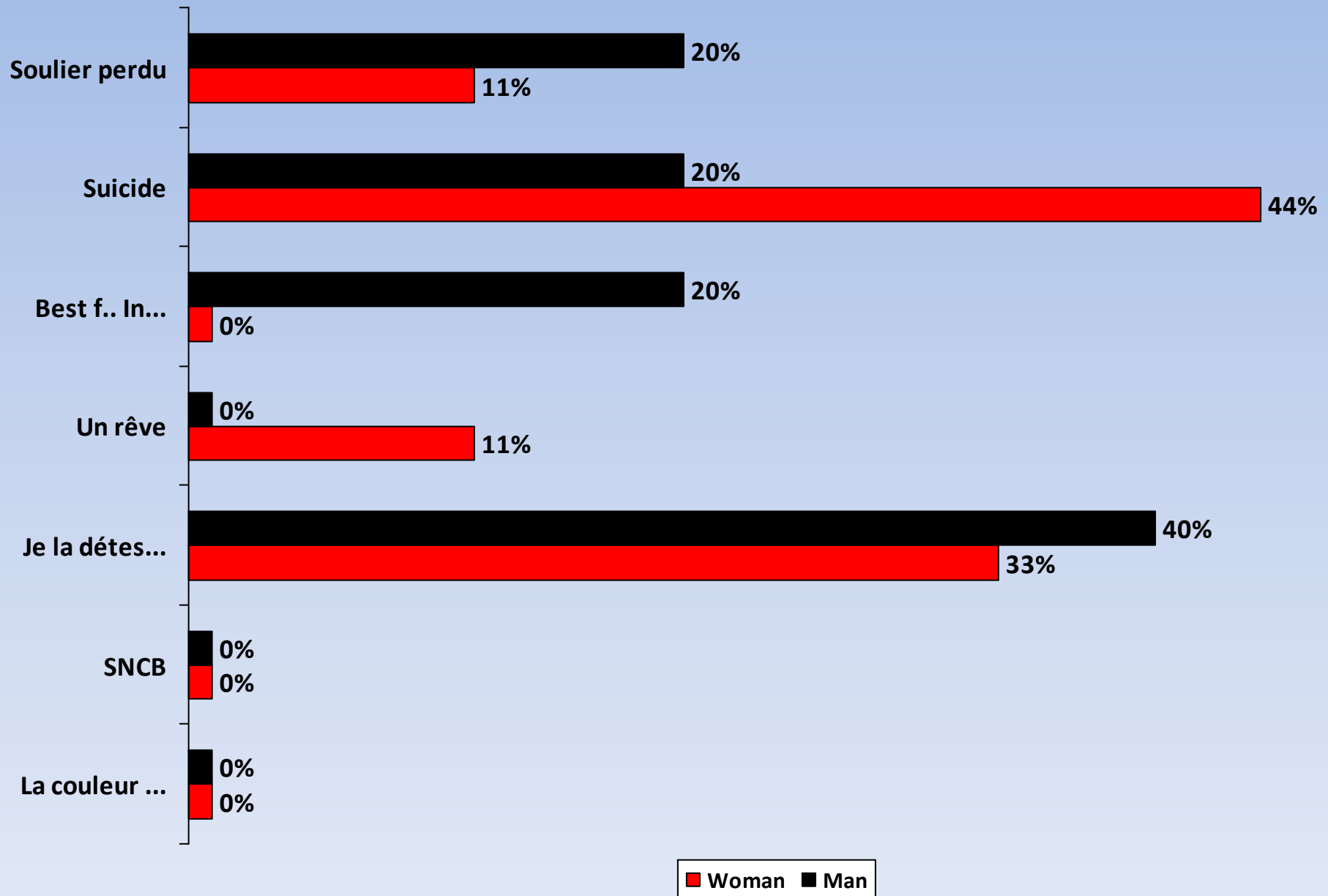


Voyage en train

1. Soulier perdu
2. Suicide
3. Best f.. In my life
4. Un rêve
5. Je la détestais!
6. SNCB
7. La couleur des rails ..



Voyage en train

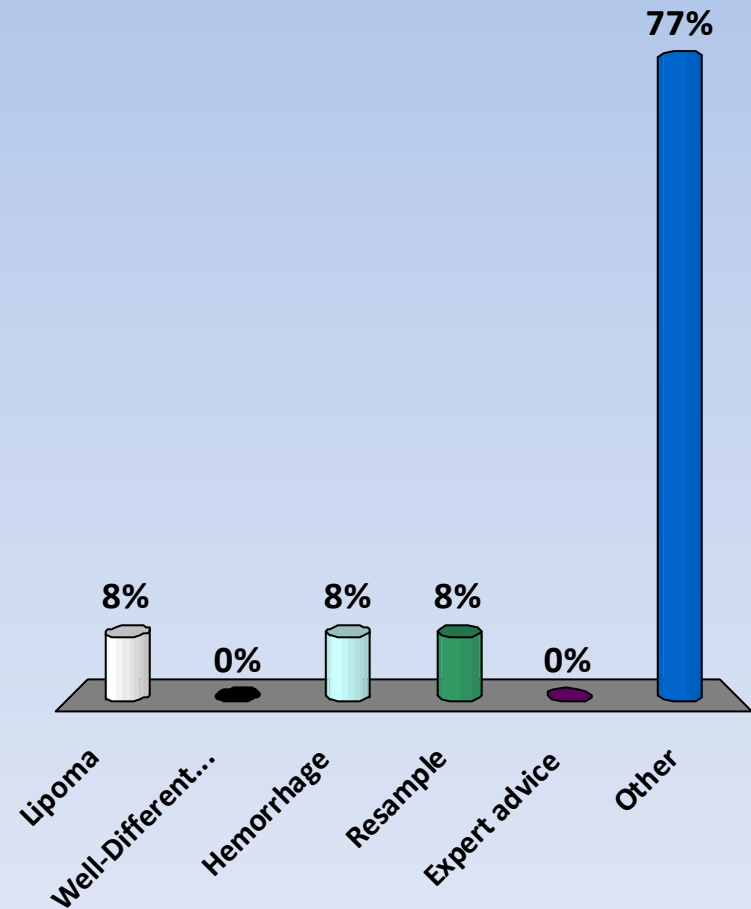


Case N°1

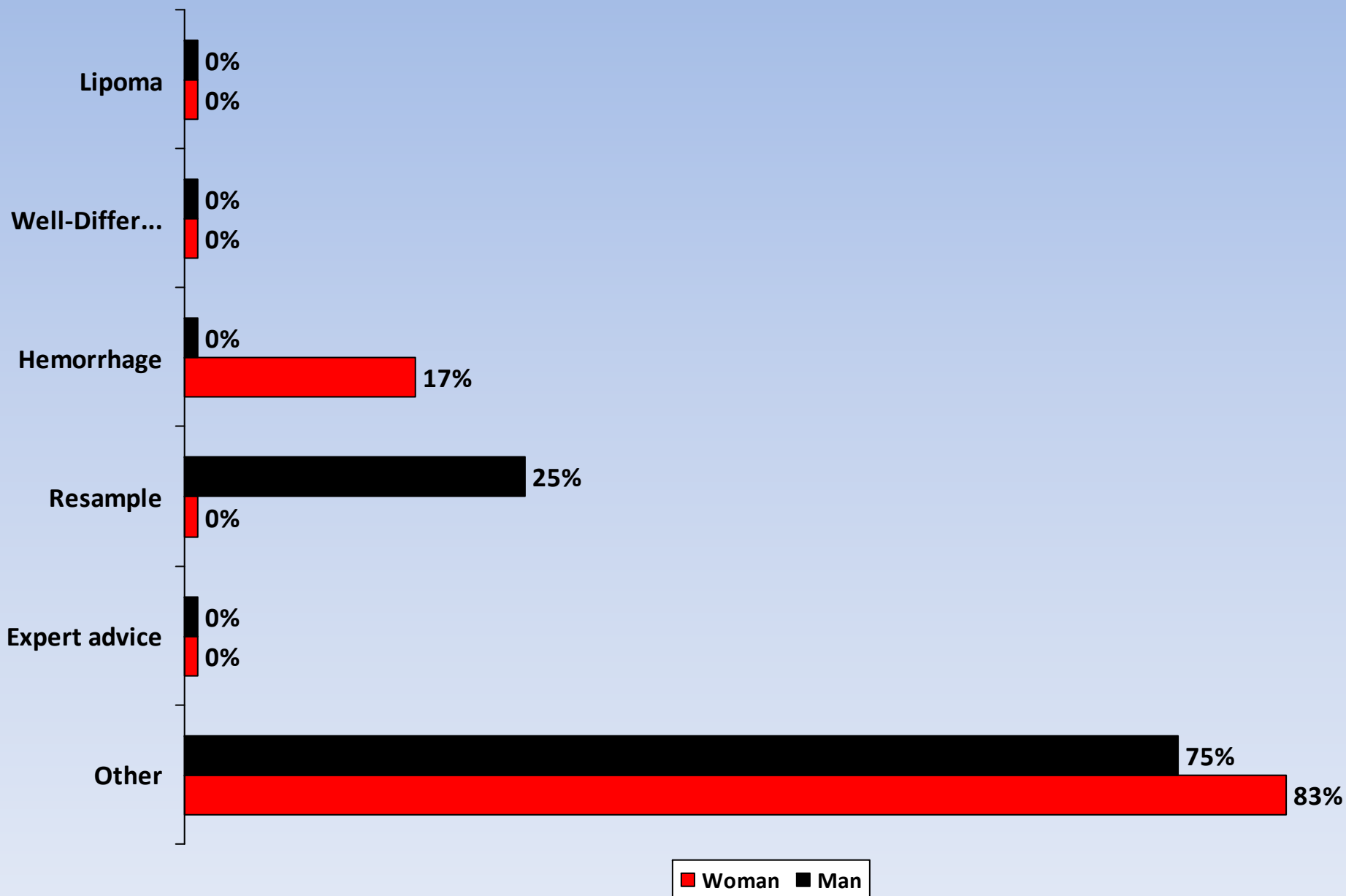


Cas N°1. Diagnostic?

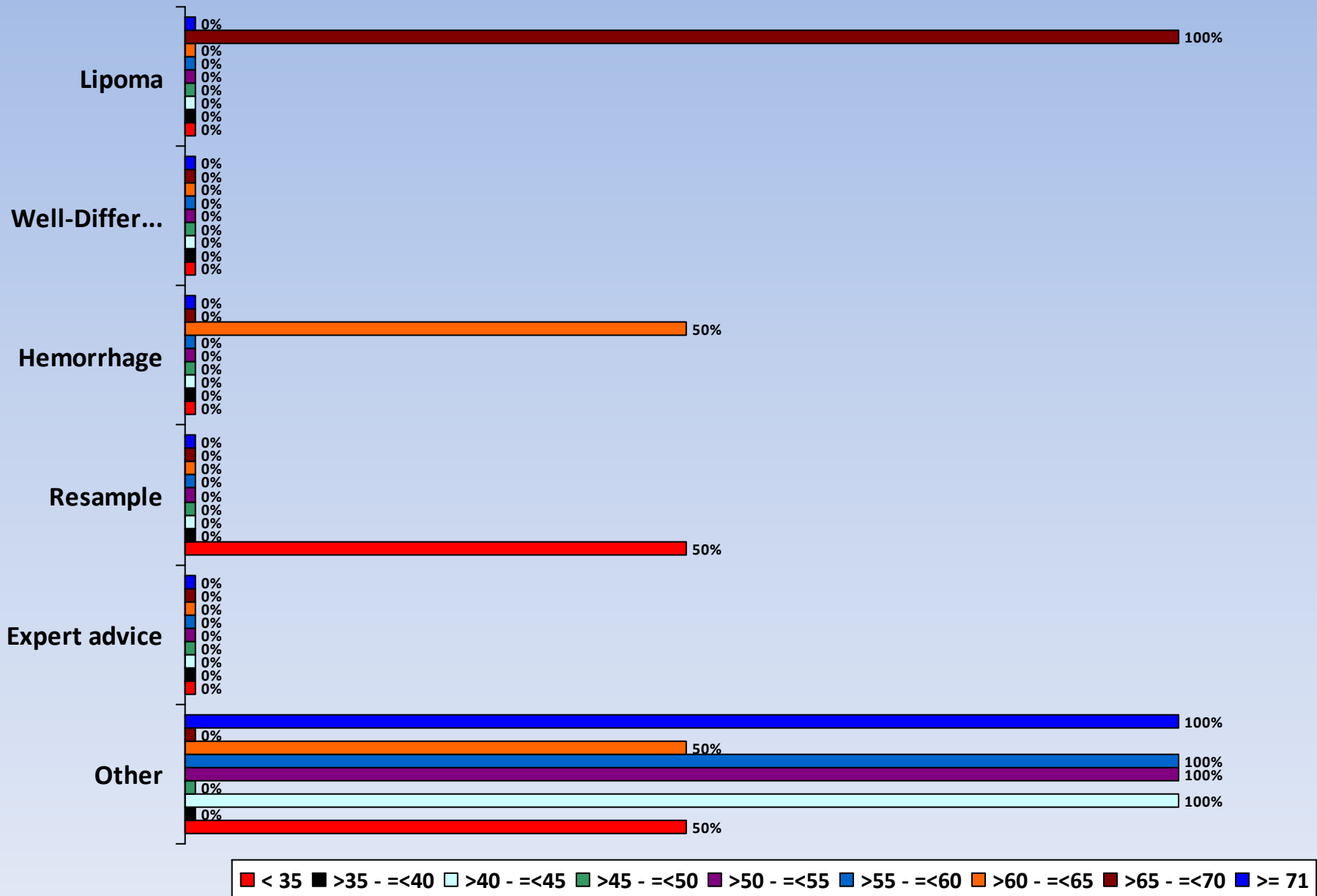
1. Lipoma
2. Well-Differentiated Liposarcoma
3. Hemorrhage
4. Resample
5. Expert advice
6. Other



Cas N°1. Diagnostic?



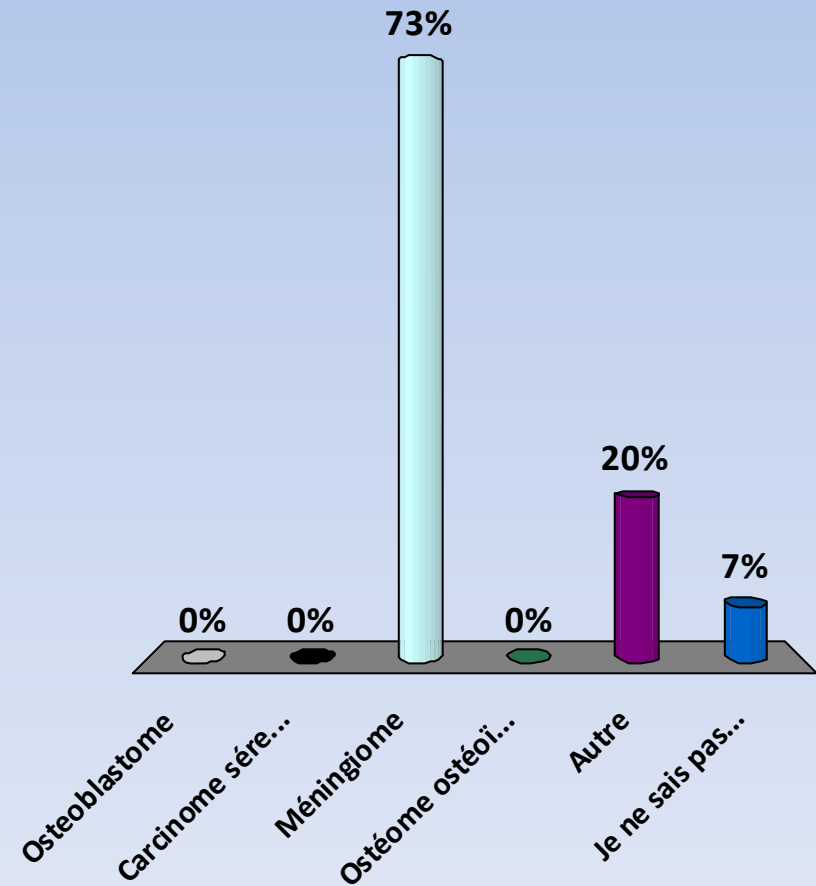
Cas N°1. Diagnostic?



Case N°2

Cas N°2 Diagnostic?

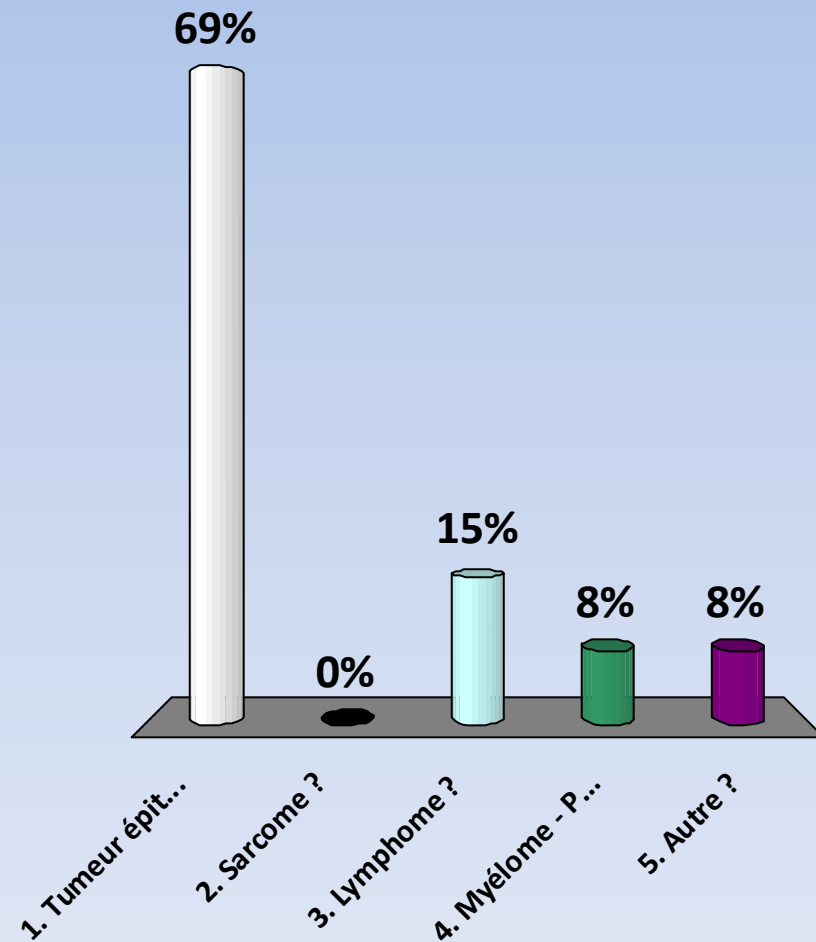
1. Osteoblastome
2. Carcinome séreux métastatique
3. Méningiome
4. Ostéome ostéoïde
5. Autre
6. Je ne sais pas...



Case N°3

Cas N°3 Diagnostic?

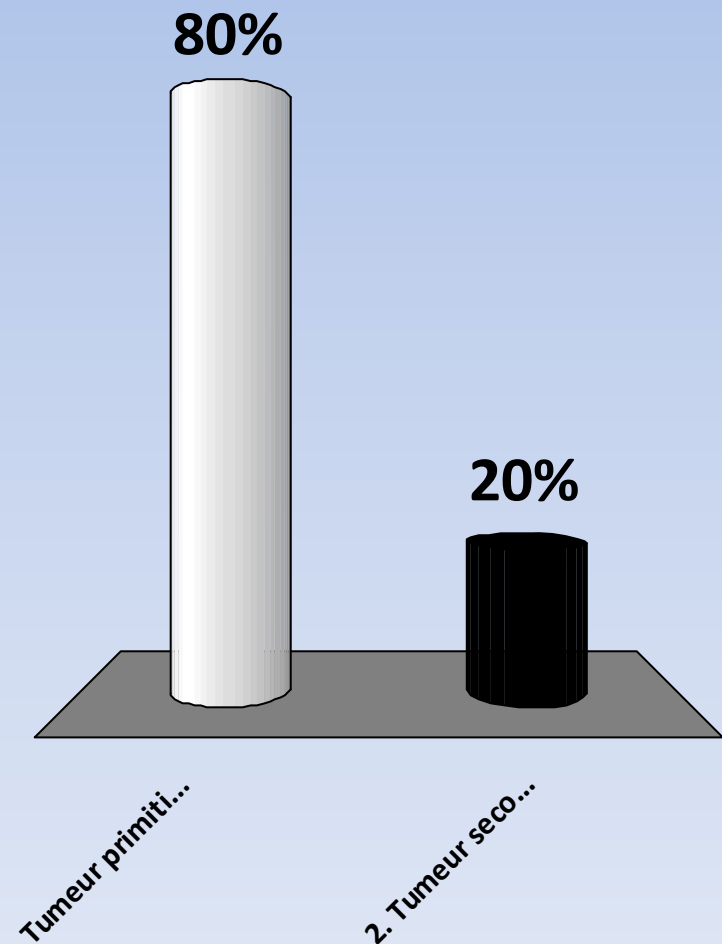
- 1. Tumeur épithéliale ?
- 2. Sarcome ?
- 3. Lymphome ?
- 4. Myélome - Plasmocytome ?
- 5. Autre ?



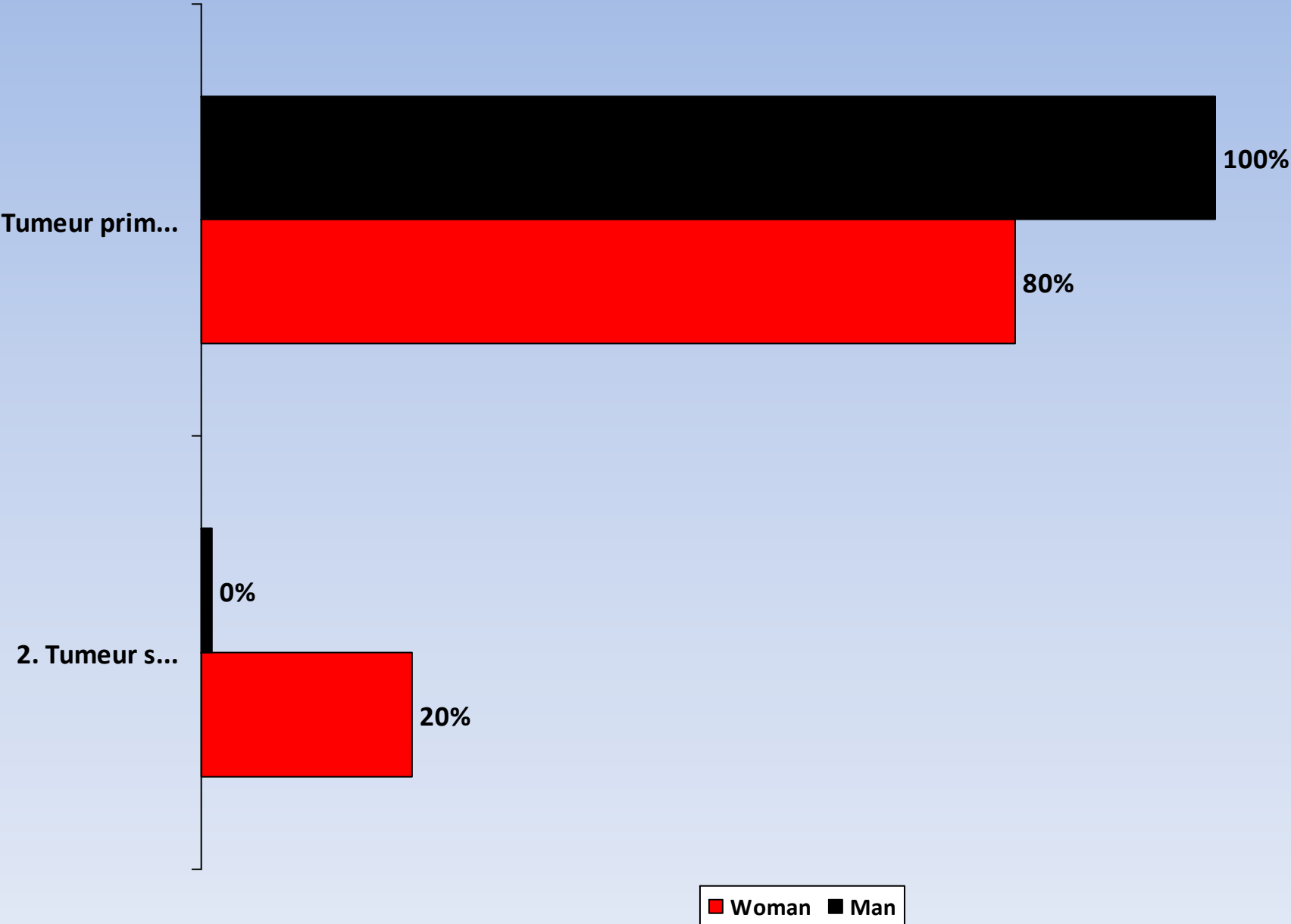
Immuno-histochimie ?

Cas N°3 Diagnostic b?

- Tumeur primitive de vessie ?
- 2. Tumeur secondaire ?



Cas N°3 Diagnostic b?



Conclusion

- Adénocarcinome vésical primitif à cellules en bague à chaton de type « **linite plastique** »

Commentaire (1)

- Linite plastique vésicale primitive
 - est une entité rare et agressive
 - elle fait partie des 0,5 à 2 % des adénocarcinomes primitifs de vessie :
 - Adénocarcinome Lieberkünüen
 - Adénocarcinome à cellules claires ou C. mésonéphrique
 - Adénocarcinome en bague à chaton (linite) : 1^{er} cas décrit en 1955 par Saphir

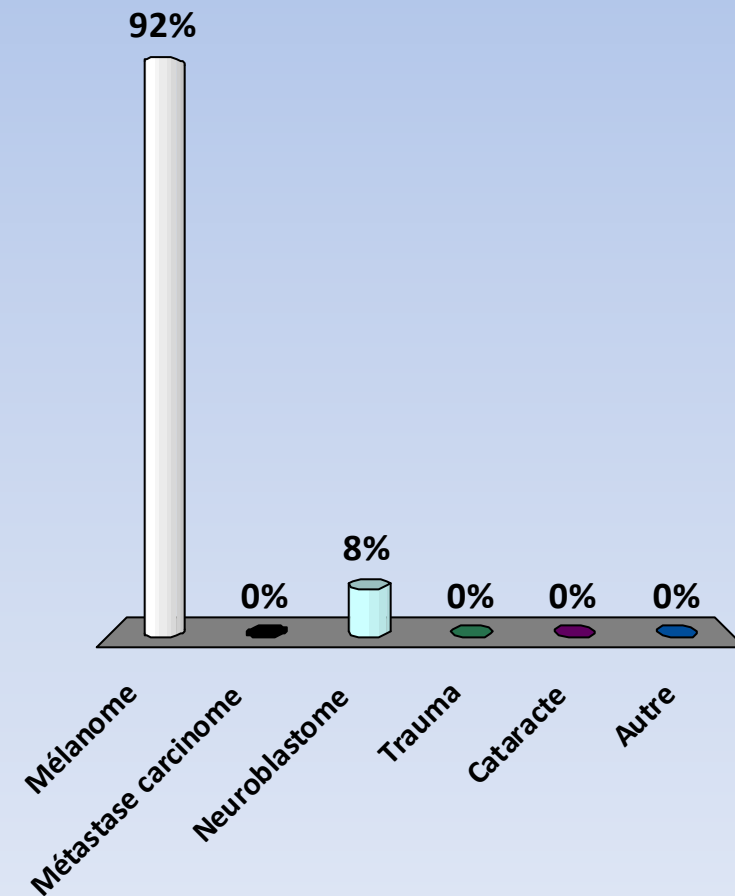
Commentaire (2)

- Moins fréquente que les métastases de vessie d'origine :
 - Digestive
 - Prostatique
 - utérine
 - mammaire
- Infiltration diffuse de toute la vessie
- Traitement : chirurgie, Chimio ?
- Pronostic : mauvais

Case N°4

Cas N°4

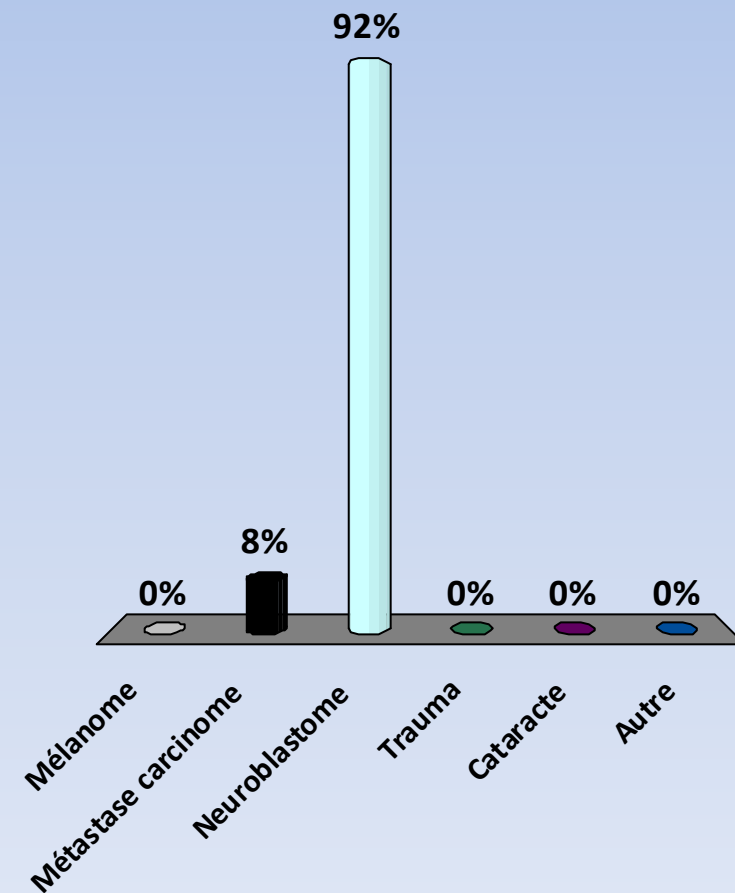
1. Mélanome
2. Métastase carcinome
3. Neuroblastome
4. Trauma
5. Cataracte
6. Autre



Case N°5

Cas N°5

1. Mélanome
2. Métastase carcinome
3. Neuroblastome
4. Trauma
5. Cataracte
6. Autre





<http://thomasconte.net/tango/>
23rd August 2014, Brussels Park (Kiosque)

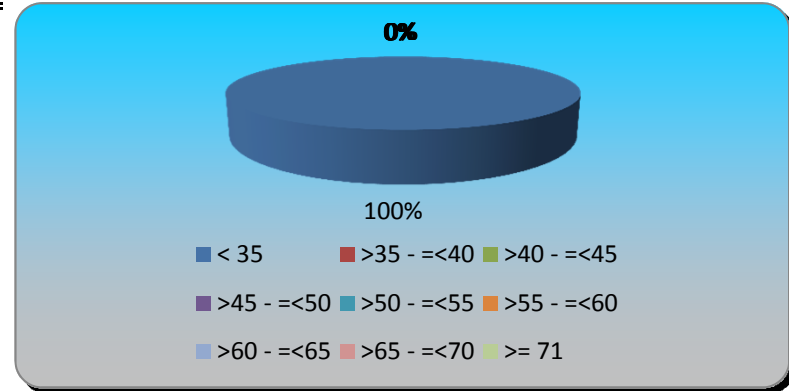
Turning Graphical Results by Question

Session Name: New Session 05-09-2014 22-16

Created: 06/09/2014 18:10

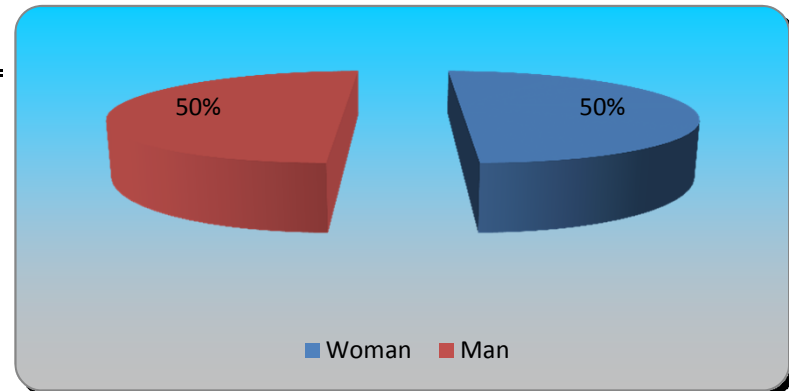
1.) Age? (multiple choice)

	Responses	
< 35	2	100%
>35 - =<40	0	0%
>40 - =<45	0	0%
>45 - =<50	0	0%
>50 - =<55	0	0%
>55 - =<60	0	0%
>60 - =<65	0	0%
>65 - =<70	0	0%
>= 71	0	0%
Totals	2	100%



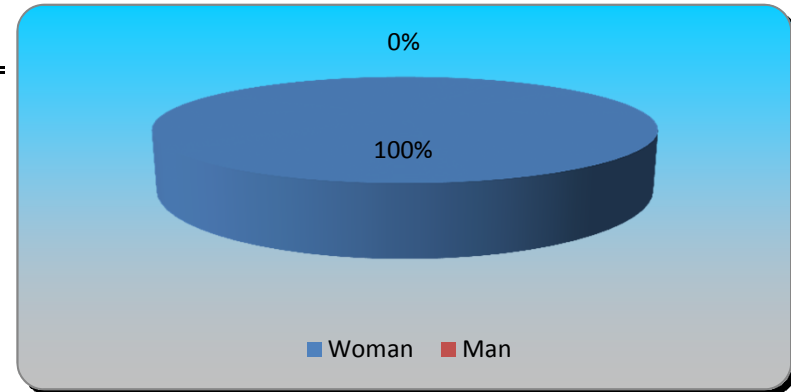
2.) Zapettes test slide. Woman=1 Man=2 (multiple choice)

	Responses	
Woman	1	50%
Man	1	50%
Totals	2	100%



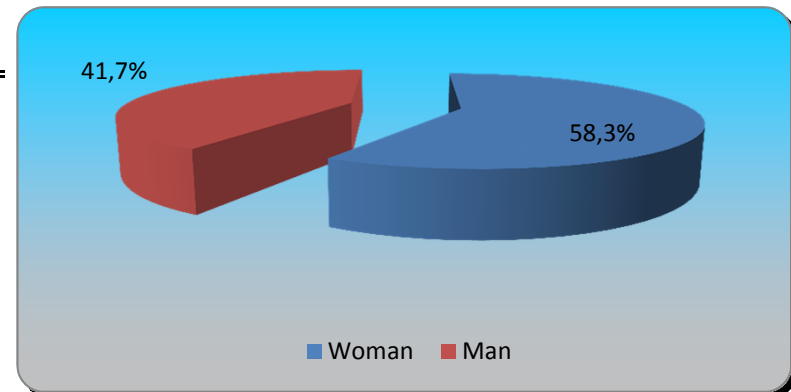
3.) Zapettes test slide. Woman=1 Man=2 (multiple choice)

	Responses	
Woman	2	100%
Man	0	0%
Totals	2	100%



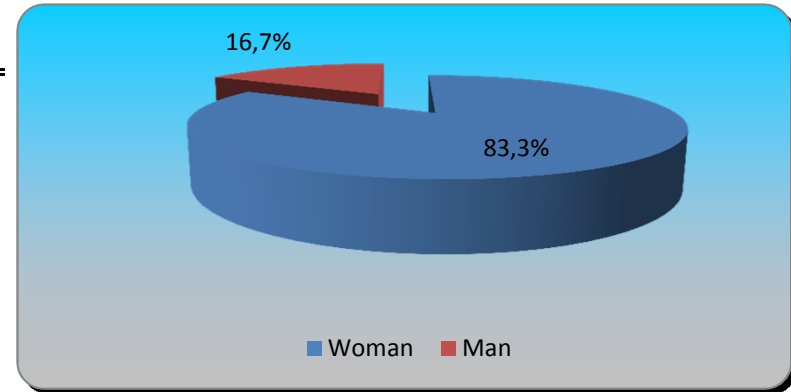
4.) Zapettes test slide. Woman=1 Man=2 (multiple choice)

	Responses	
Woman	7	58,33%
Man	5	41,67%
Totals	12	100%



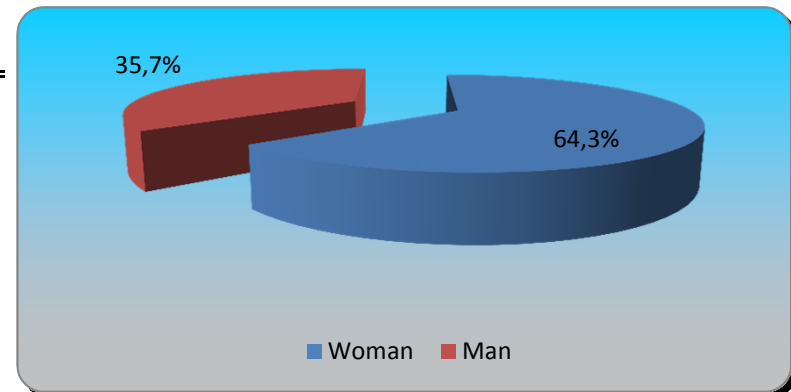
5.) Zapettes test slide. Woman=1 Man=2 (multiple choice)

	Responses	
Woman	5	83,33%
Man	1	16,67%
Totals	6	100%



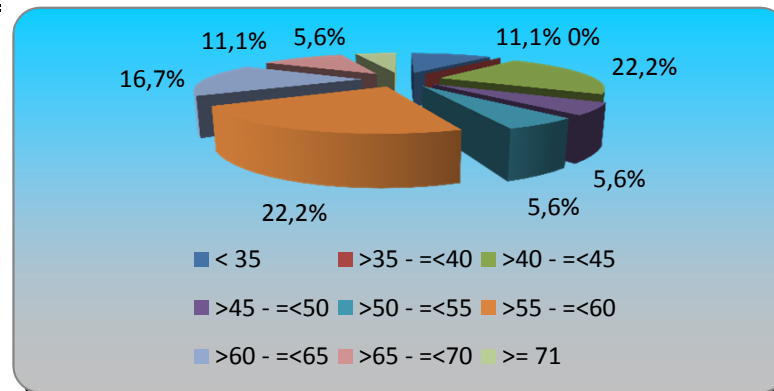
6.) Zapettes test slide. Woman=1 Man=2 (multiple choice)

	Responses	
Woman	9	64,29%
Man	5	35,71%
Totals	14	100%



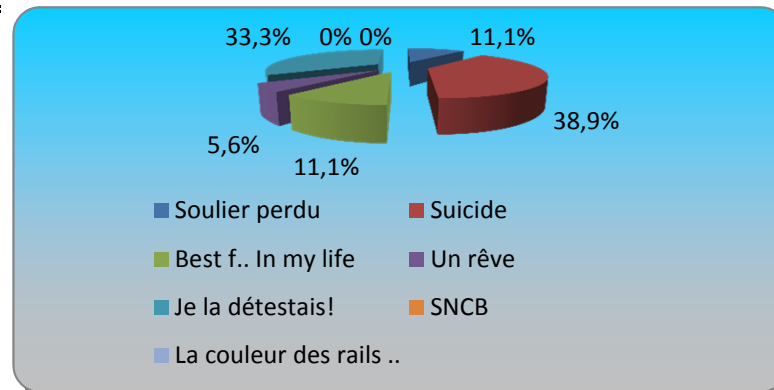
7.) Age? (multiple choice)

	Responses	
< 35	2	11,11%
>35 - =<40	0	0%
>40 - =<45	4	22,22%
>45 - =<50	1	5,56%
>50 - =<55	1	5,56%
>55 - =<60	4	22,22%
>60 - =<65	3	16,67%
>65 - =<70	2	11,11%
>= 71	1	5,56%
Totals	18	100%



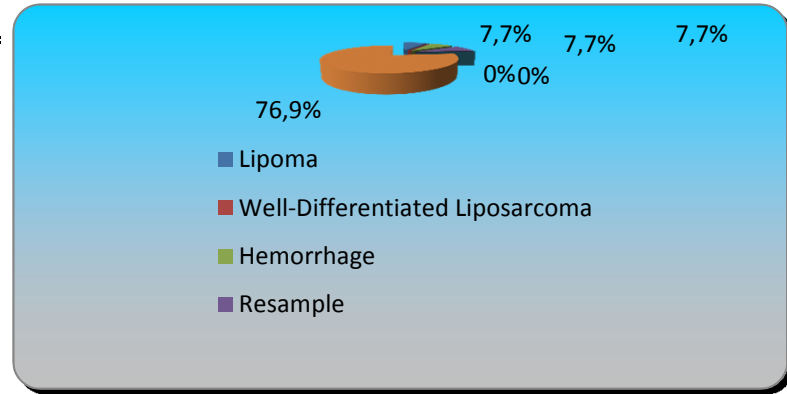
8.) Voyage en train (multiple choice)

	Responses	
Soulier perdu	2	11,11%
Suicide	7	38,89%
Best f.. In my life	2	11,11%
Un rêve	1	5,56%
Je la détestais!	6	33,33%
SNCB	0	0%
La couleur des rails ..	0	0%
Totals	18	100%



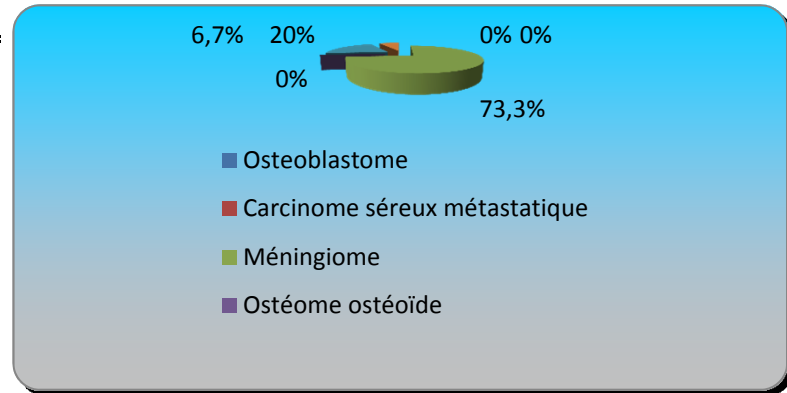
9.) Cas N°1. Diagnostic? (multiple choice)

	Responses	
Lipoma	1	7,69%
Well-Differentiated Liposarcoma	0	0%
Hémorrhage	1	7,69%
Resample	1	7,69%
Expert advice	0	0%
Other	10	76,92%
Totals	13	100%



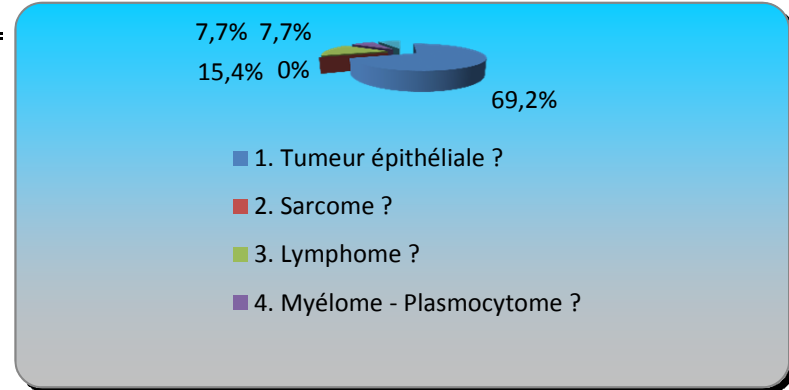
10.) Cas N°2 Diagnostic? (multiple choice)

	Responses	
Osteoblastome	0	0%
Carcinome séreux métastatique	0	0%
Méningiome	11	73,33%
Ostéome ostéoïde	0	0%
Autre	3	20%
Je ne sais pas...	1	6,67%
Totals	15	100%



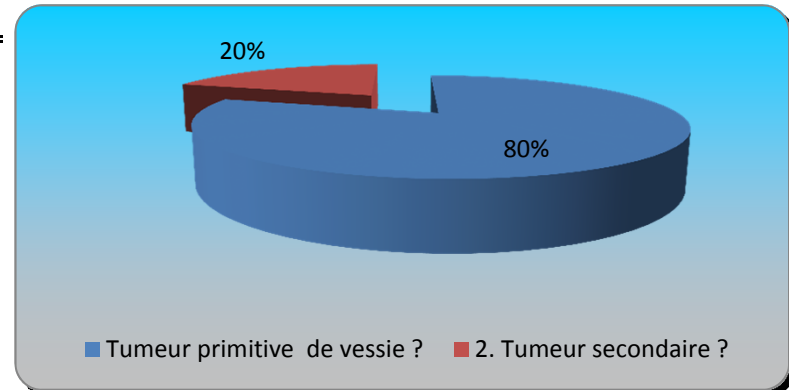
11.) Cas N°3 Diagnostic? (multiple choice)

	Responses	
1. Tumeur épithéliale ?	9	69,23%
2. Sarcome ?	0	0%
3. Lymphome ?	2	15,38%
4. Myélome - Plasmocytome ?	1	7,69%
5. Autre ?	1	7,69%
Totals	13	100%



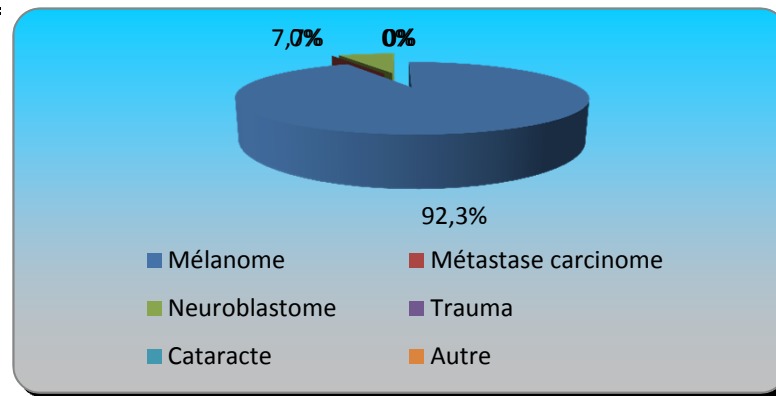
12.) Cas N°3 Diagnostic b? (multiple choice)

	Responses	
Tumeur primitive de vessie ?	8	80%
2. Tumeur secondaire ?	2	20%
Totals	10	100%



13.) Cas N°4 (multiple choice)

	Responses	
Mélanome	12	92,31%
Métastase carcinome	0	0%
Neuroblastome	1	7,69%
Trauma	0	0%
Cataracte	0	0%
Autre	0	0%
Totals	13	100%



14.) Cas N°5 (multiple choice)

	Responses	
Mélanome	0	0%
Métastase carcinome	1	8,33%
Neuroblastome	11	91,67%
Trauma	0	0%
Cataracte	0	0%
Autre	0	0%
Totals	12	100%

