PLACENTA PATHOLOGIE

Marcella Baldewijns – Cecile Colpaert
Brussel 10/02/2020

Indicaties voor placenta onderzoek

Drucilla J Roberts, www.uptodate.com

- **all placentas should have a minimal examination including color, length of umbilical cord, number of cord vessels, and weight of the placental disk.**
- following clinical scenarios require a full pathologic examination of the placenta:
  - Stillbirth (current or history of previous stillbirth)
  - Neonatal resuscitation or neonatal intensive care unit (NICU) admission
  - Preterm or postterm delivery
  - Multiple gestation
  - Obstetric complications/disorders (e.g. chorioamnionitis, preeclampsia, cholestasis, fetal intolerance of labor, antepartum or postpartum hemorrhage, thick meconium, severe oligohydramnios/polyhydramnios)

Indications for placental examination

- Any Apgar score <7
- Fetal/neonatal anomalies or hydrops
- Small for gestational age/large for gestational age

- Abnormal gross examination of the placenta (e.g. abnormal color, masses, long or short umbilical cord, abnormal membranes)

- Relevant maternal diseases/disorders (e.g. diabetes, obesity, hypertension, tobacco/alcohol/illegal drug use, thyroid disease, malignant neoplasm, fever/infection, uterine anomalies or scars)

Placental Pathology, a Survival Guide

Drucilla J. Roberts, MD

Arch Pathol Lab Med 2008

Table 1. Indications for Placental Examination

Pediatric
Prematurity/postdates
Growth indices: intrauterine growth restriction/macrosomia
Unexpected adverse outcome
Congenital anomalies
Suspicion of fetal infection
Fetal hydrops
Fetal hematologic abnormalities
Obstetric
Stillbirth (important site to obtain tissue for culture for karyotype)
Poor obstetric history
Maternal disease/death
Hypertension
Maternal infection
Oligo/polyhydramnios
Excessive bleeding per vagina
Abnormal fetal monitoring
In utero therapy
Maternal toxin exposure
Abnormal placenta noted at delivery

Placenta

Request form:

- underlying maternal conditions (e.g. Diabetes Mellitus or known thrombophilias (e.g., Factor V Leiden)), - - -
- gestational age
- birth weight
- mode of delivery
- Apgar scores and complications

Sampling and Definitions of Placental Lesions

Amsterdam Placental Workshop Group Consensus Statement

(*Arch Pathol Lab Med.* 2016;140:698–713; doi: 10.5858/arpa.2015-0225-CC)

Recommendations:

- **Gross description** of the placenta
- **Sampling** of the placenta
- **Definition of pathologic terminologies** and **diagnostic criteria** especially in areas of controversy or uncertainty:
  - Maternal vascular malperfusion
  - Fetal vascular malperfusion
  - Delayed villous maturation
  - Staging and grading of maternal and fetal inflammatory response
  - Villitis of unknown etiology

Gross description and sampling: macroscopie

- Vliezen
- Navelstreng
- Placentaschijf:
  - Gewicht zonder navelstreng en vliezen (vers < gefixeerd (+3-6%))
  - Afmetingen: lengte x breedte x (min. en) max. dikte
  - Foetale zijde
  - Maternele zijde
  - Afwijkingen bij lamellatie van het parenchym

Placenta macroscopie

- *Placenta totaal gewicht: ……gr percentiel: …*
- *Placentavorm: …*
- *Afmetingen (l x b x min-max. dikte): …… x …… cm met dikte …… tot …… cm*
- ***Vliezen***
  - *Insertie: Normaal / Circumvallata ……%/ Circummarginata ……%/ niet vast te stellen*
  - *Kleur : normaal / bruin / groen andere: …*

Placenta circummarginata / placenta circumvallata

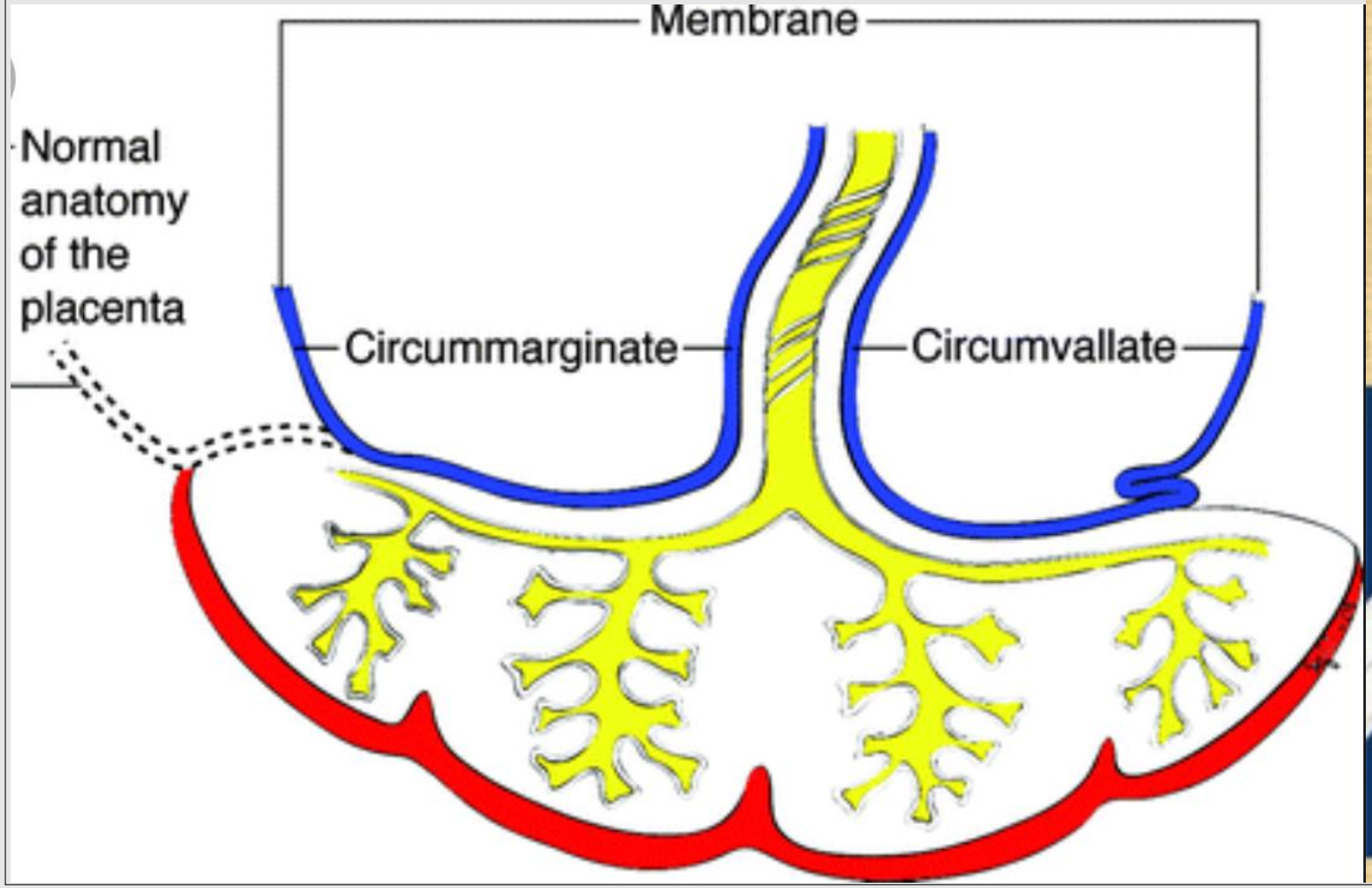

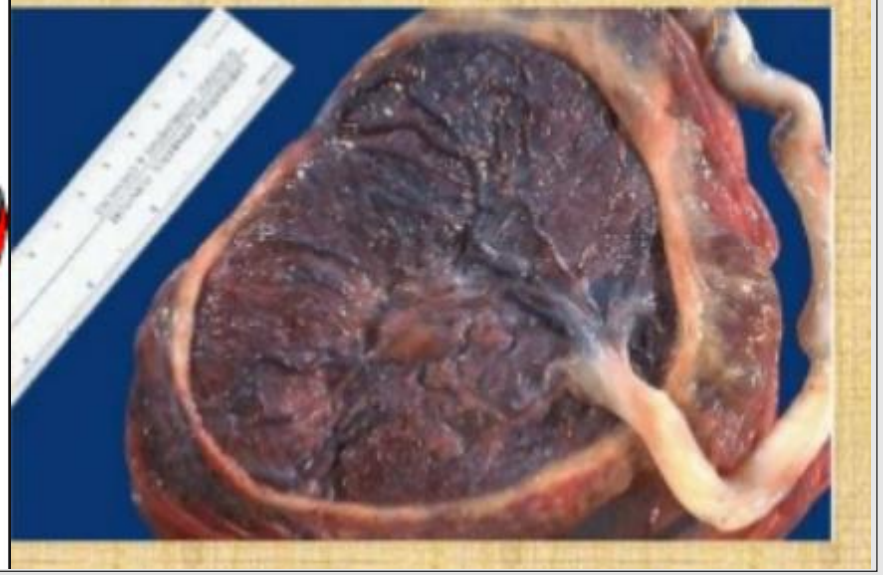

Placenta macroscopie

Navelstreng:

Insertieplaats: … centraal/paracentraal/paramarginaal/marginaal (< 1 cm)/velamenteus

Totale lengte: …

Diameter: …

Totaal aantal windingen: …

Coiling index: … *(hypocoiling: <1/10 cm; hypercoiling: >3/10 cm)*

Aantal bloedvaten: …

Kleur: normaal / andere

Echte knopen: geen / ja zonder congestie/ ja met congestie

Hyper-/hypocoiling twist

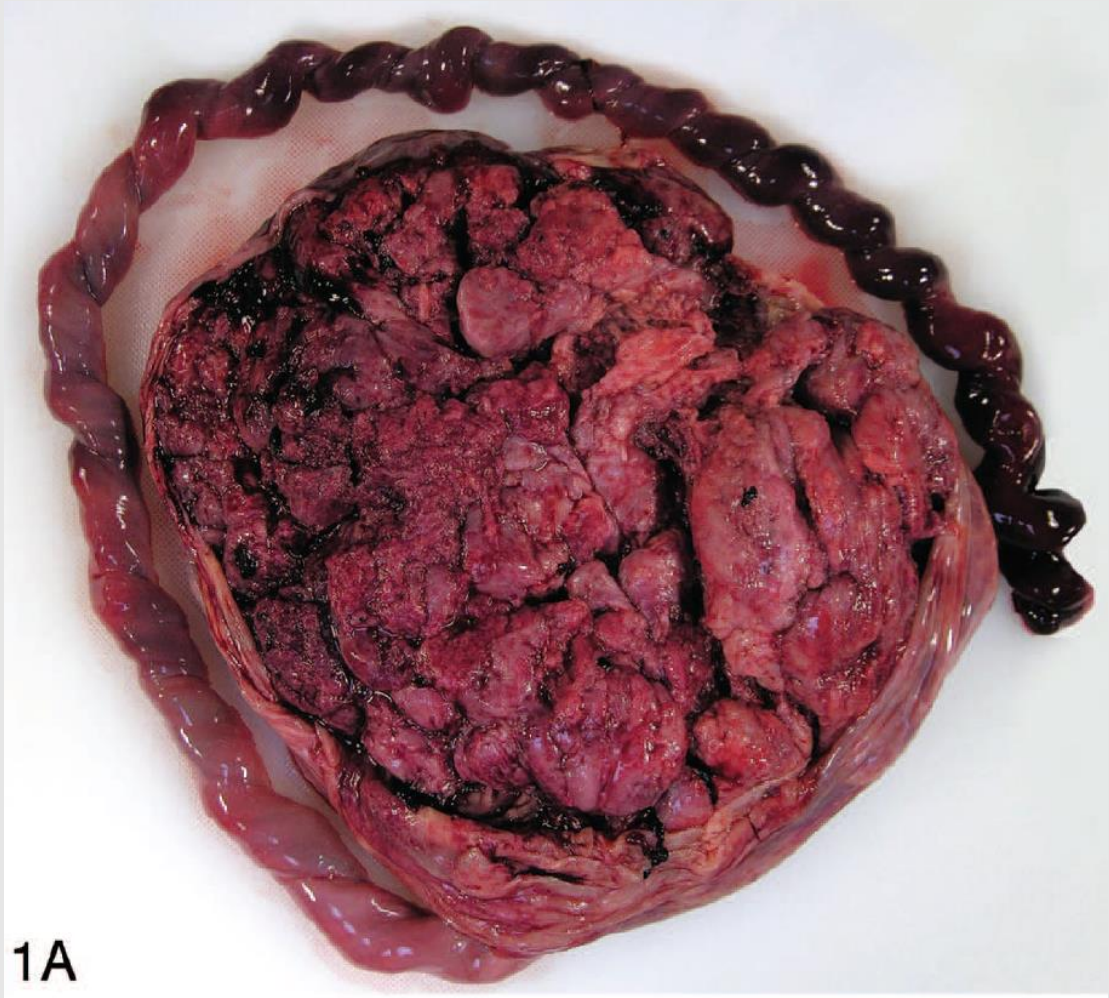

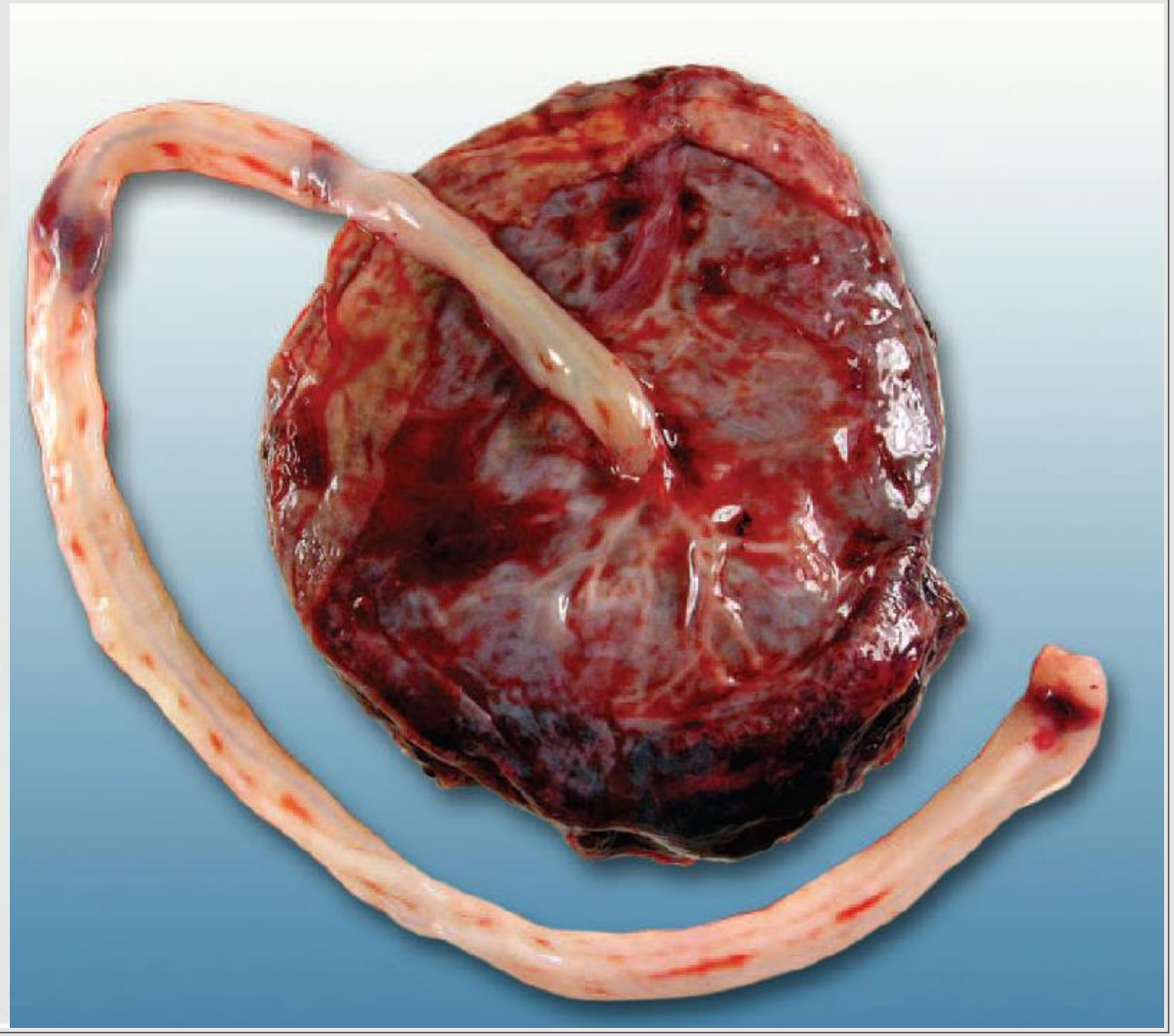

Placenta macroscopie

Foetale zijde/choriale plaat:

normaal / amnion nodosum / andere

abnormale kleur : … groen / bruin

abnormale choriale vaten: … eventueel trombose /……

Maternale zijde:

Normaal gave cotyledonen / gescheurde cotyledonen / andere

Retroplacentaire bloeding (perifeer): …… (percentage t.o.v. totale placenta)

Retroplacentaire bloeding (centraal): …… (percentage t.o.v. totale placenta)

Indeuking van parenchym door de retroplacentaire bloeding? Ja / nee

Placenta macroscopie

- Aspect parenchym:

Normaal / vlekkerig

Haarden: perifeer / centraal aantal …

Afmetingen: …… x …… cm

Uitval percentage: 0% < 5% 5-10% 10-30% 30-50% >50%

Sampling
min. 4 blokken

- Navelstreng foetaal uiteinde
- Navelstreng materneel uiteinde (5 cm van plaat)
- Vliezenrol(len)
- Minimum 3 transmurale blokken van normaal placentaparenchym
  - 1 nabij navelstrenginsertie
  - 2 random van binnenste 2/3 van placentaschijf
- Bijkomende blokken van laesies

Indien transmurale schijf te dik is voor cassette: steeds deel subchoriaal en deel basaal inleggen.

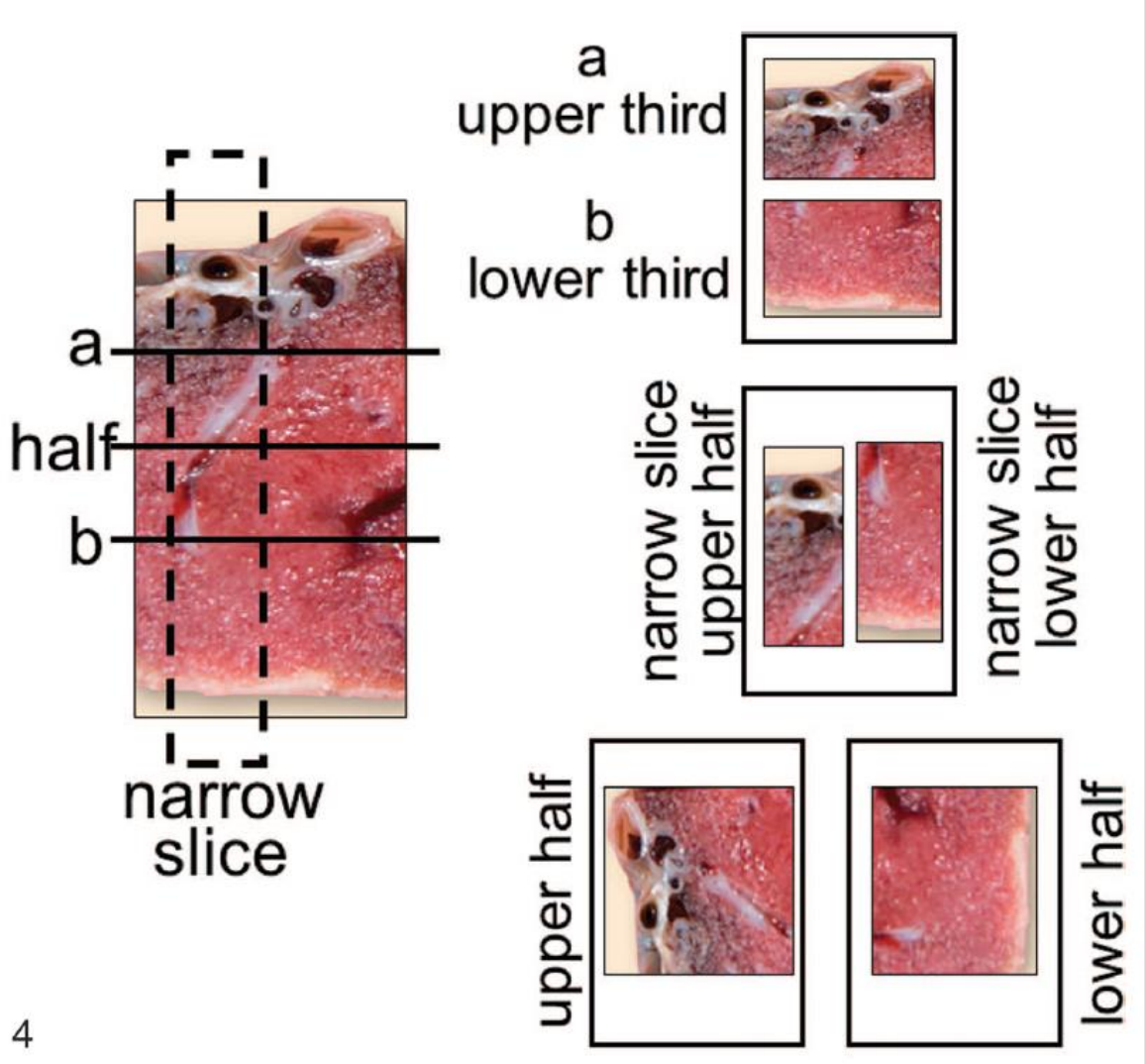

Table 3. Gross Findings and Their Significance
Cord length
Short or flat umbilical cord
Poor fetal activity
Neuromuscular compromise
Oligohydramnios
Associated with limb/body wall complex, gastroschisis
Long or hypertwisted umbilical cord
Increased fetal activity
Polyhydramnios
Heart failure (increased distance to pump)
Increased risk of cord accident
Placental weight
Light placenta (<10th percentile for gestational age)
Chronic uteroplacental insufficiency
Chromosomal anomalies
Maternal tobacco use
Congenital infection
Heavy placenta (>95th percentile for gestational age)
Hydrops placentalis/fetalis
Macrosomia, infant of diabetic mother
Beckwidth-Weidemann syndrome
Triploidy
Discolored placenta
Brown—hemosiderin
Green—meconium
Yellow—chorioamnionitis

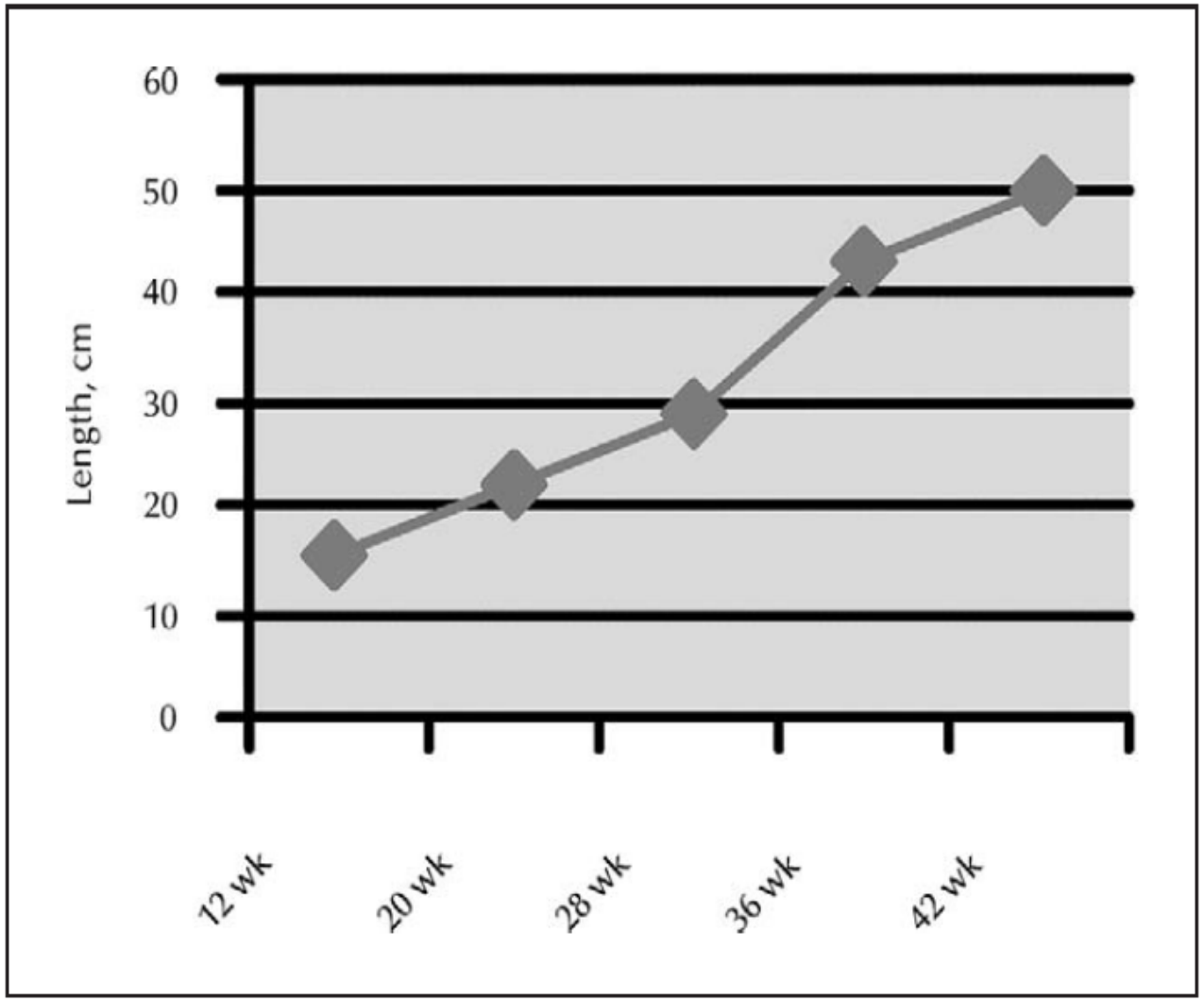

Figure 1. *Umbilical cord length standards. Term cord length 40 to 70 cm (10th–90th percentile).*

Placental histology

- Maternal vascular malperfusion MVM
- Fetal vascular malperfusion FVM
- Delayed villous maturation
- Staging and grading of maternal and fetal inflammatory response
- Villitis of unknown etiology = VUE
- Some cases of specific infectious villitis
- Metabolic disorders detected in the placenta

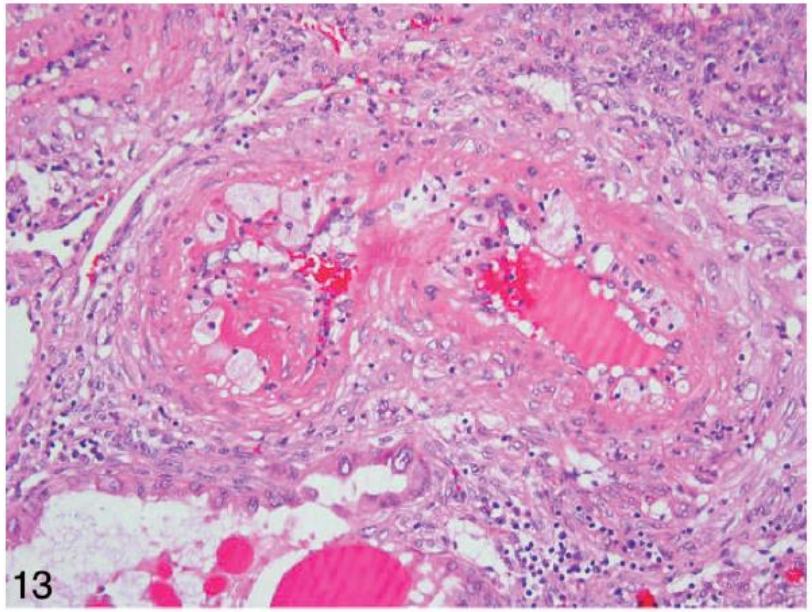

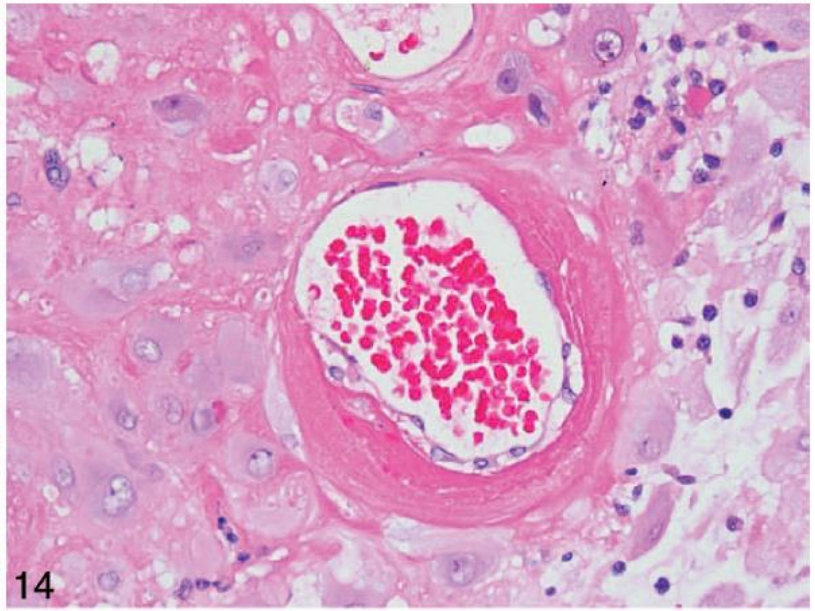

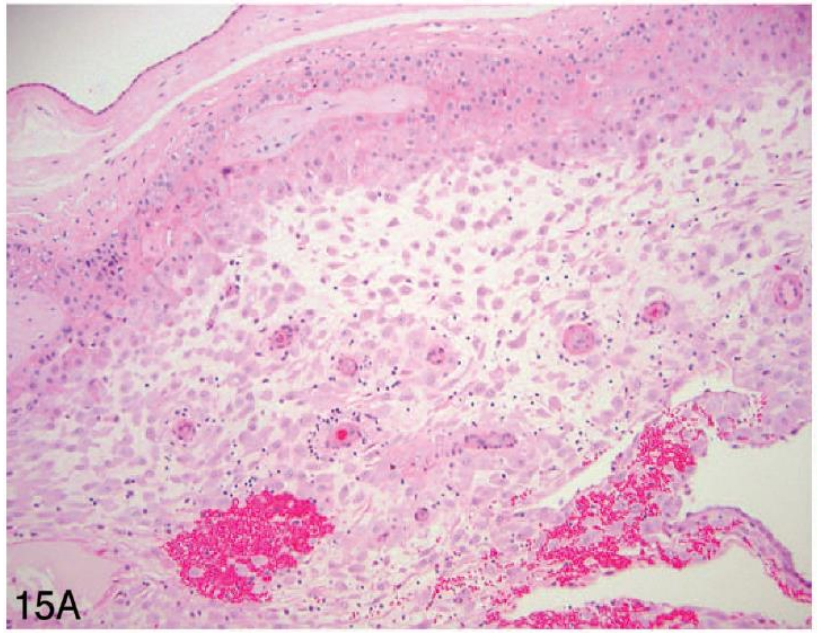

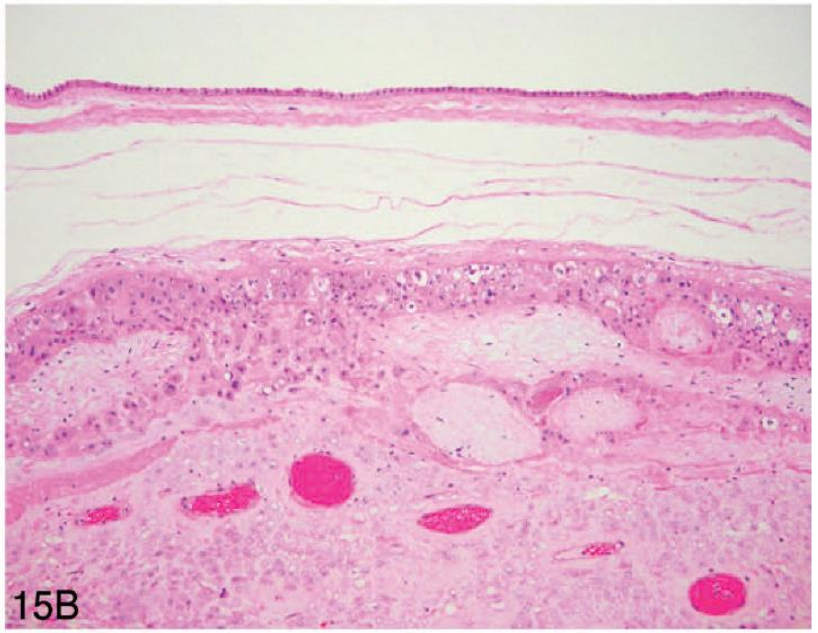

MVM: Deciduale arteriopathie

- Fibrinoide necrose
- Fibrinoide necrose met schuimmacrofagen = “acute atherose”

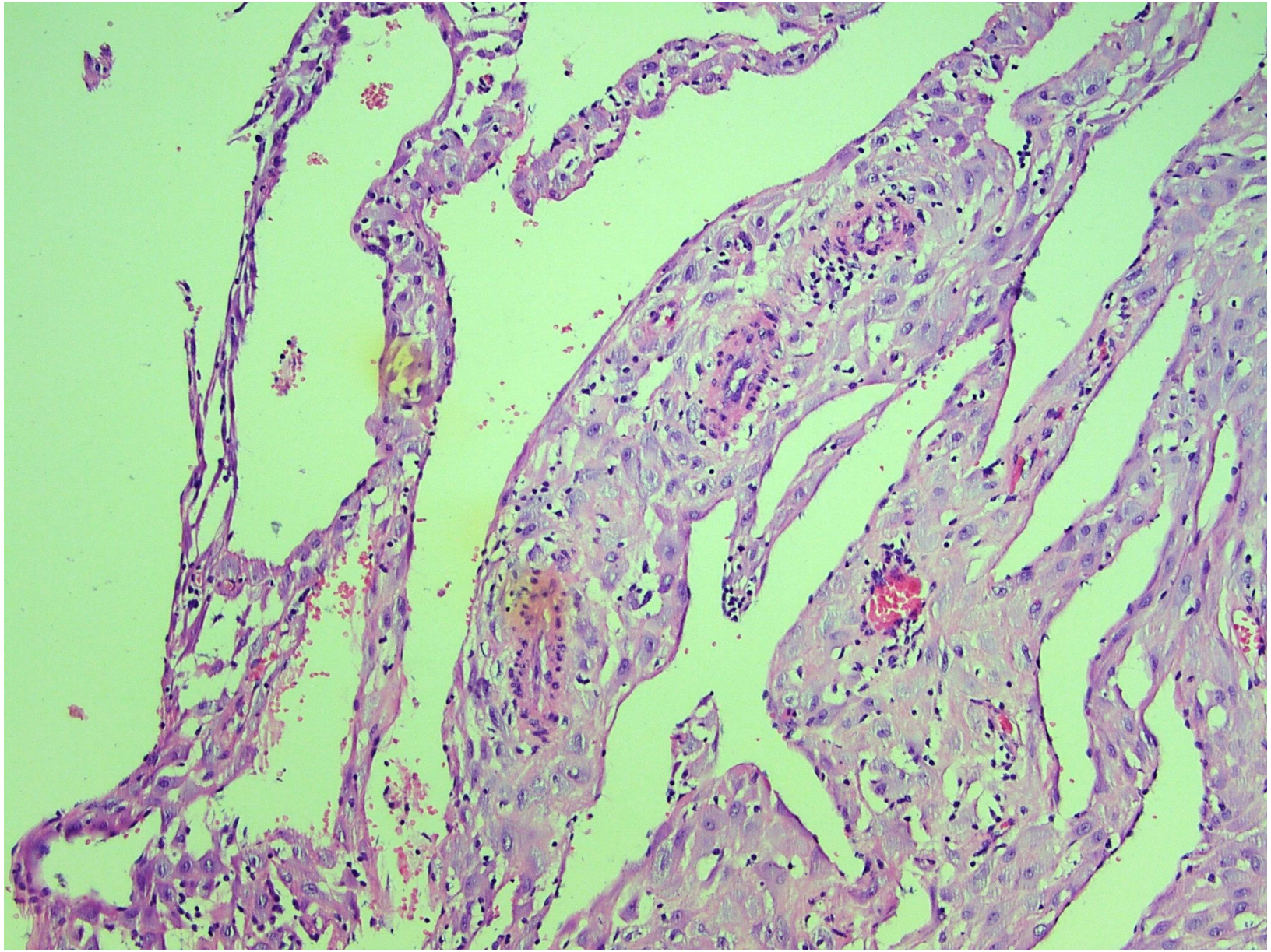

Deciduale arteriopathie

Onvoldoende adaptatie van de gladde spiercellaag van de spiraalarteriolen in de decidua van de vliezen.

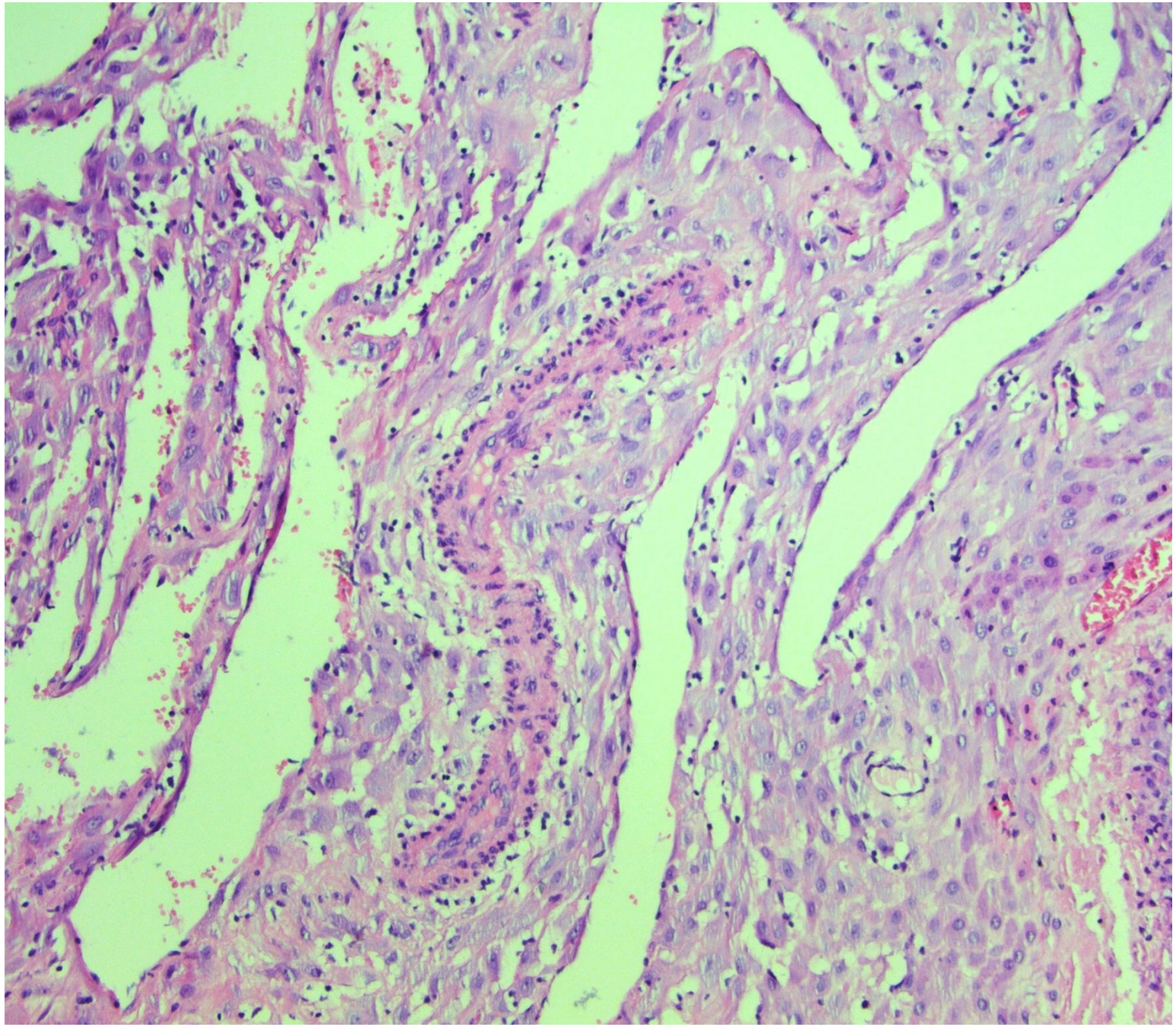

Deciduale arteriopathie

Onvoldoende adaptatie van de gladde spiercellaag van de spiraalarteriolen in de decidua van de vliezen.

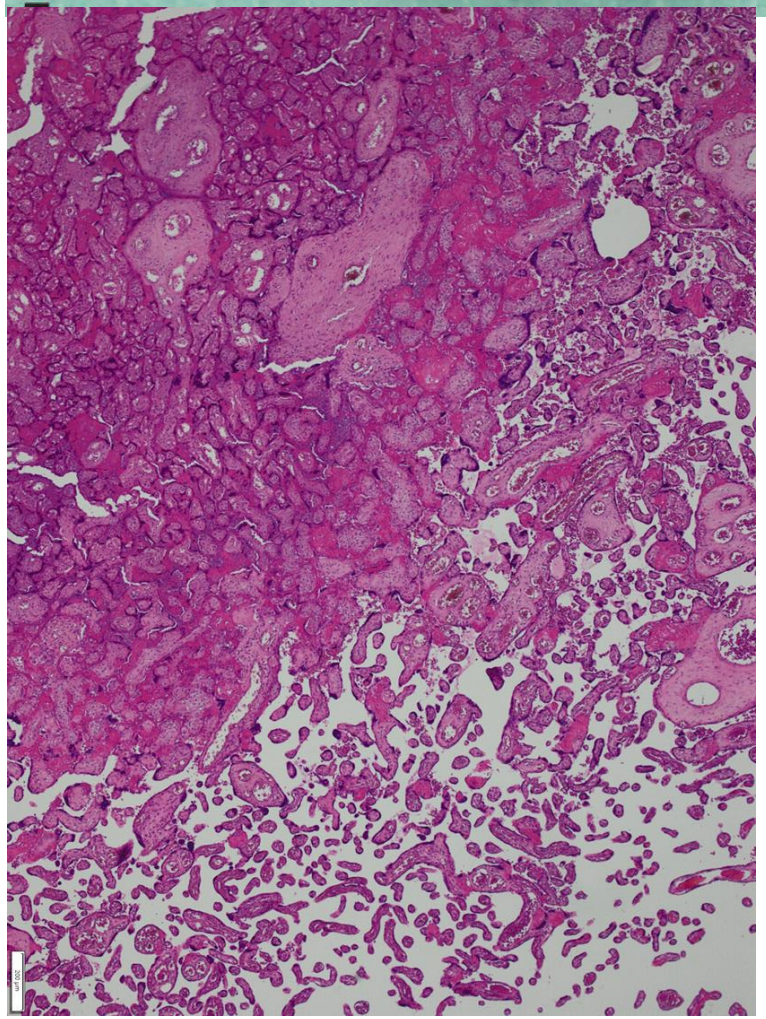

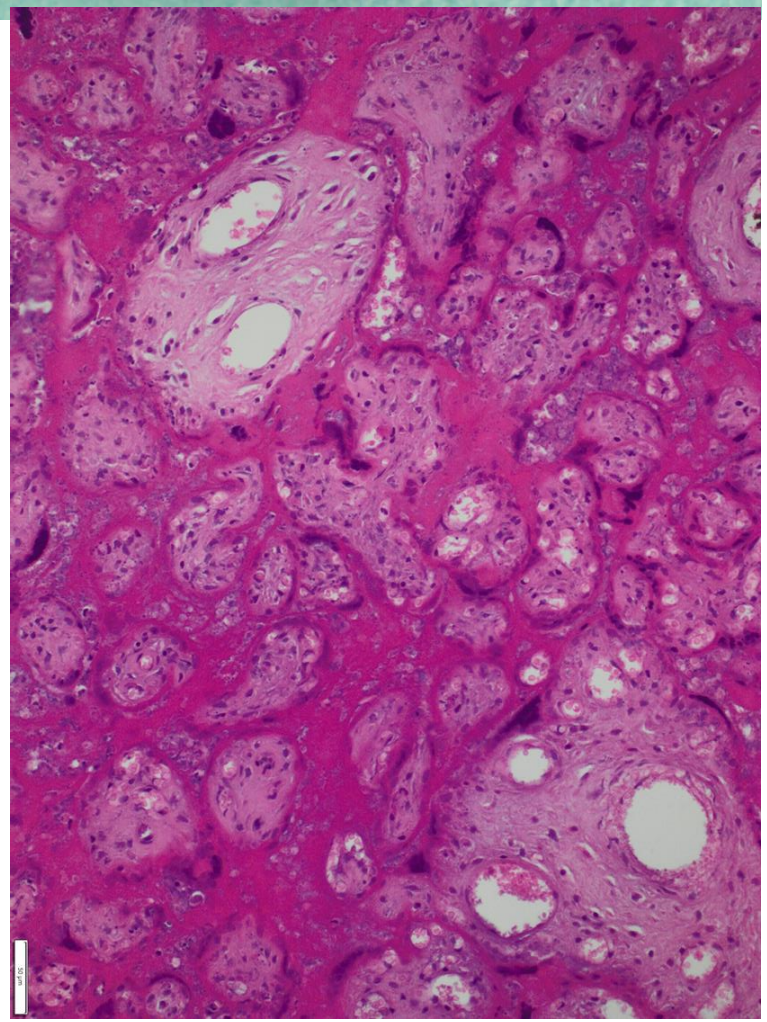

Ischemische infarcten

- Preterm: elk infarct belangrijk / at term: >5% van placenta-volume, niet perifeer infarct
- Oud infarct: geel-beige / recenter infarct: rood
- Infarct met inliggende bloeding: “infarcthematoom”
- Verhoogd risico op retroplacentaire bloeding

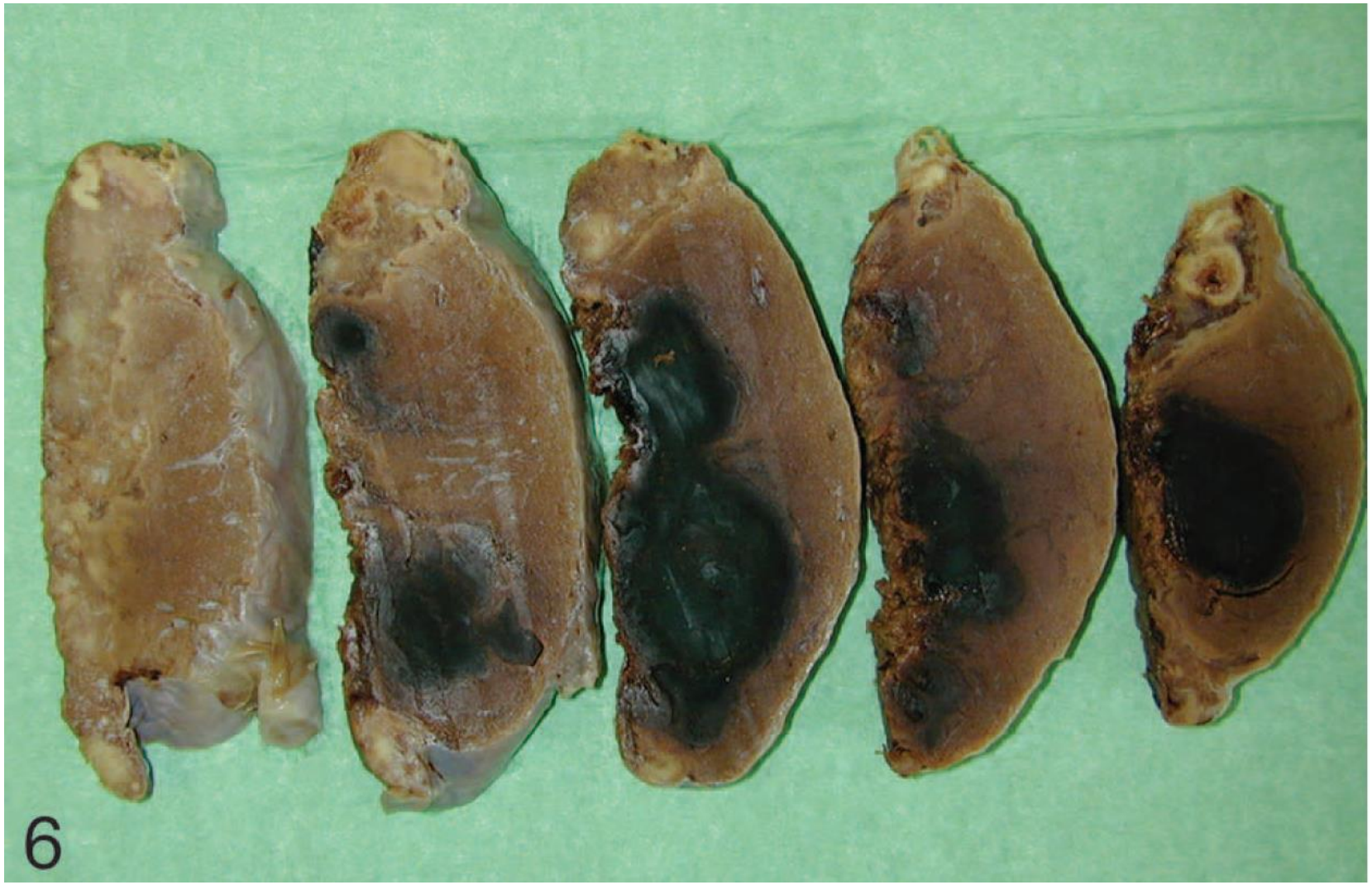

Retroplacentaire bloeding

- Meet 2 dimensies van het retroplacentair hematoom of % maternele oppervlak dat bedekt is.
- Beschrijf eventuele compressie van overliggend placentaweefsel.
- Weeg en meet ook afzonderlijke bloedklonters

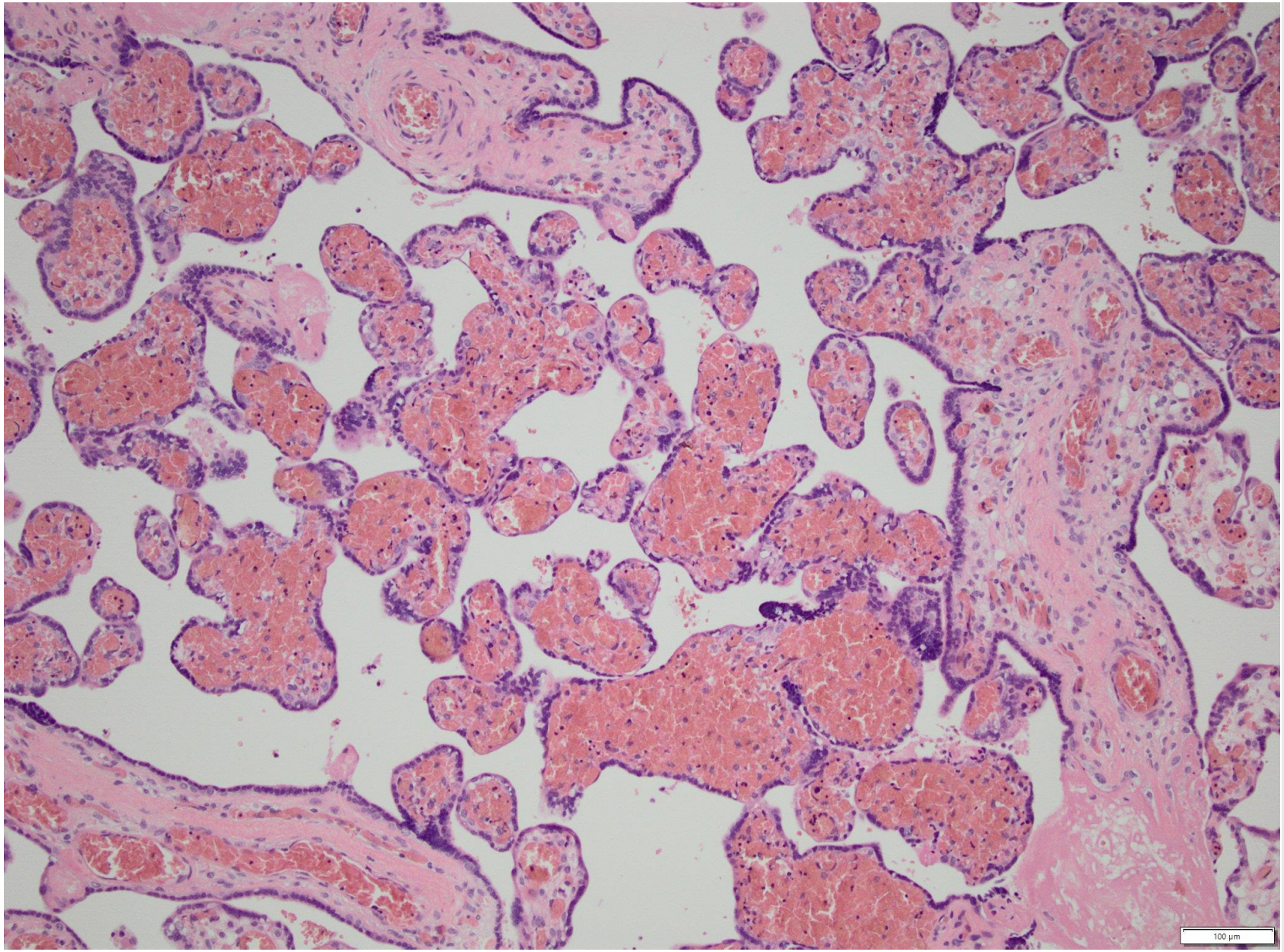

Intravilleuze bloedingen

- Vaak aanwezig in placentaweefsel boven een retroplacentair hematoom
- Ijzermacrofagen in chorion: niet bij acute solutio placentae, pas na 3-6 u aanwezigheid van bloed

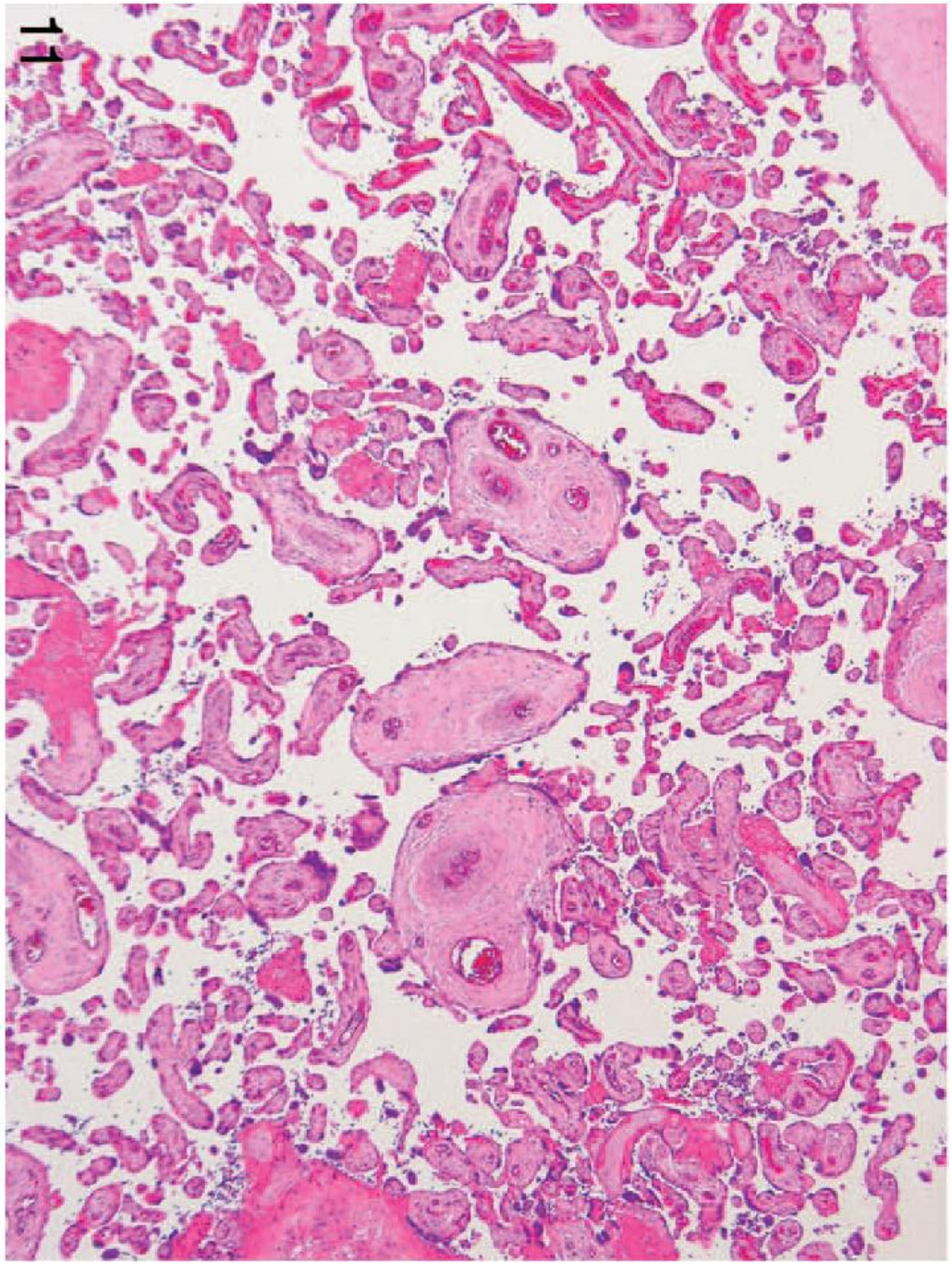

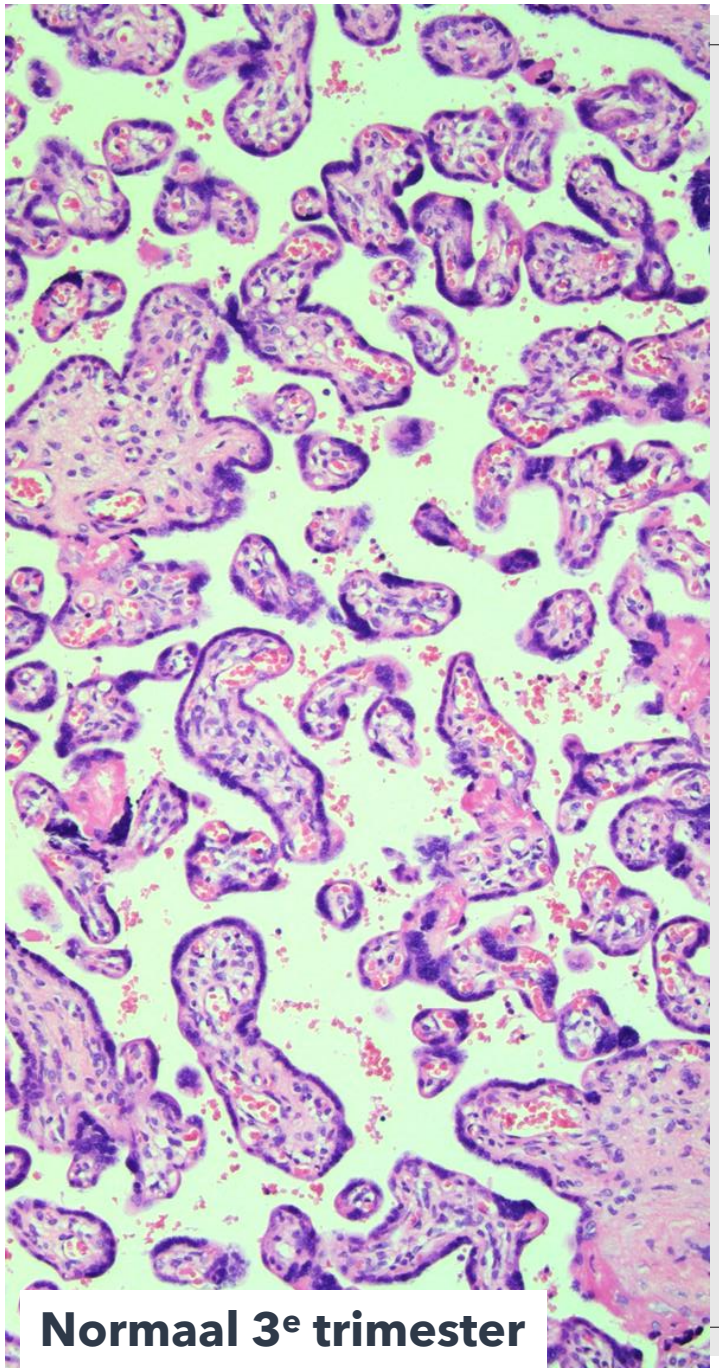

Normaal 3e trimester

Distale villus hypoplasie

- MVM in vroege zwangerschap <32 weken
- Stamvlokken omgeven door verminderd aantal kleine, dunne, langwerpige vlokken. Toegenomen syncytiale knopen.
- Diagnose alleen in basale 2/3 van de placenta en wanneer >30% van minstens 1 coupe aangetast is.

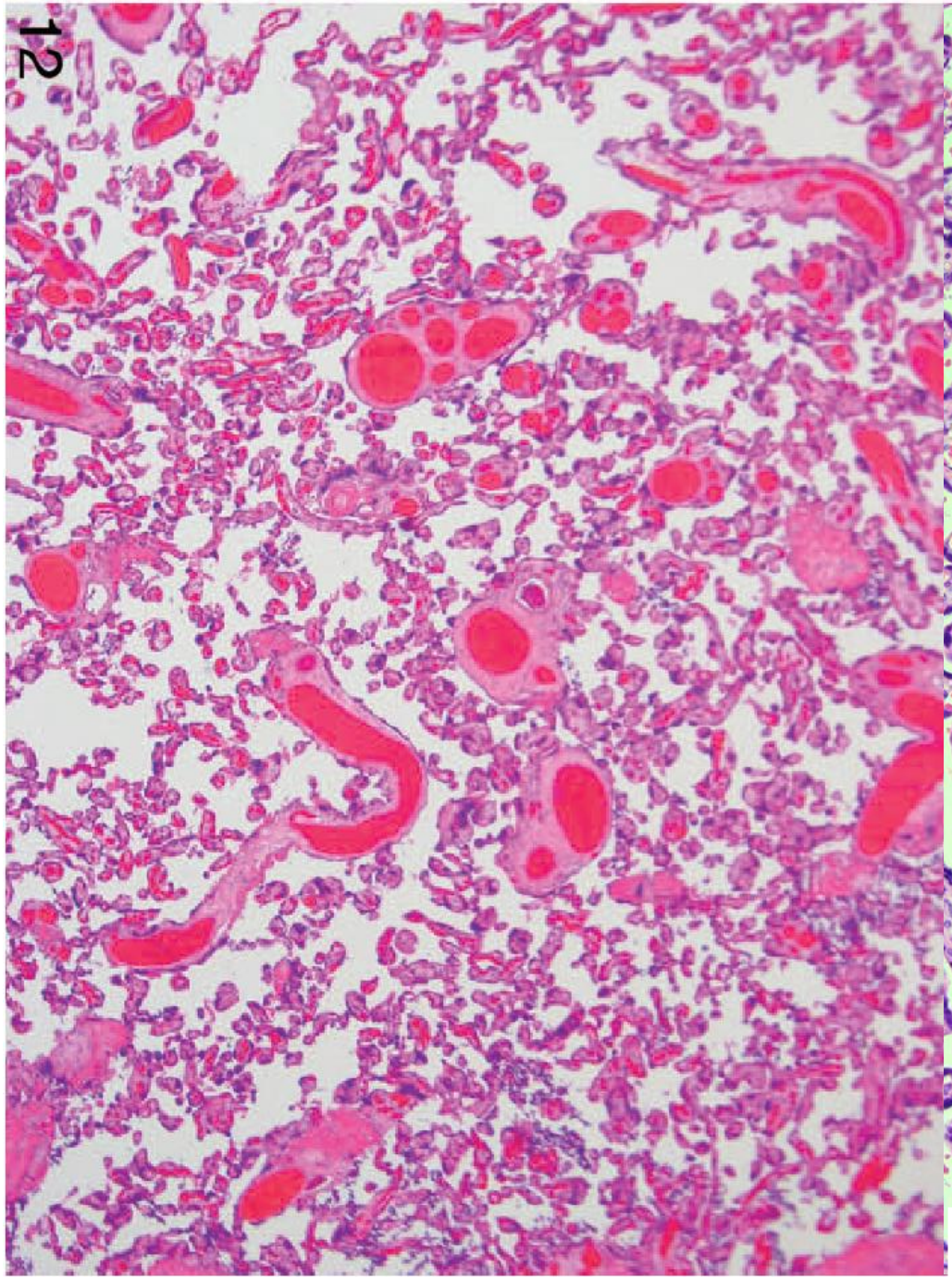

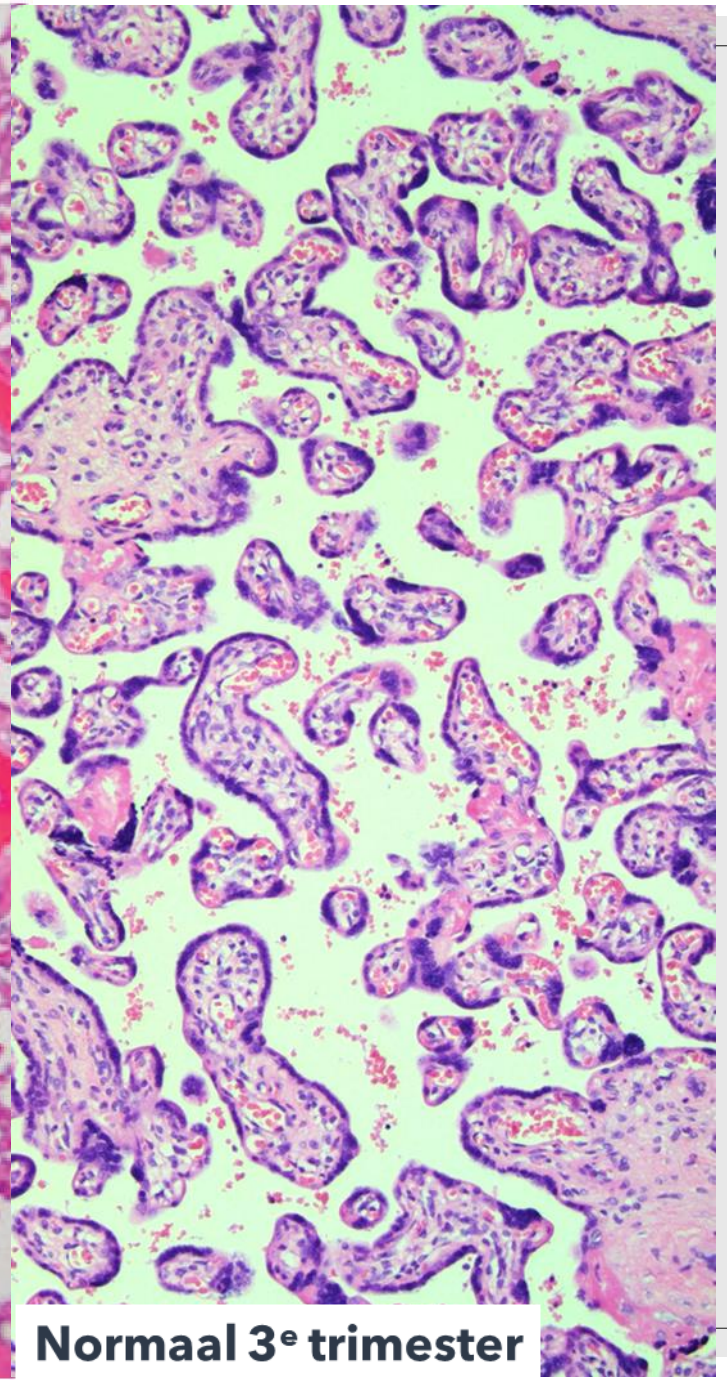

Te ver gevorderde vlokkenmaturatie

- Diagnose alleen mogelijk preterm.
- Zeer talrijke terminale vlokken met toegenomen syncytiale knopen.
- Syncytiale knopen in > 33% van de vlokken = toegenomen.

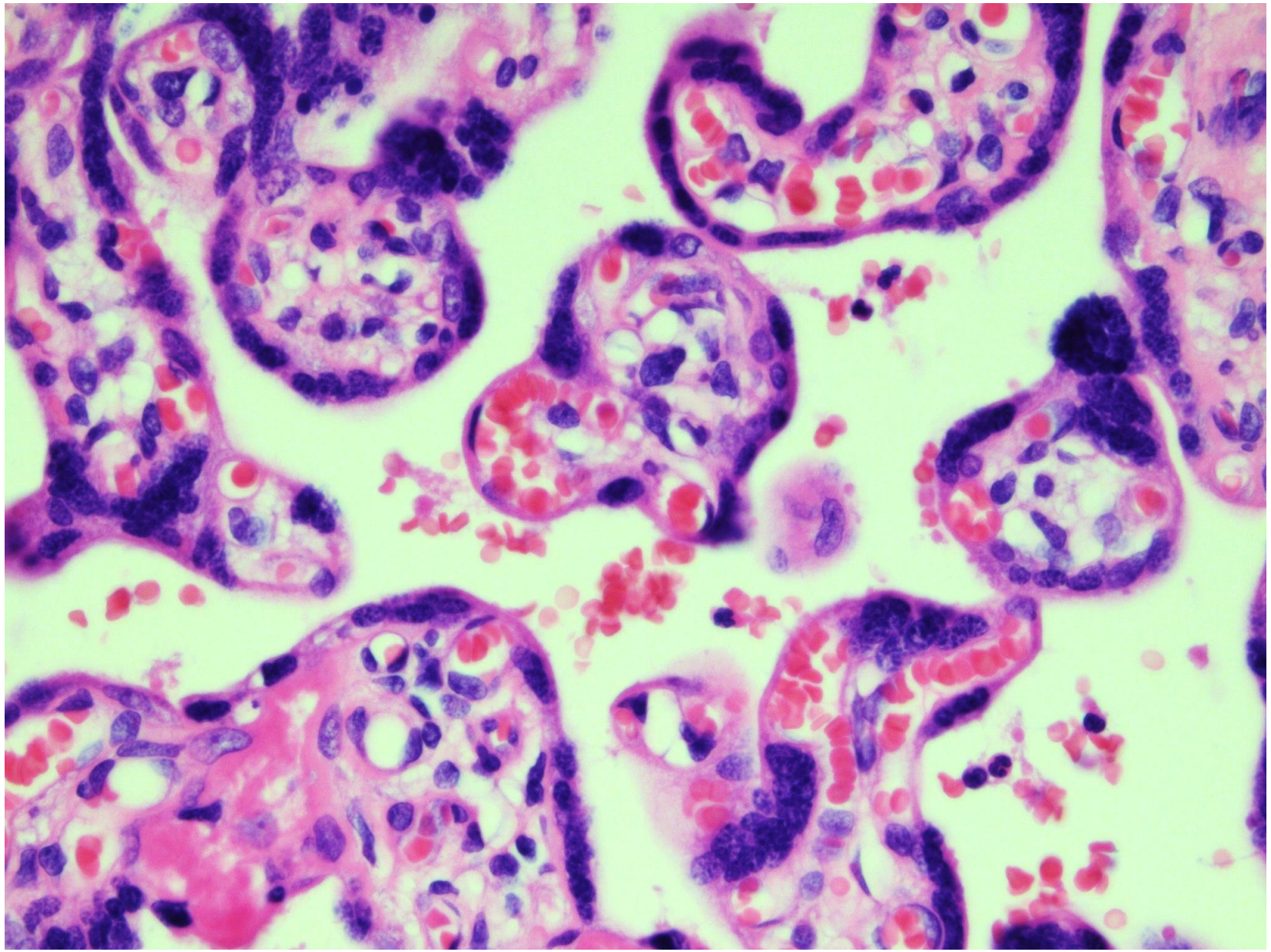

Syncytiale knopen / syncytiocapillaire membranen

Verhoogt diffusie-oppervlakte tussen materneel en foetaal bloed.

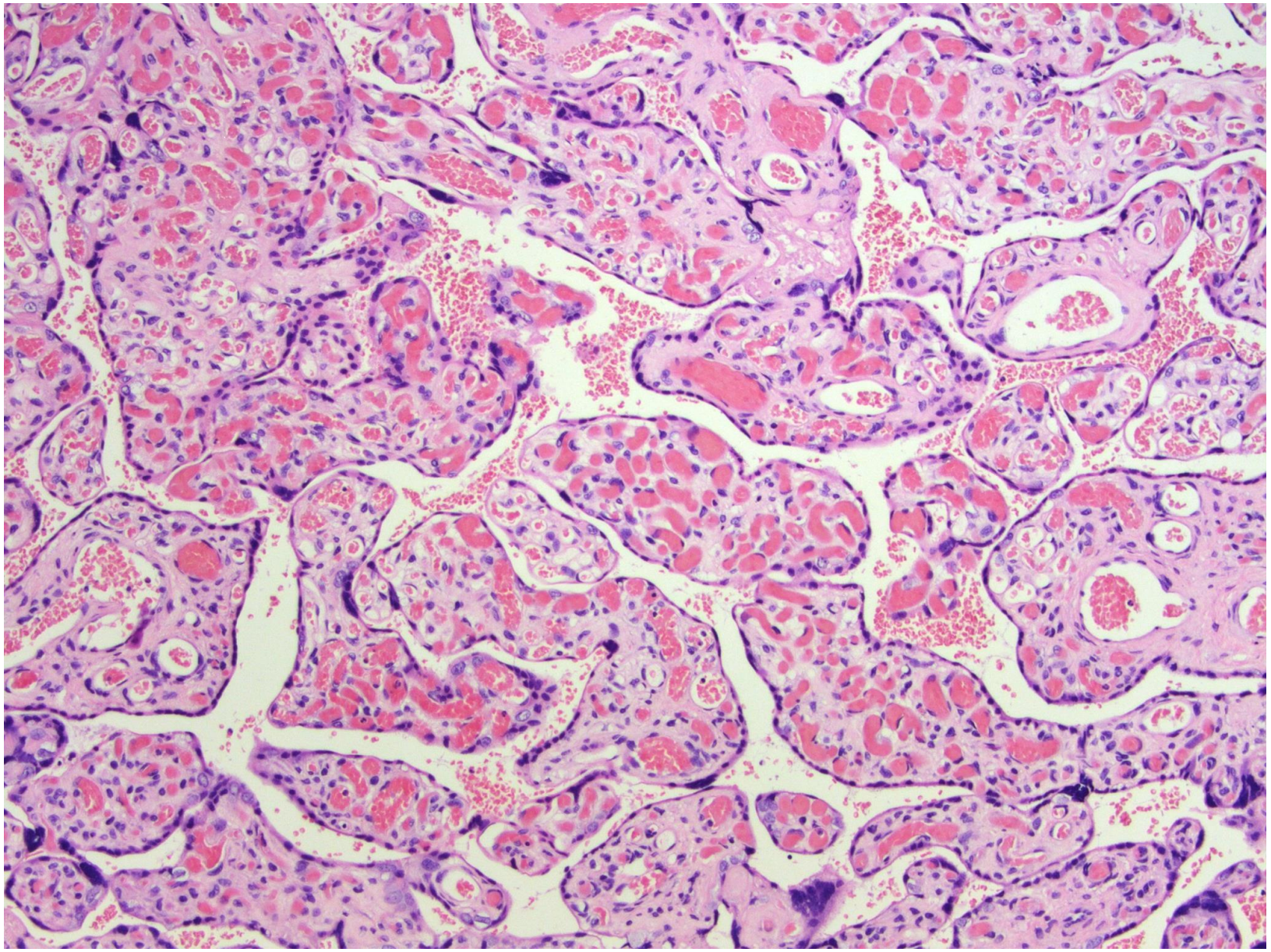

chorangiosis

- > 10 capillaire doorsneden per vlok in > 10 vlokken in > 10 velden
- Inefficiënte reactie van de placenta op zuurstofnood
- Meer gevolg van maternele hypoxemie (cardiopulmonaire aandoening, zwangerschap in hooggebergte, …) dan van MVM.

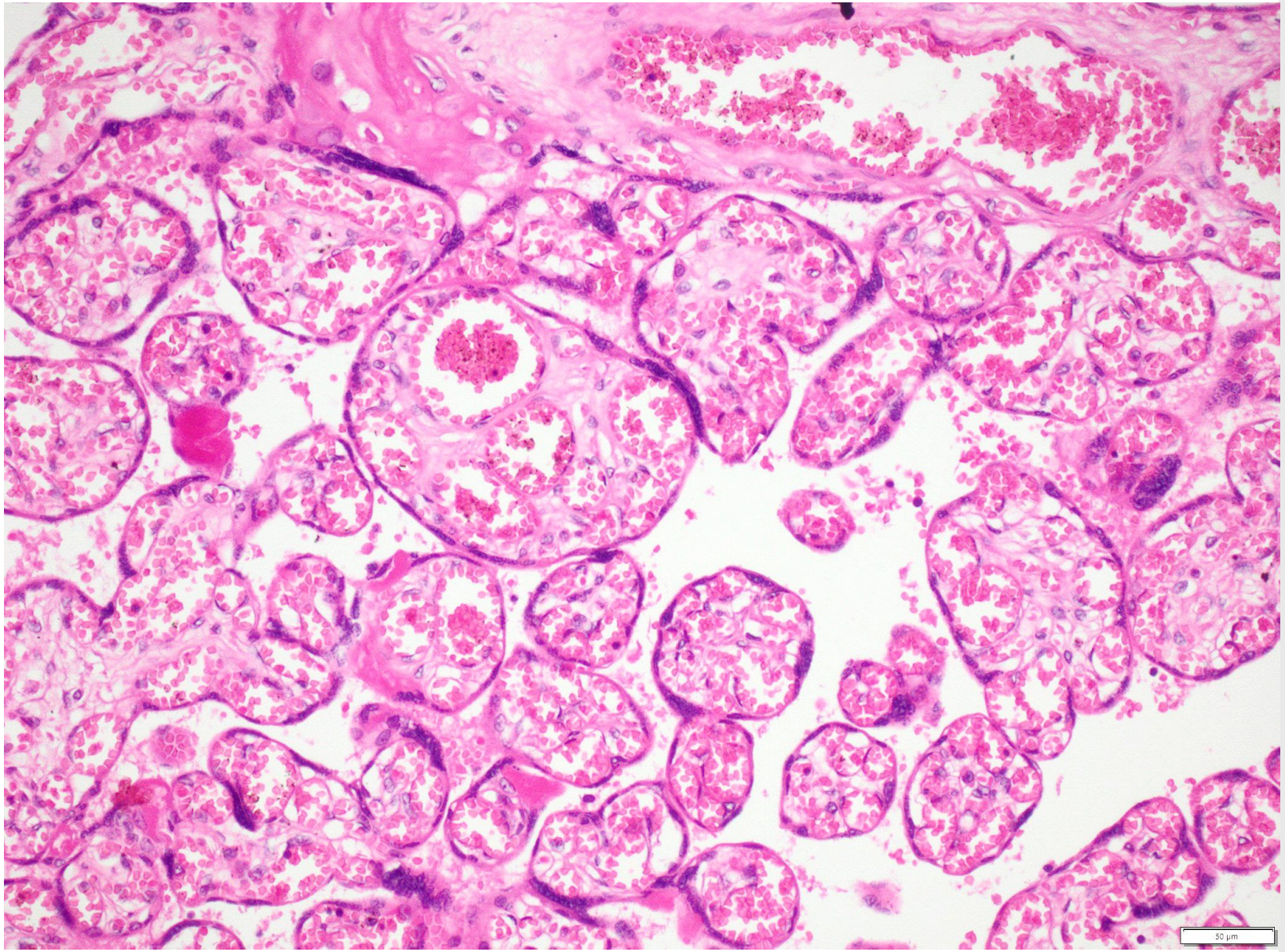

congestie

< 10 capillaire doorsneden per vlok.

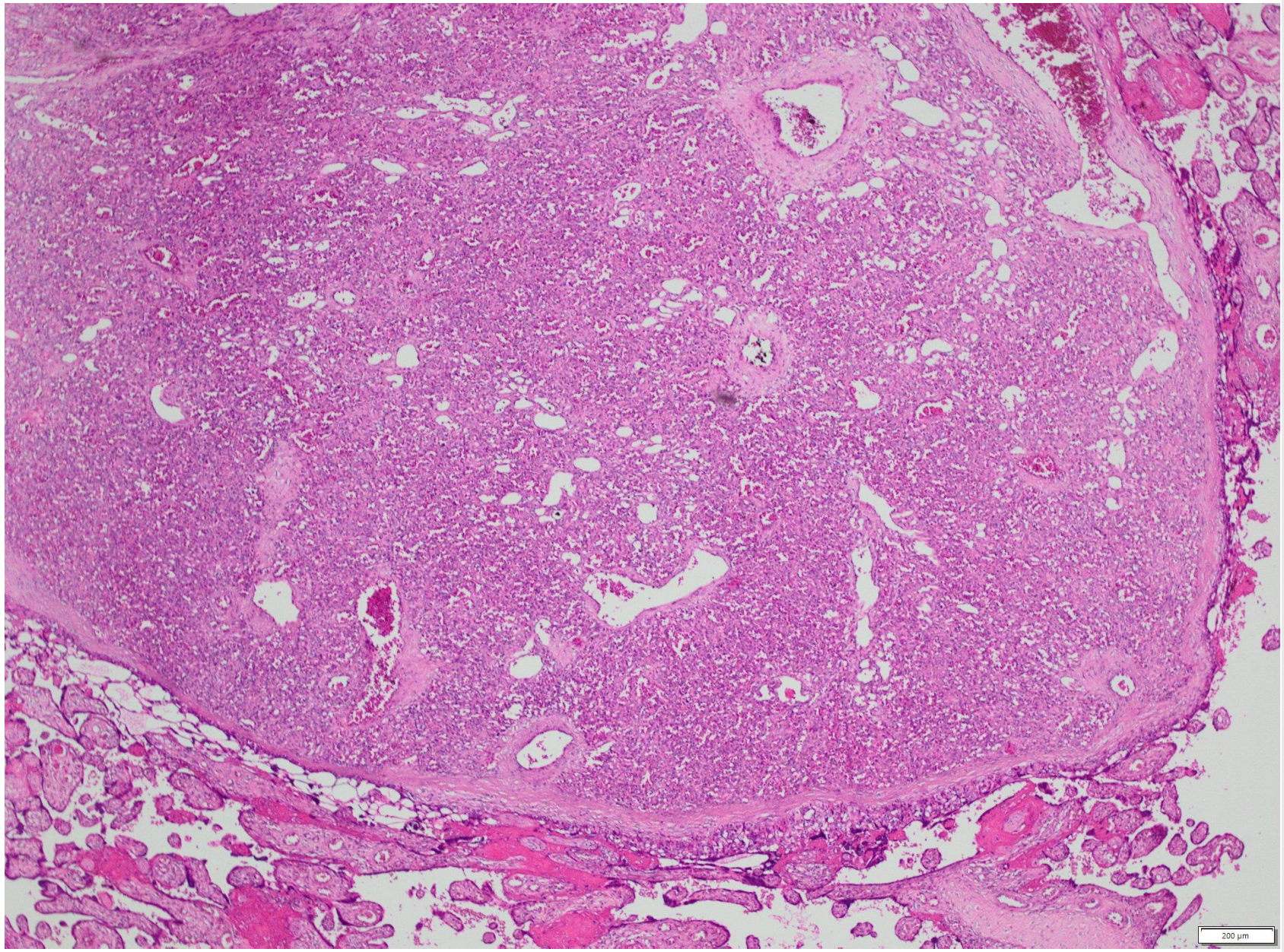

chorangioom

Scherp begrensde tumor opgebouwd uit choriale bloedvaten.

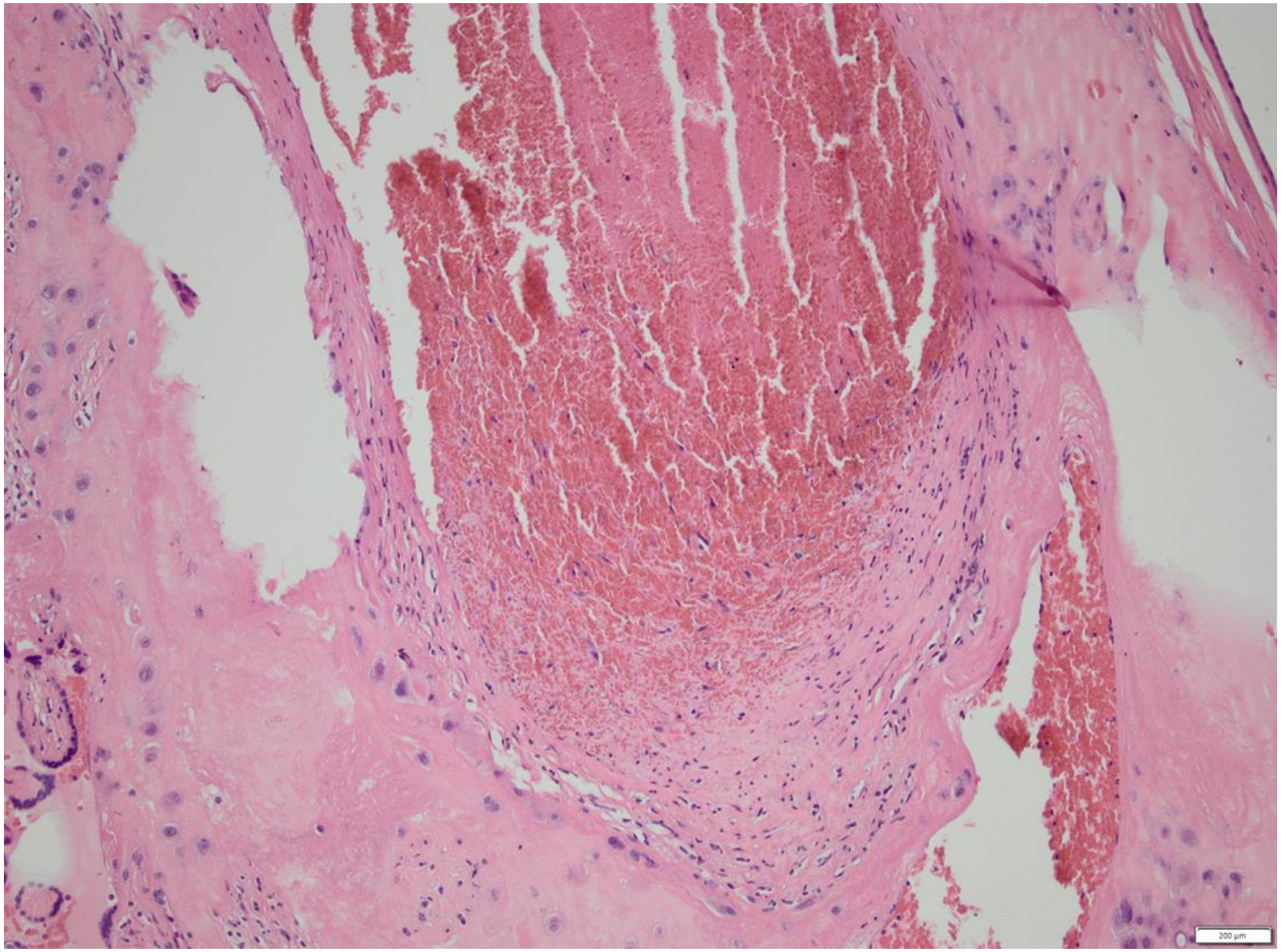

Fetal vascular malperfusion

SEGMENTAIR:

1, thrombose van choriale of stamvlokbloedvaten

2, segmentaire avasculaire villi

GLOBAAL:

1, partiële obstructie van umbilicale bloedflow

2, intramurale fibrinedepositie in grote foetale bloedvaten

3, multipele kleine foci met avasculaire vlokken (<5 vlokken)

4, villeuze stromale vasculaire karyorrhexis

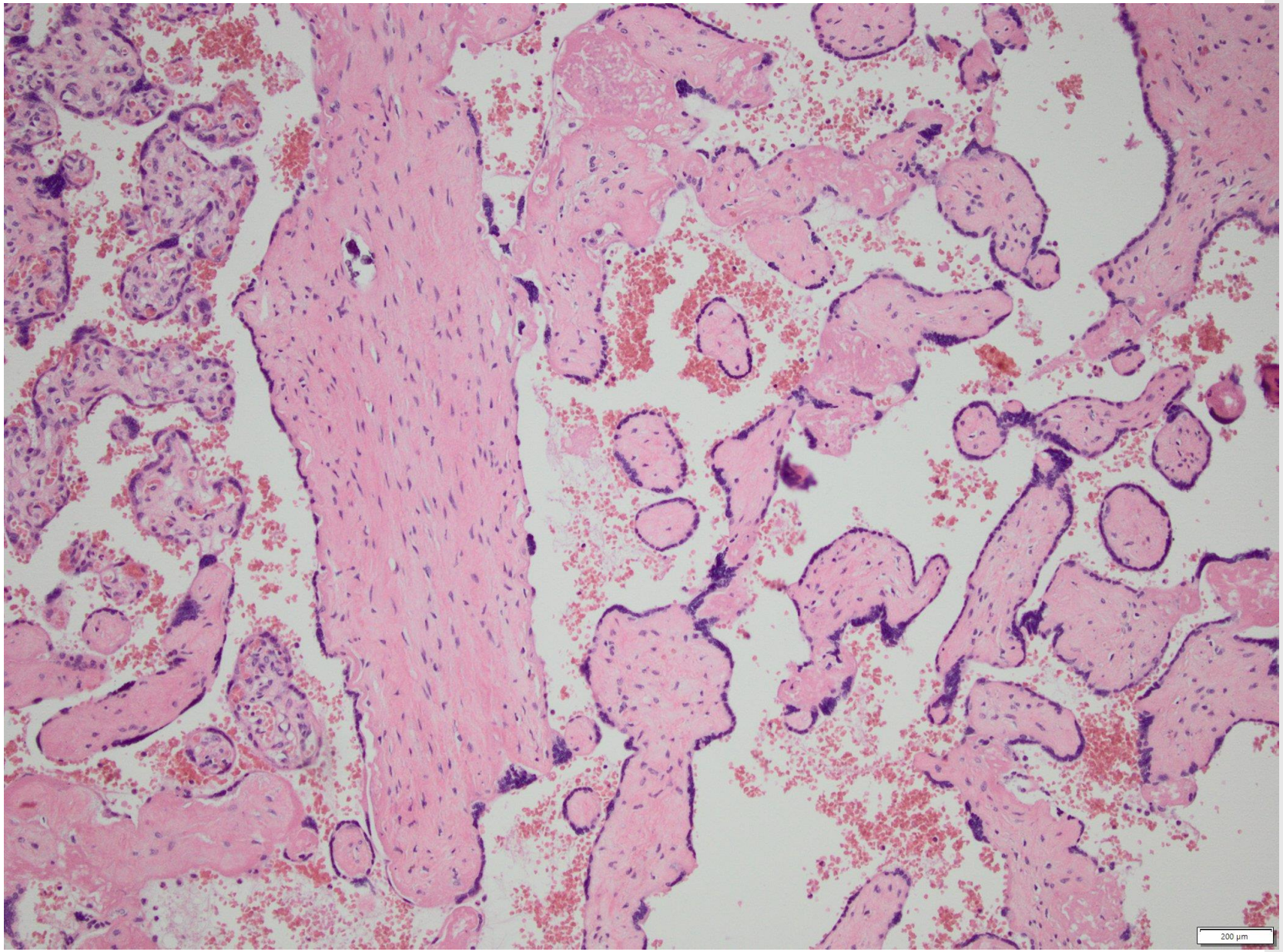

Avasculaire vlokken

- Kleine foci: 2-4 vlokken
- Middelgrote foci: 5-10 vlokken
- Grote foci: >10 vlokken

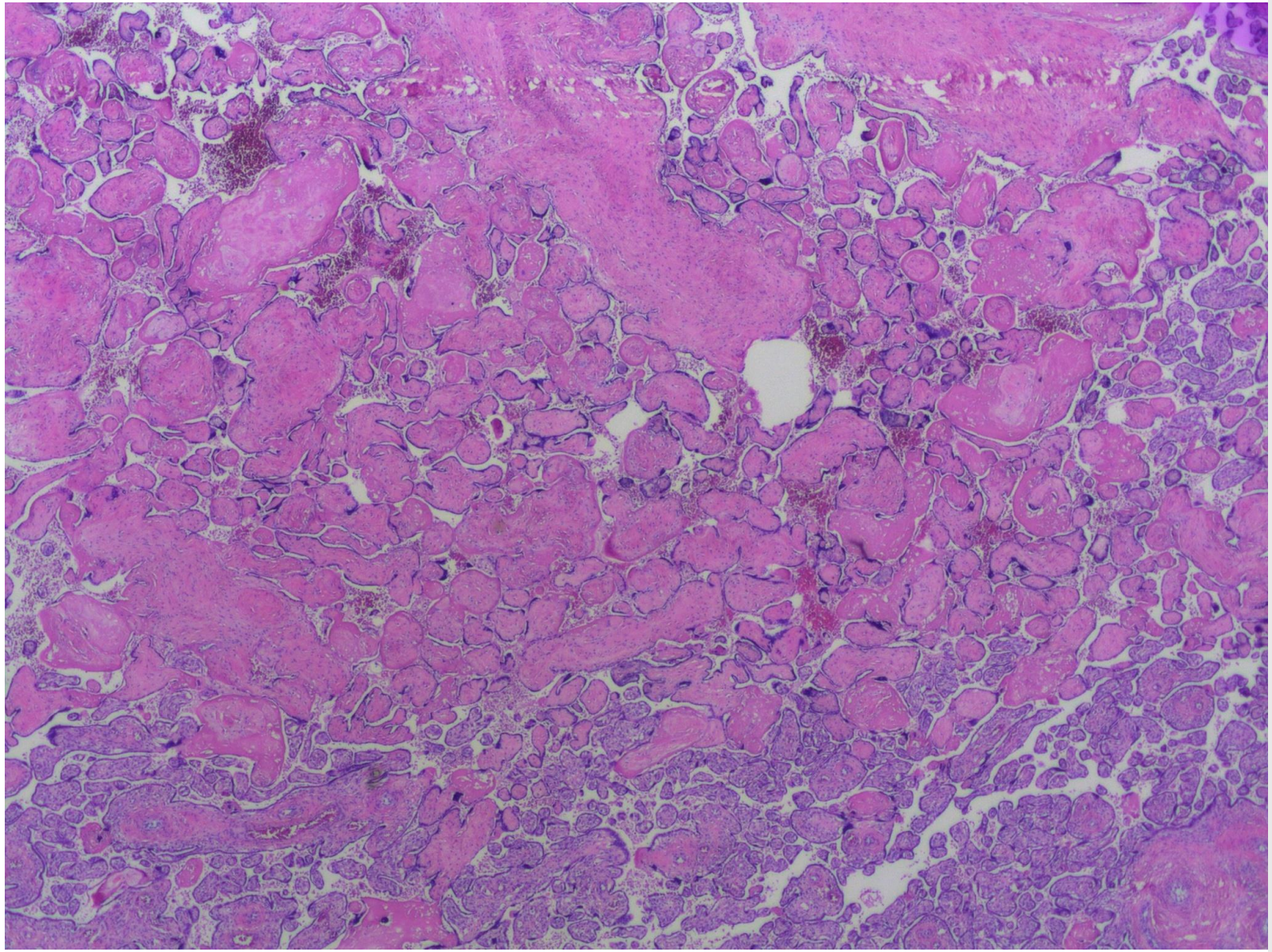

Avasculaire vlokken

Grote focus

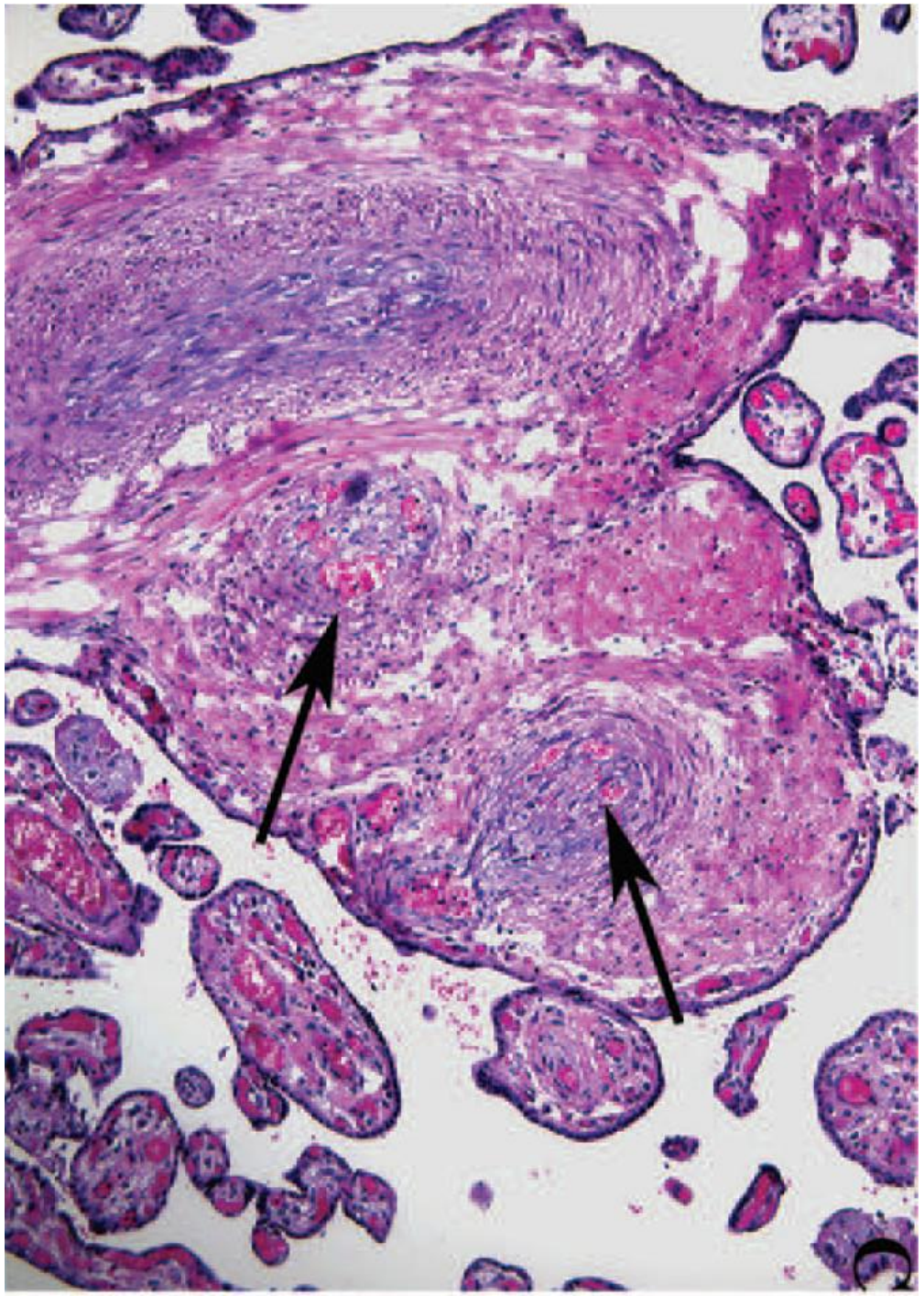

Villeuze stromale vasculaire karyorrhexis

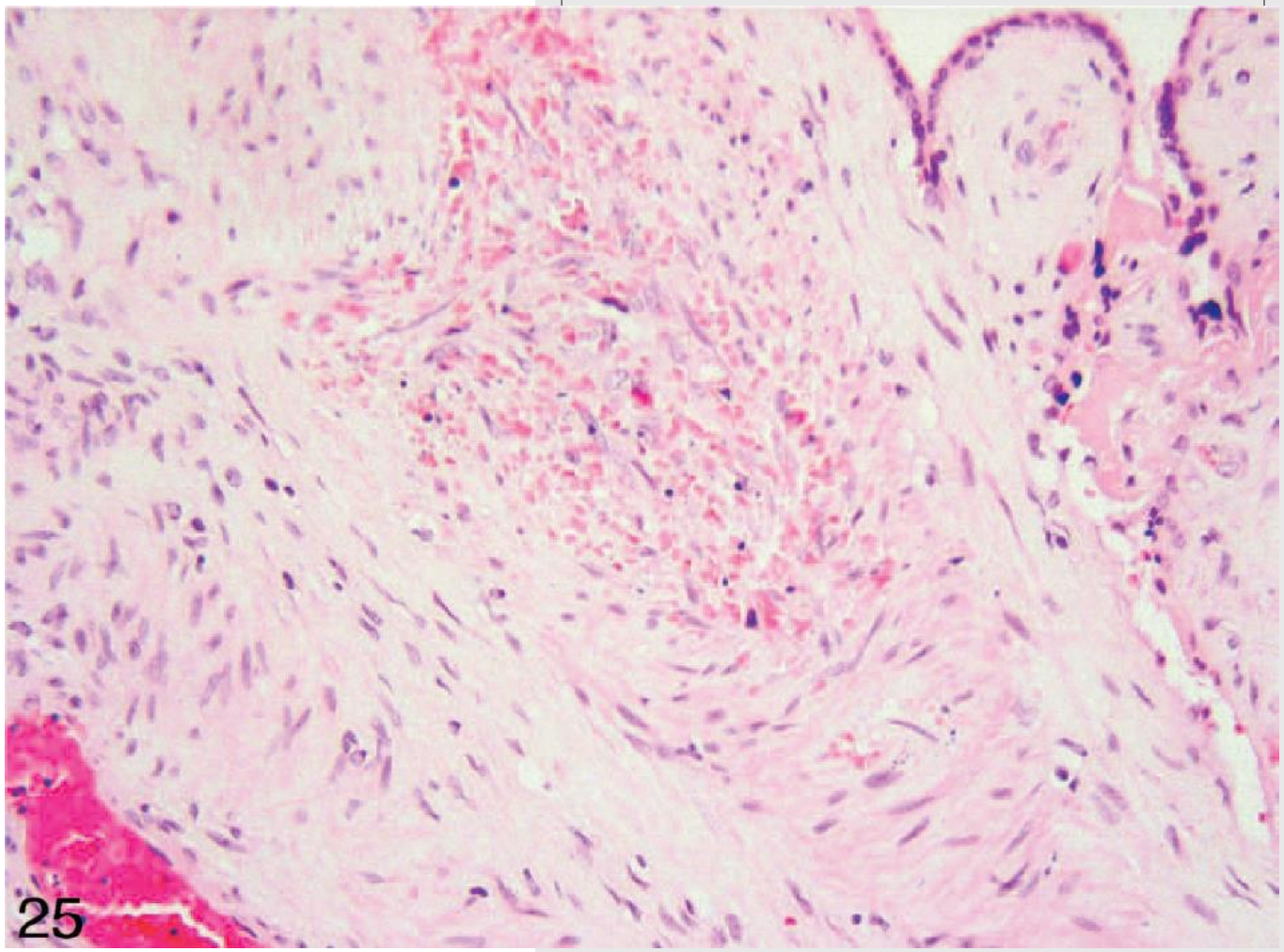

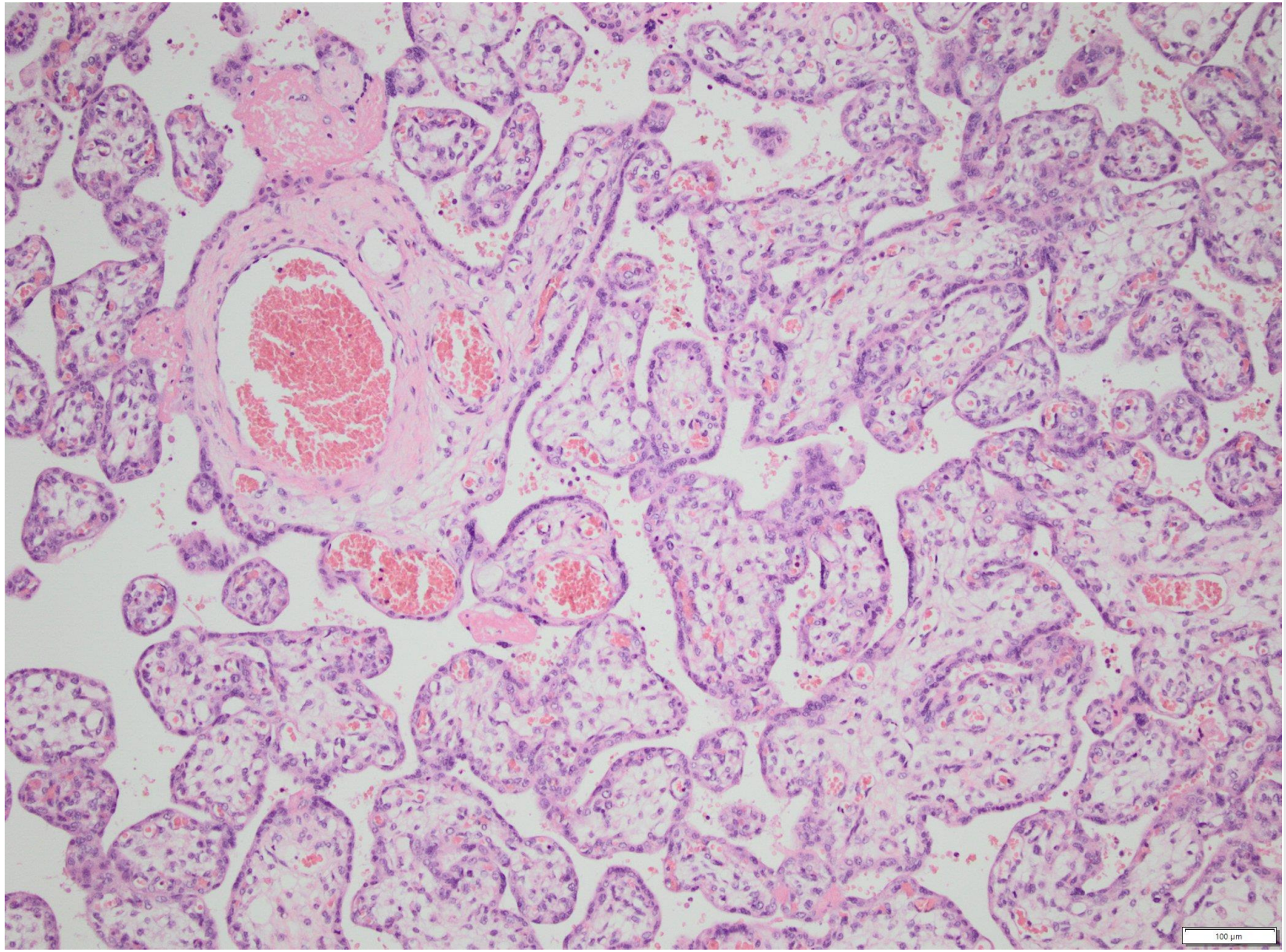

“Delayed villous maturation”: te weinig gevorderde vlokkenmaturatie.

- Zone van minstens 10 monotone vlokken met minder syncytiocapillaire membranen, lijkend op 2e trimester vlokken.
- Diagnose alleen wanneer aanwezig in > 30% van een coupe.
- Klinische betekenis onduidelijk.

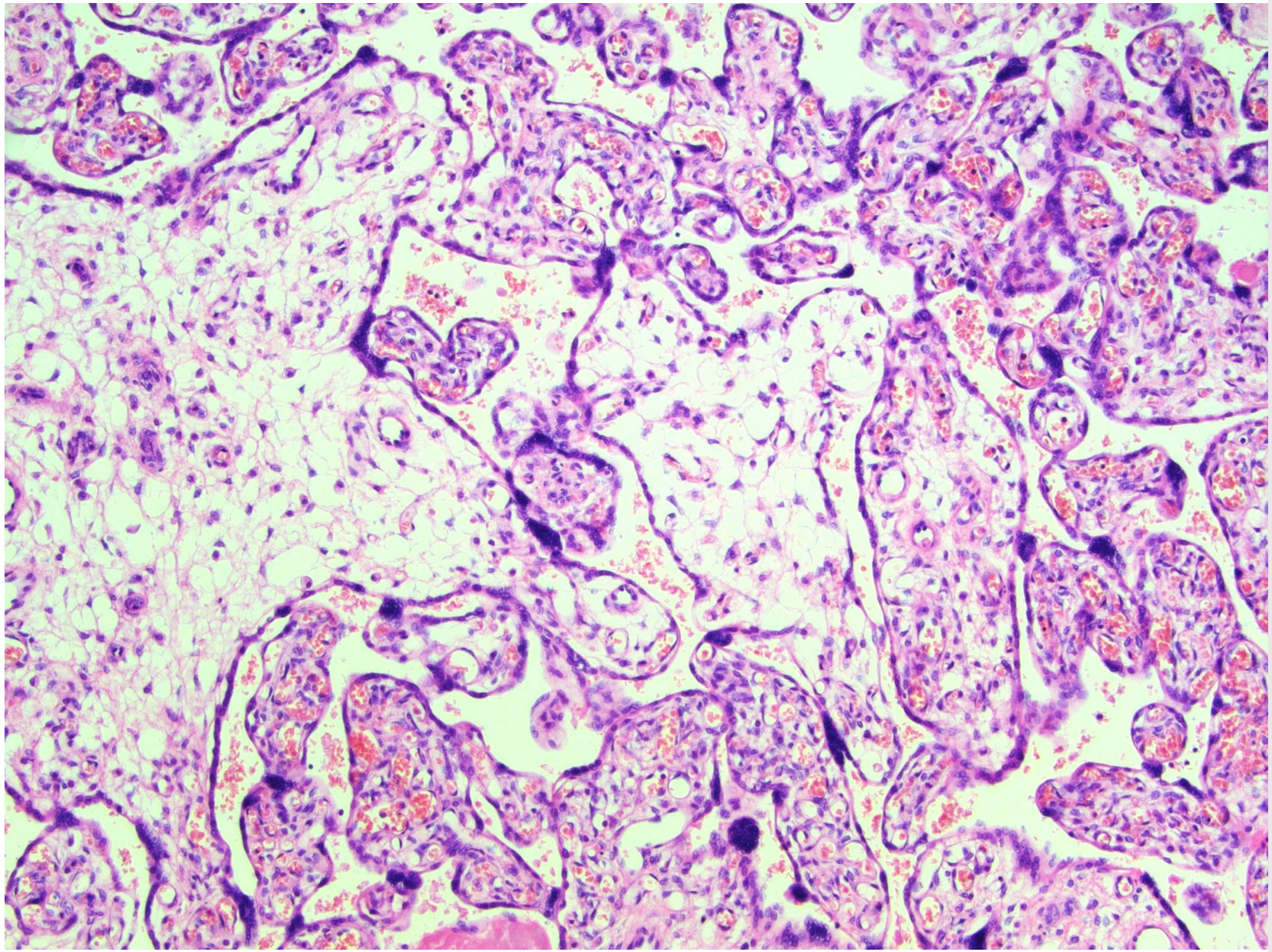

Chronisch vlokoedeem

Staging and Grading of the Maternal and Fetal Inflammatory Responses in Ascending Intrauterine Infection	
Maternal Inflammatory Response	
Stage 1—acute subchorionitis or chorionitis Stage 2—acute chorioamnionitis: polymorphonuclear leukocytes extend into fibrous chorion and/or amnion Stage 3—necrotizing chorioamnionitis: karyorrhexis of polymorphonuclear leukocytes, amniocyte necrosis, and/or amnion basement membrane hypereosinophilia	Grade 1—not severe as defined Grade 2—severe: confluent polymorphonuclear leukocytes or with subchorionic microabscesses
Fetal Inflammatory Response	
Stage 1—chorionic vasculitis or umbilical phlebitis Stage 2—involvement of the umbilical vein and one or more umbilical arteries Stage 3—necrotizing funisitis	Grade 1—not severe as defined Grade 2—severe: near-confluent intramural polymorphonuclear leukocytes with attenuation of vascular smooth muscle

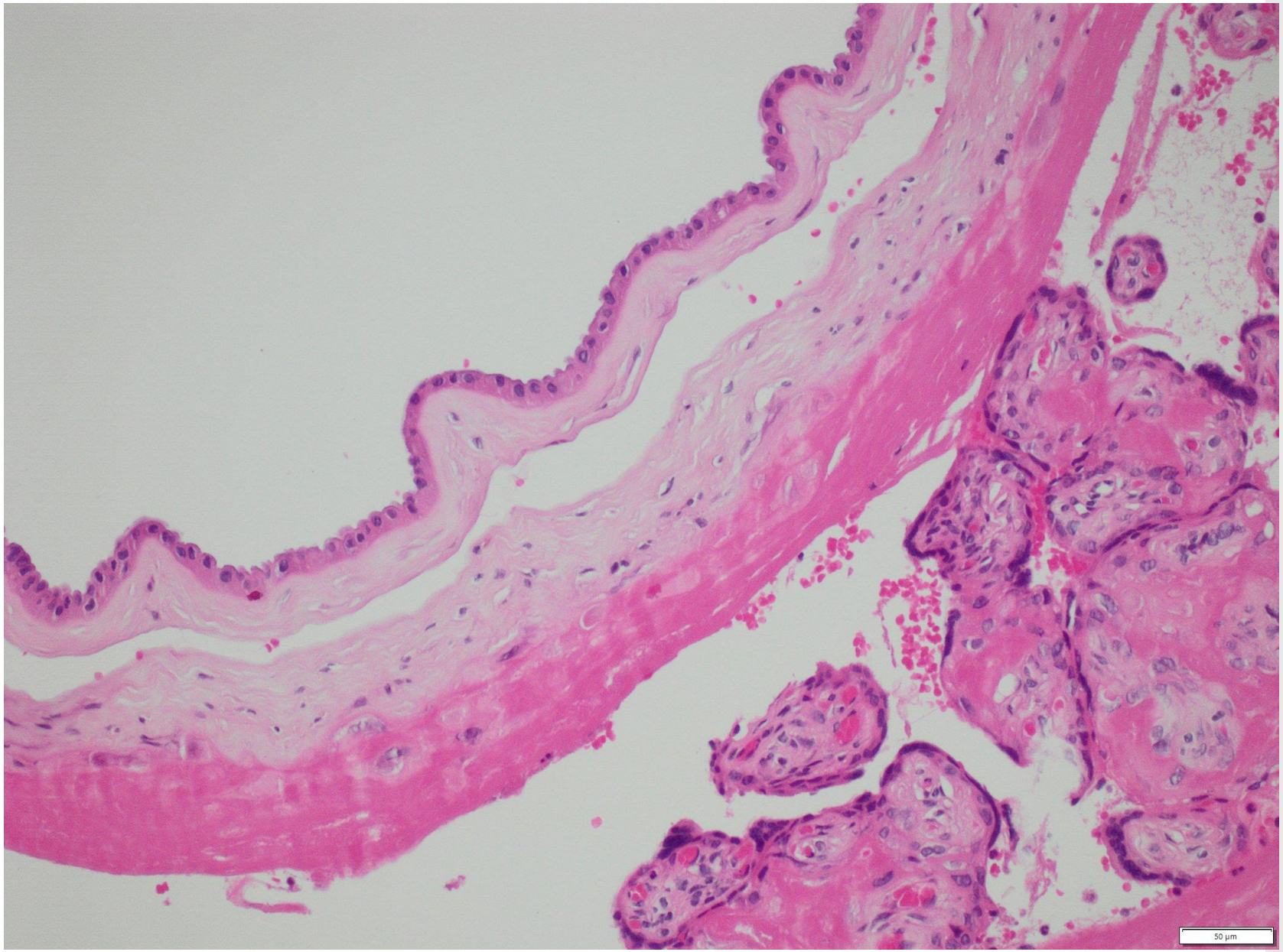

Subchoriale fibrine zonder ontsteking

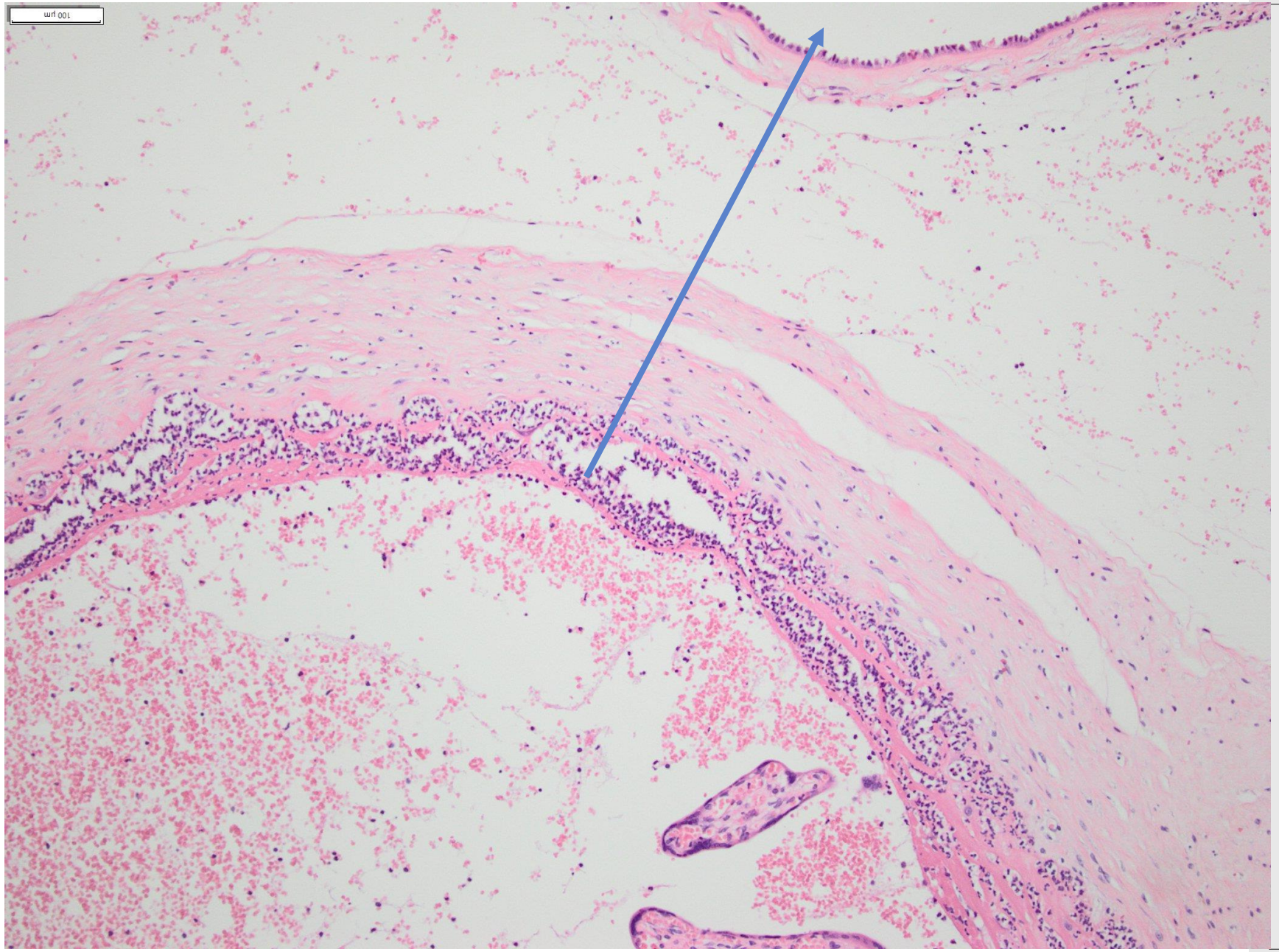

Acute chorioamnionitis stadium 2 graad 2

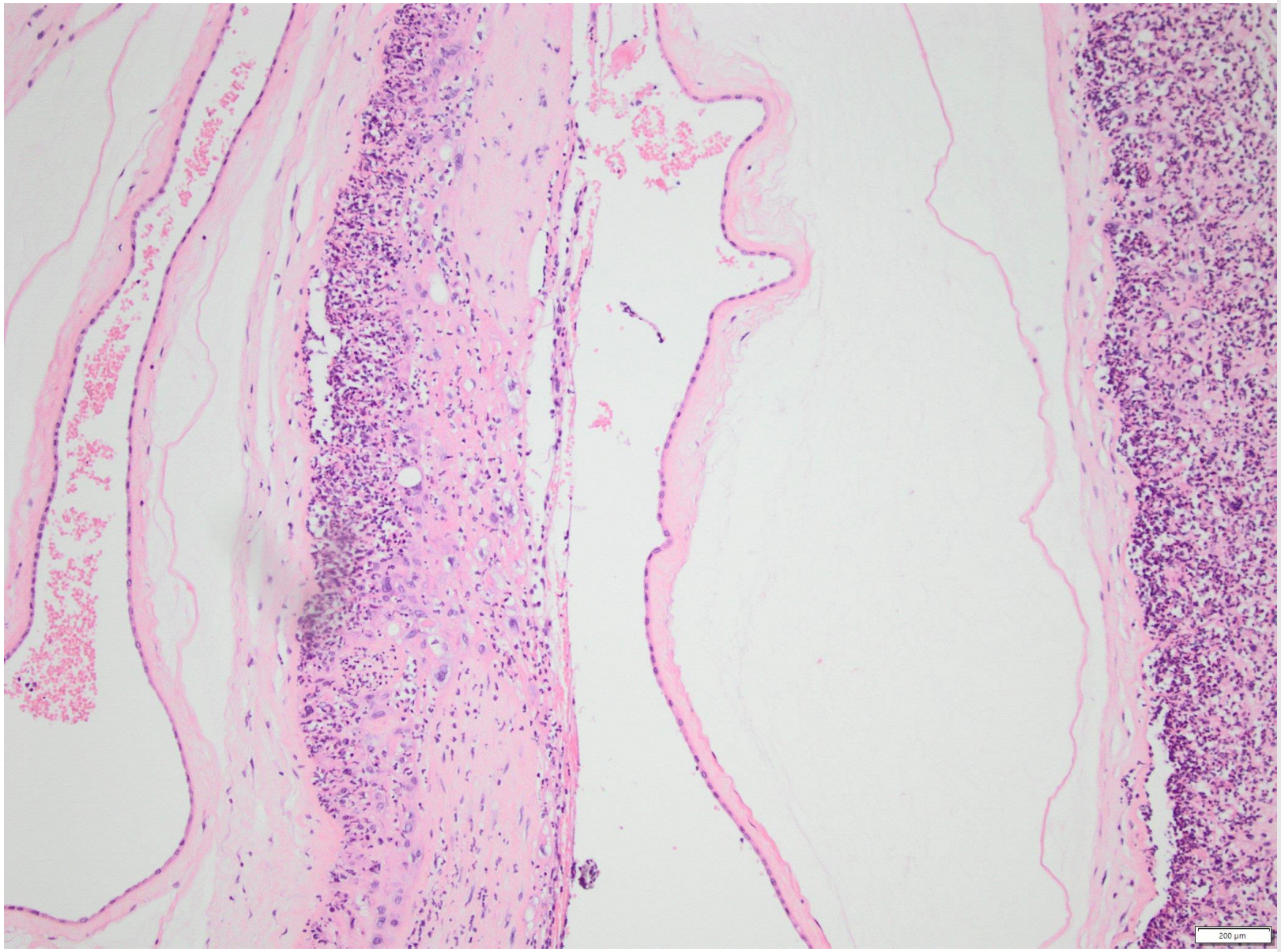

Acute chorioamnionitis stadium 1 graad 2

In vliezenrol: kijk net onder en in chorion.

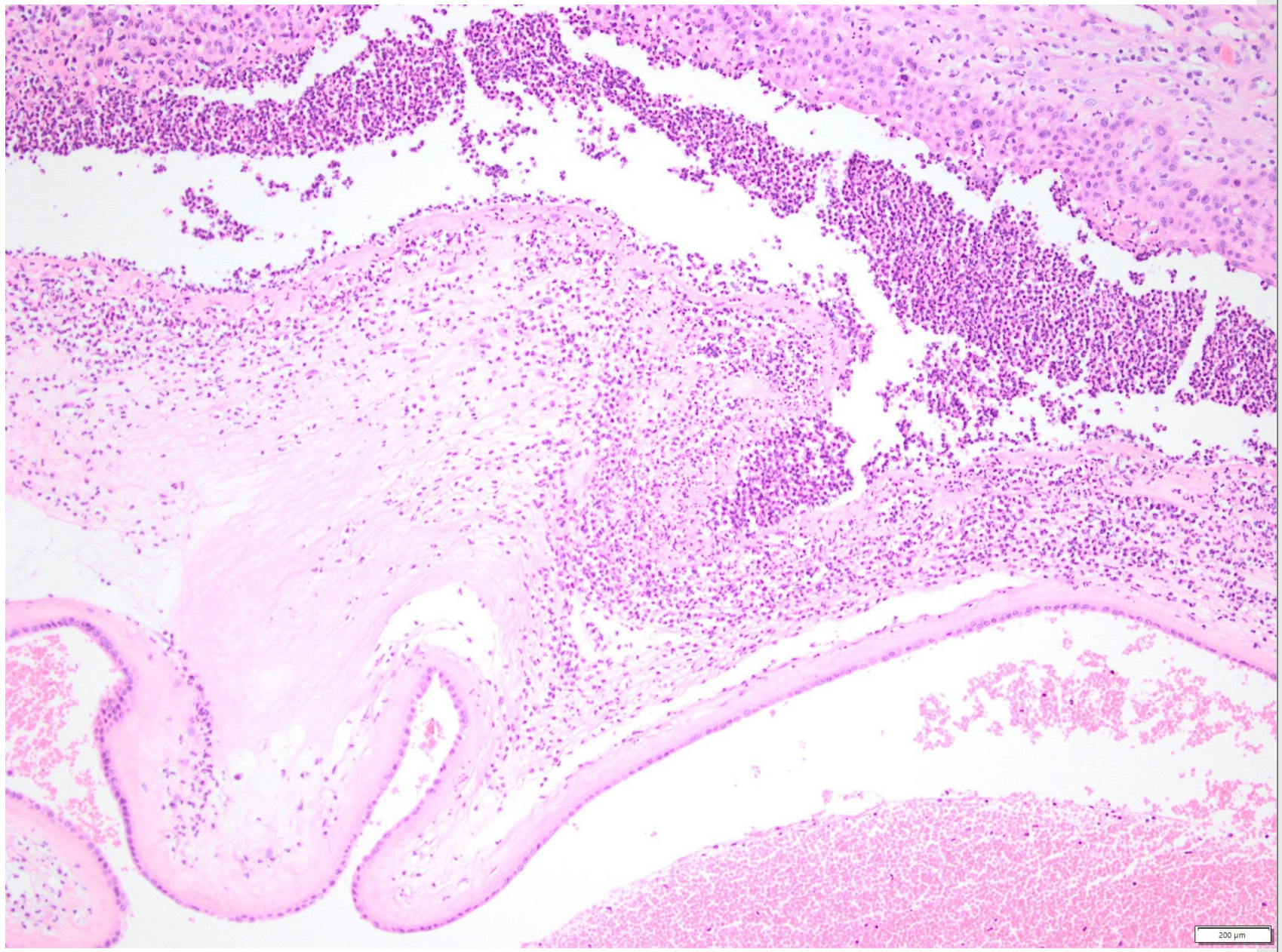

Acute chorioamnionitis stadium 2 graad 2

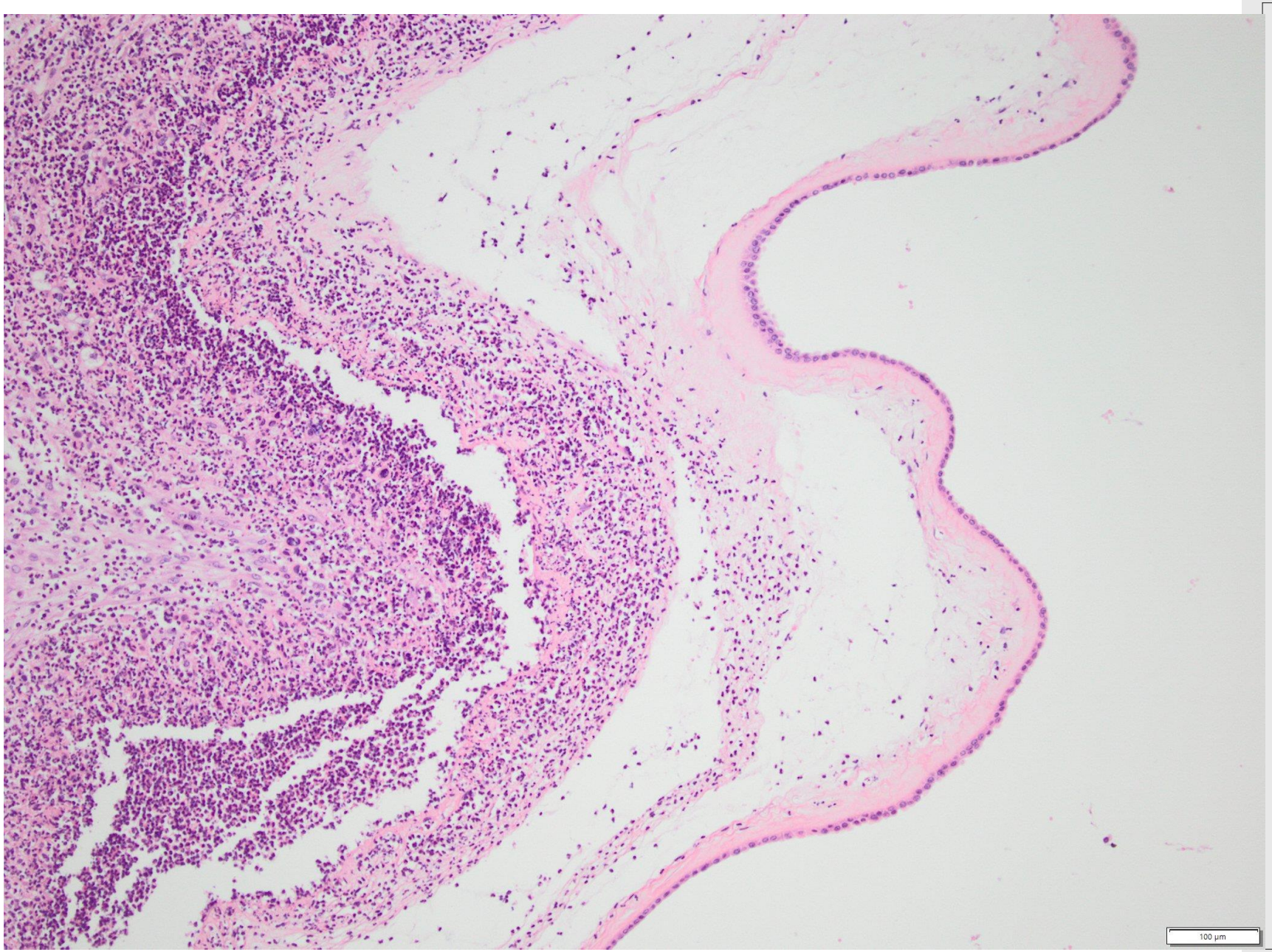

Acute chorioamnionitis stadium 2 graad 2

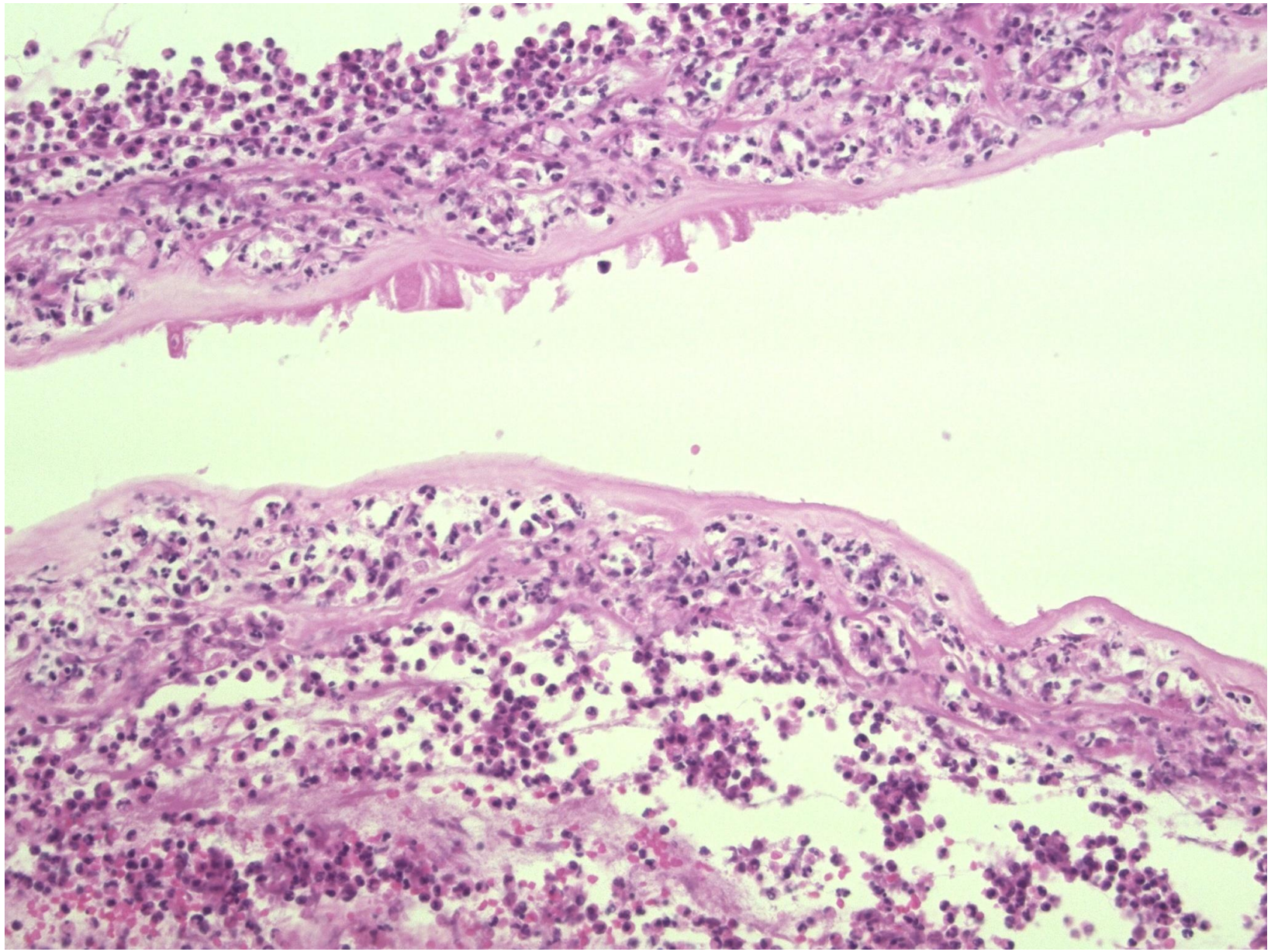

Acute chorioamnionitis stadium 3 graad 2

Necrose van het amnionepitheel

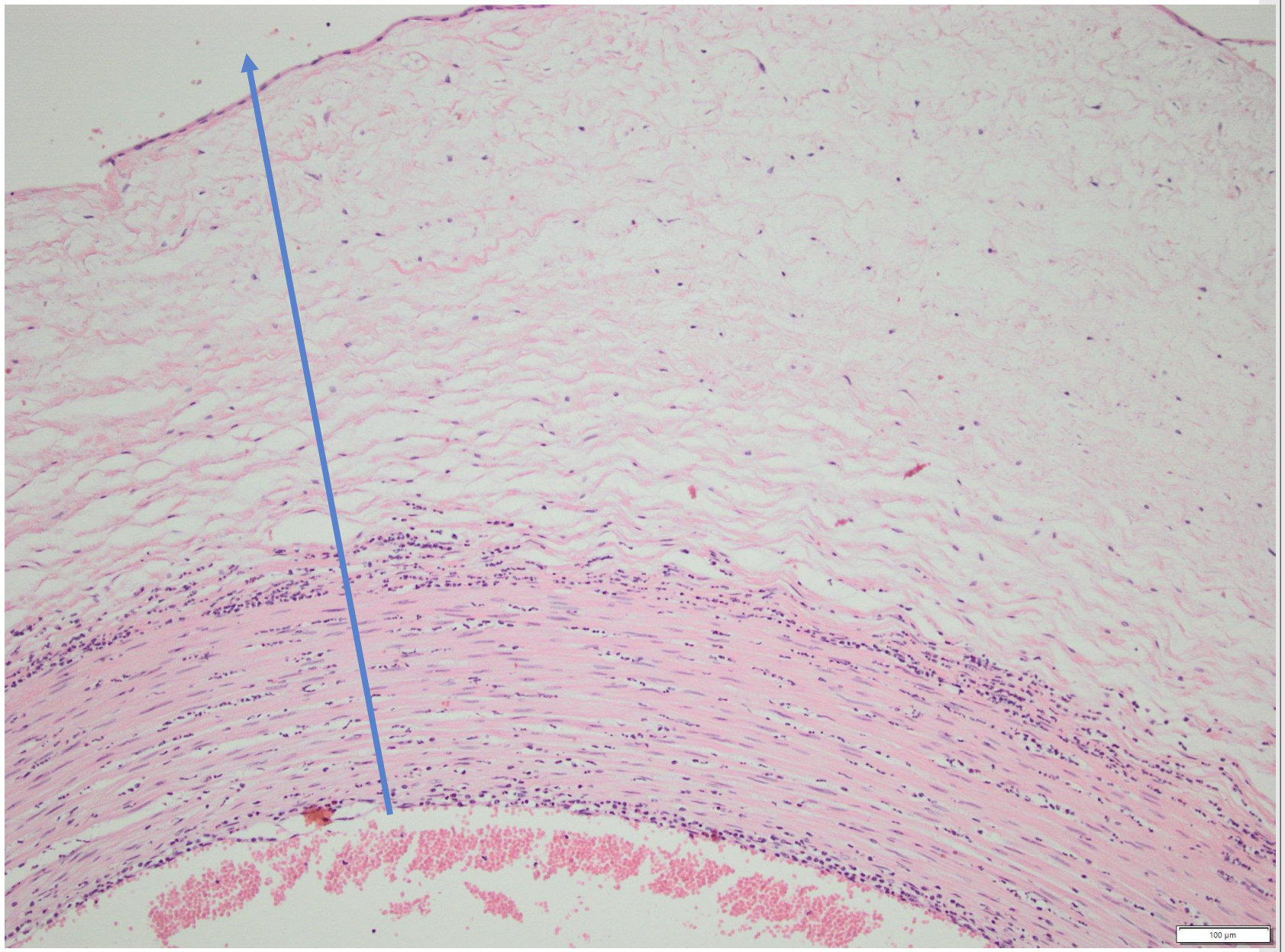

Acute vasculitis van een choriaal bloedvat

Foetale inflammatoire respons stadium 1, graad 1

Chemotaxis en diapedese van neutrofiele granulocyten in richting van vruchtzak.

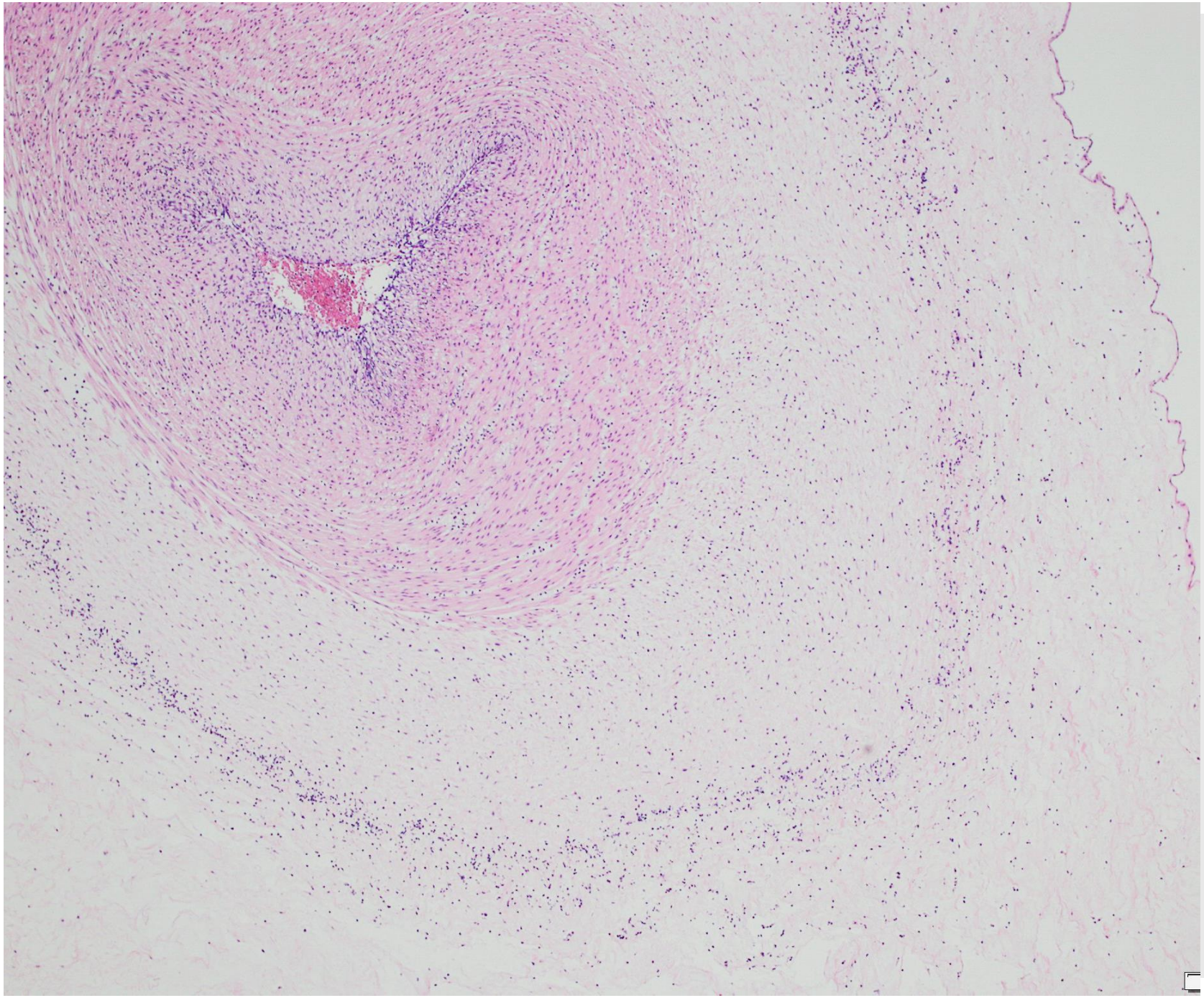

Necrotizerende funisitis

Fetale inflammatoire respons stadium 3, graad 1

Accumulatie van neutrofielen en necrose van gelei van Wharton rond de navelbloedvaten: Mickey mouse sign.

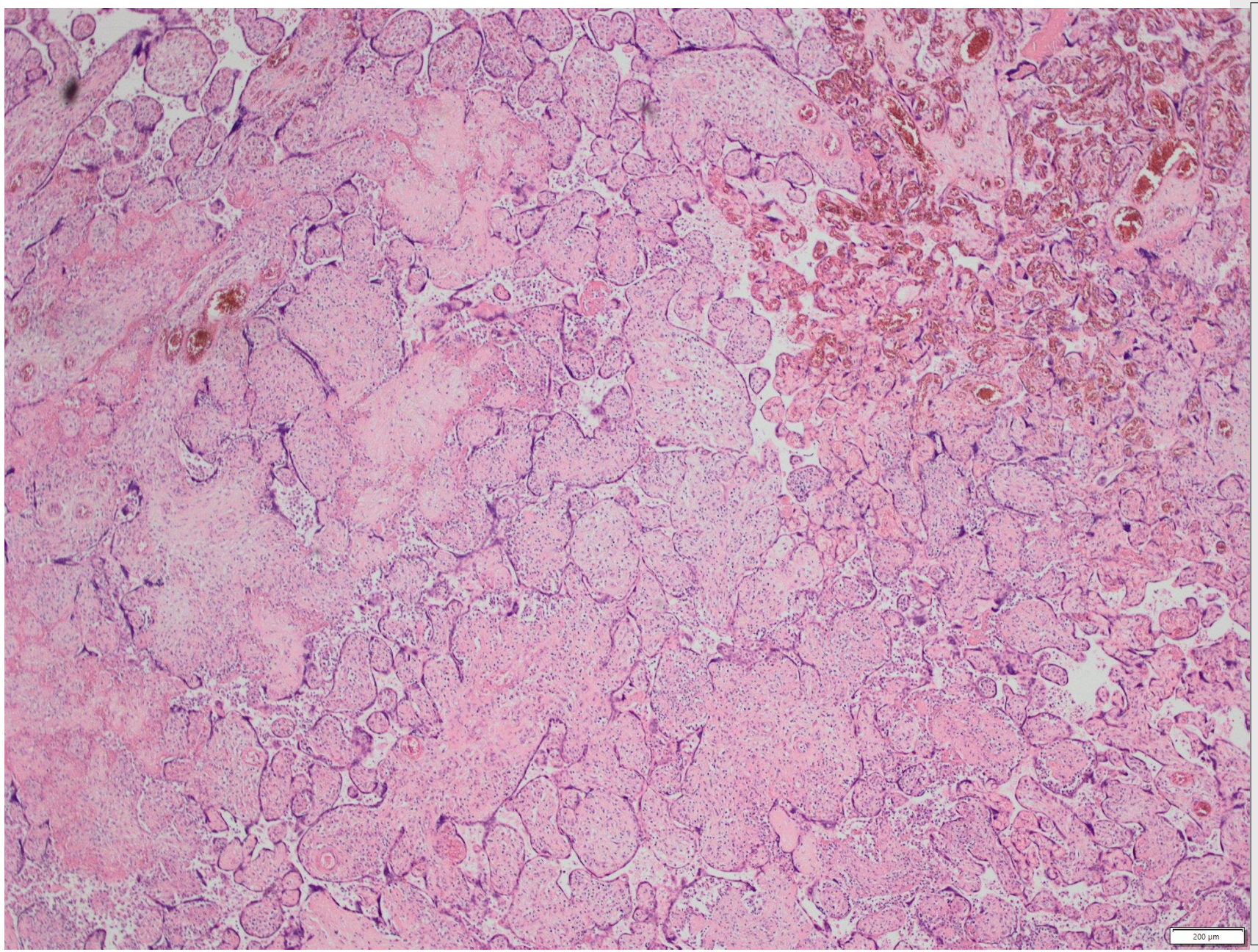

Villitis of unknown etiology VUE

- Meest frequente vorm van villitis
- Minstens 3 parenchymblokken nodig om 62% van de villitiden te ontdekken
- Lymfohistiocytaire ontsteking in de vlokken, zelden plasmacellen
- Sluit infectieuze villitis uit:
  - Plasmacellen: cave CMV
  - Neutrofielen: bacteriëel

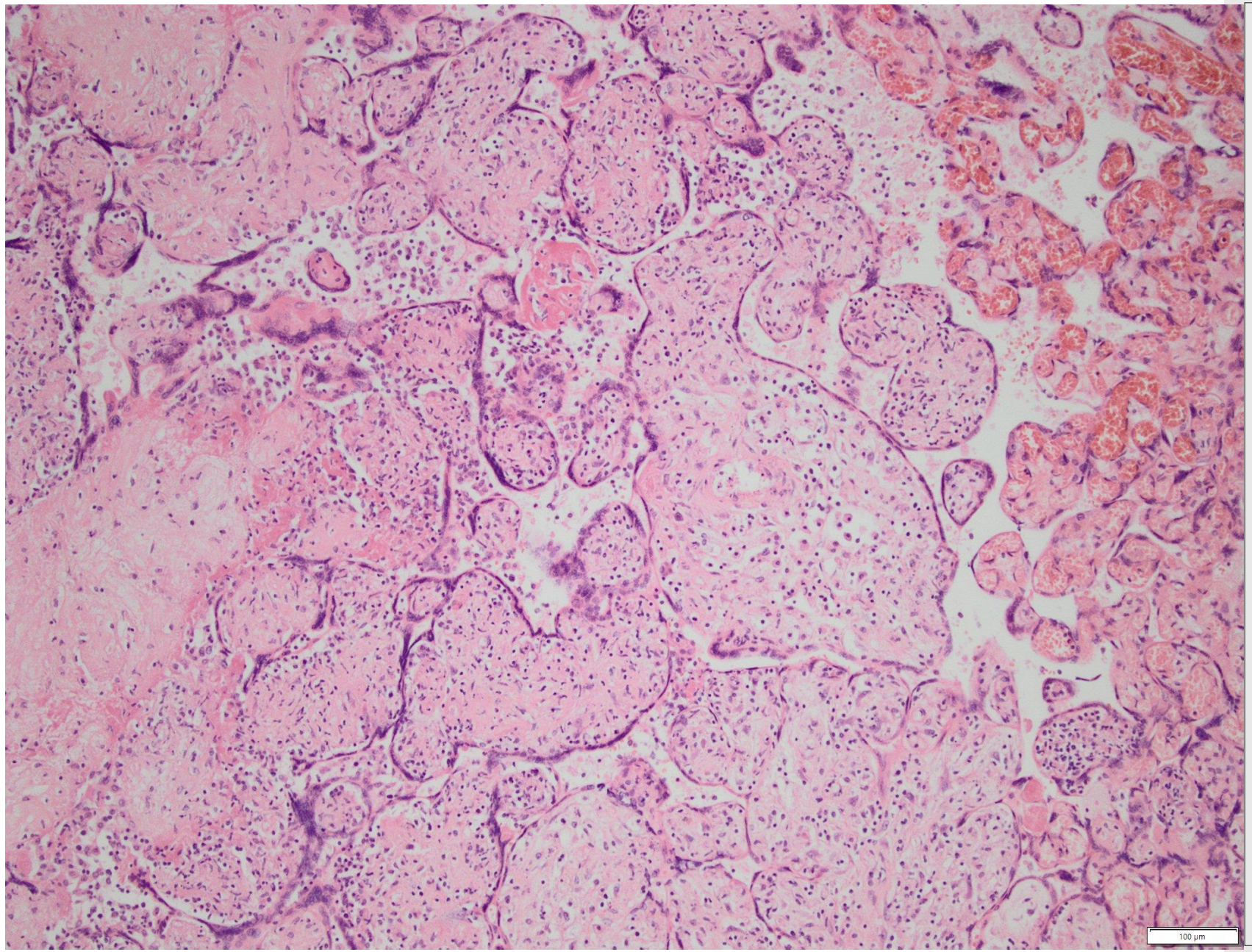

VUE

- Maternele gastheer tegen foetale allograft rejectie
- **Laaggradig**: minder dan 10 naast elkaar gelegen vlokken in elke focus van villitis / meer dan 1 focus nodig voor diagnose van VUE
- **Hooggradig**: multipele foci in meer dan 1 coupe, minstens 1 focus bevat > 10 ontstoken vlokken
- Hooggradig: meer kans op recidief, foetale groeirestrictie en slechte neurologische ontwikkeling
- 1 focus: > / < 10 vlokken = mogelijks hoog / laaggradig: sampling!

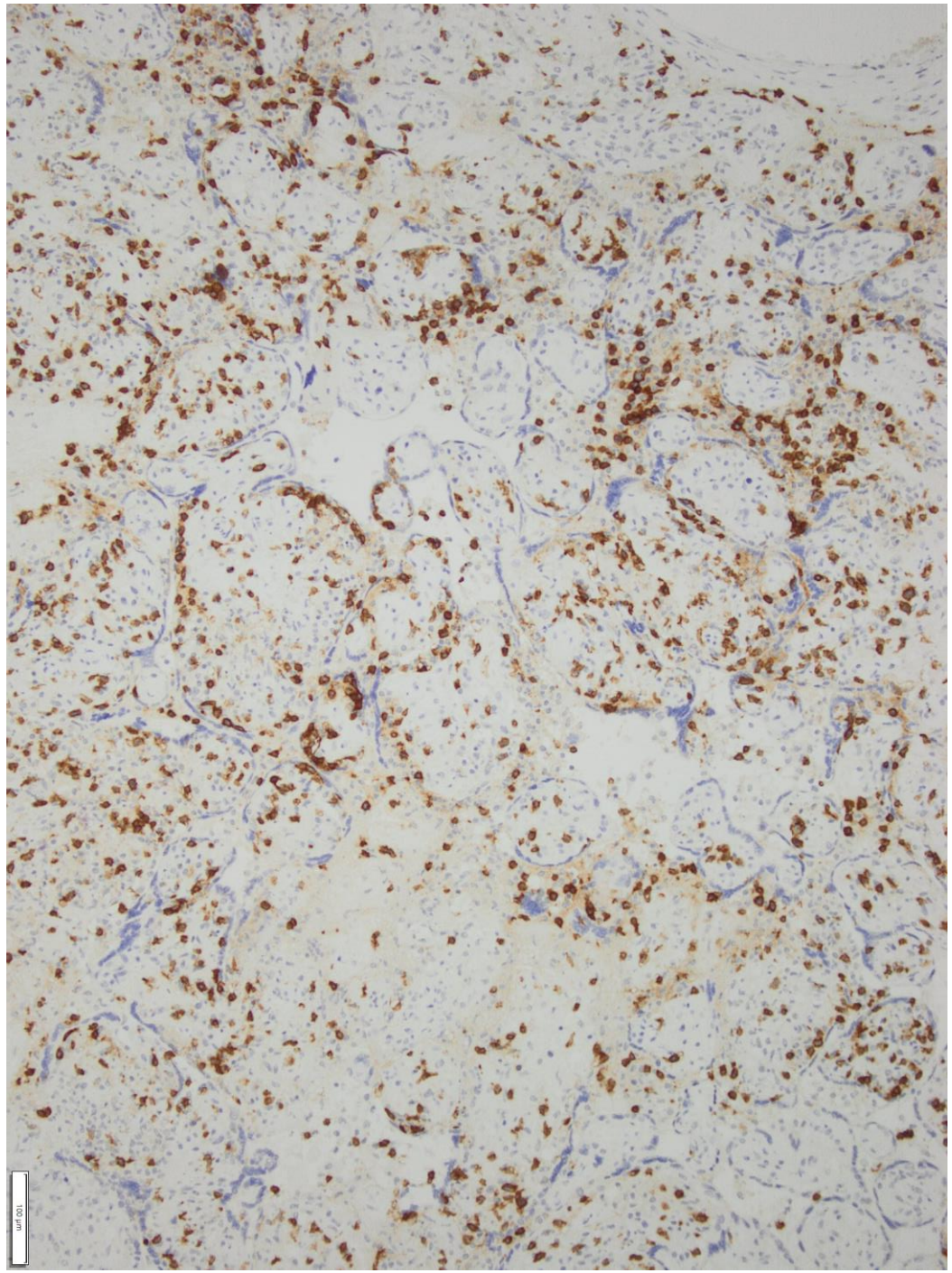

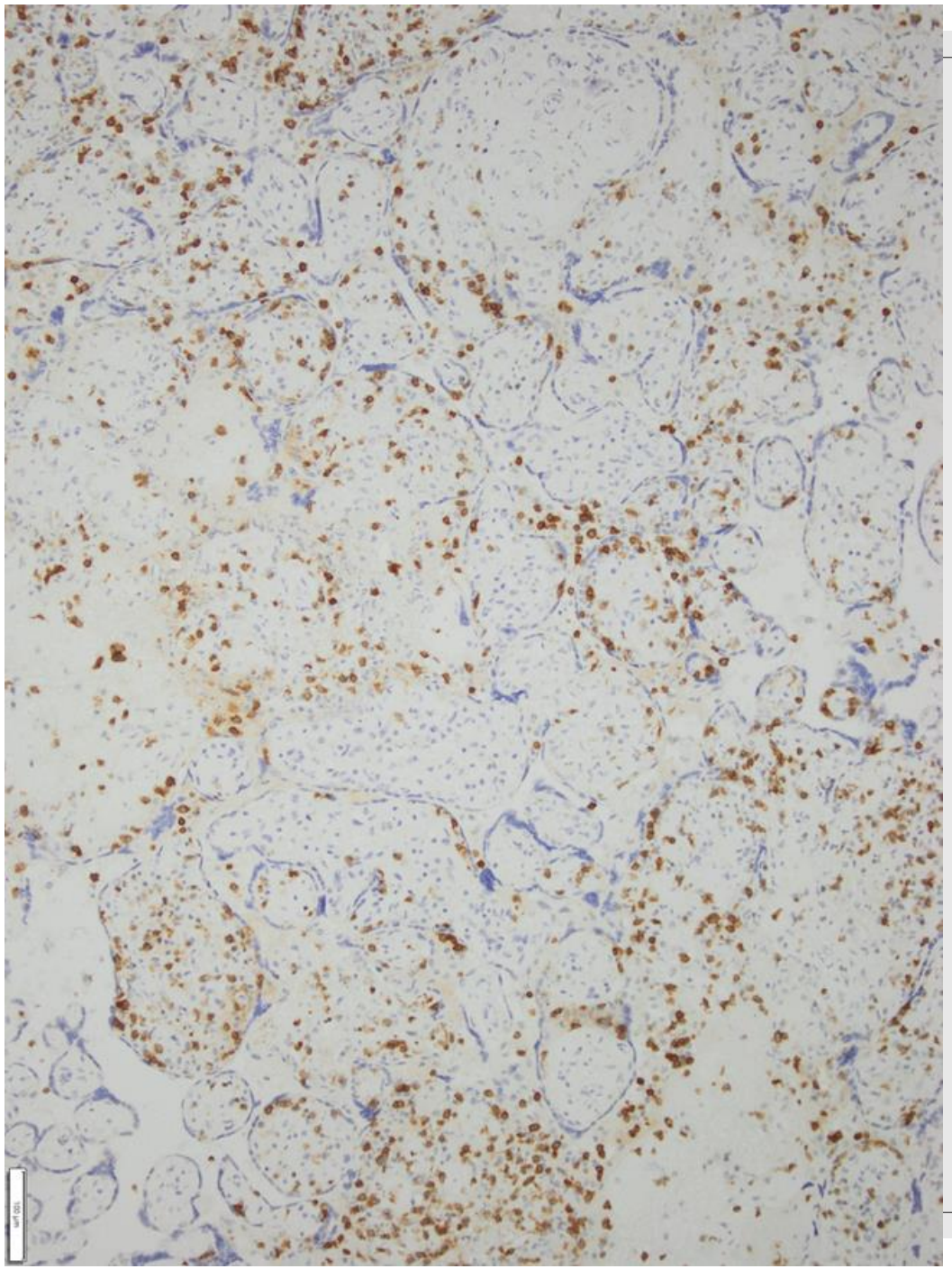

CD3
CD8

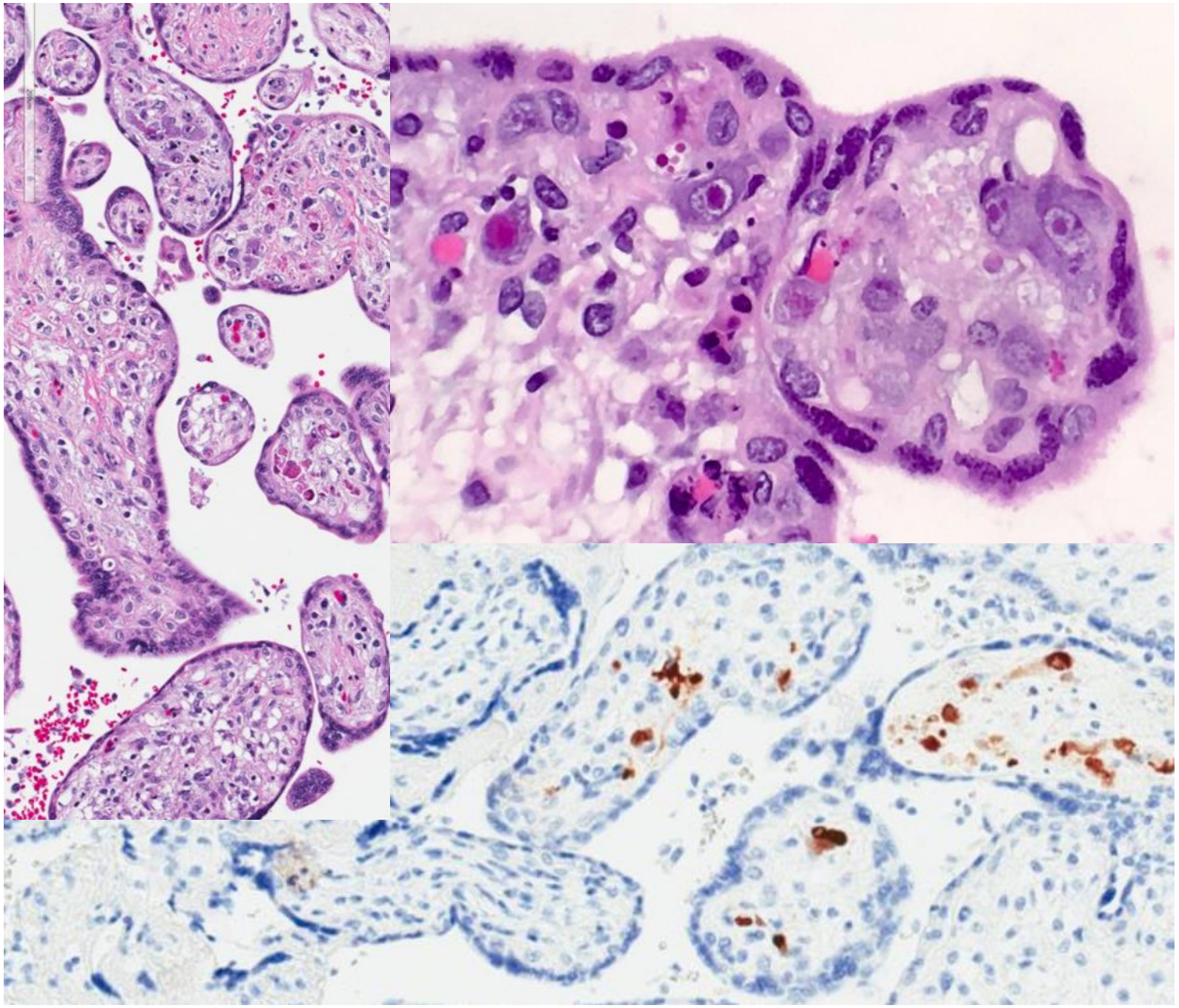

CMV villitis

Plasmacellen!

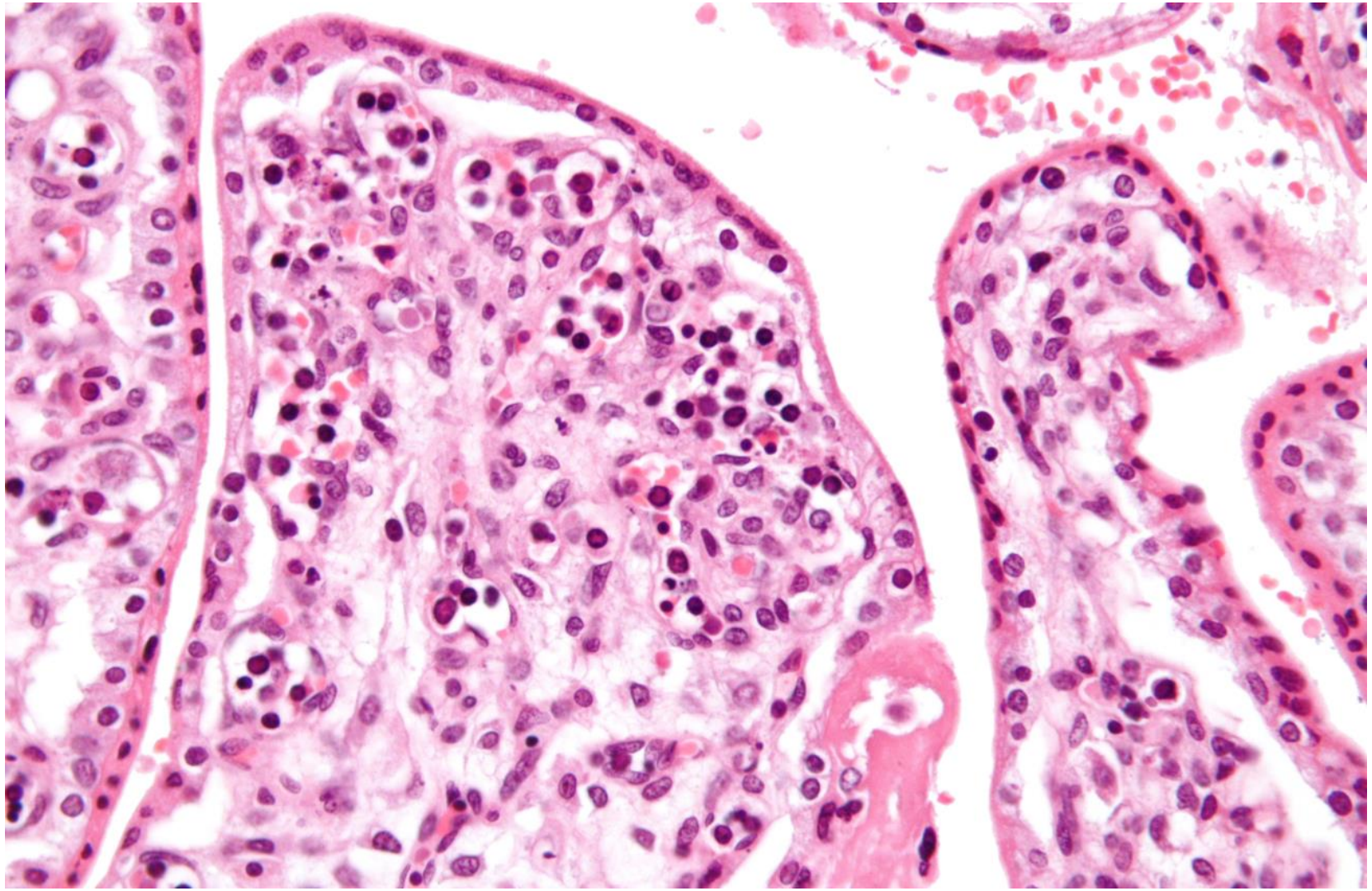

Foetale capillairen bevatten erythroblasten met intranucleaire inclusies

Parvovirus B19 infectie (5e ziekte, erythema infectiosum)

- 30-50% van zwangere vrouwen is niet-immuun
- Infectie van foetus kan zonder gevolg zijn, doch ook: hemolyse, anemie, hartfalen, hydrops, IUVD.
- Erythroblastosis foetalis met karakteristieke intranucleaire virale inclusies (matglaskern)
- Geen inflammatoire reactie, geen villitis.

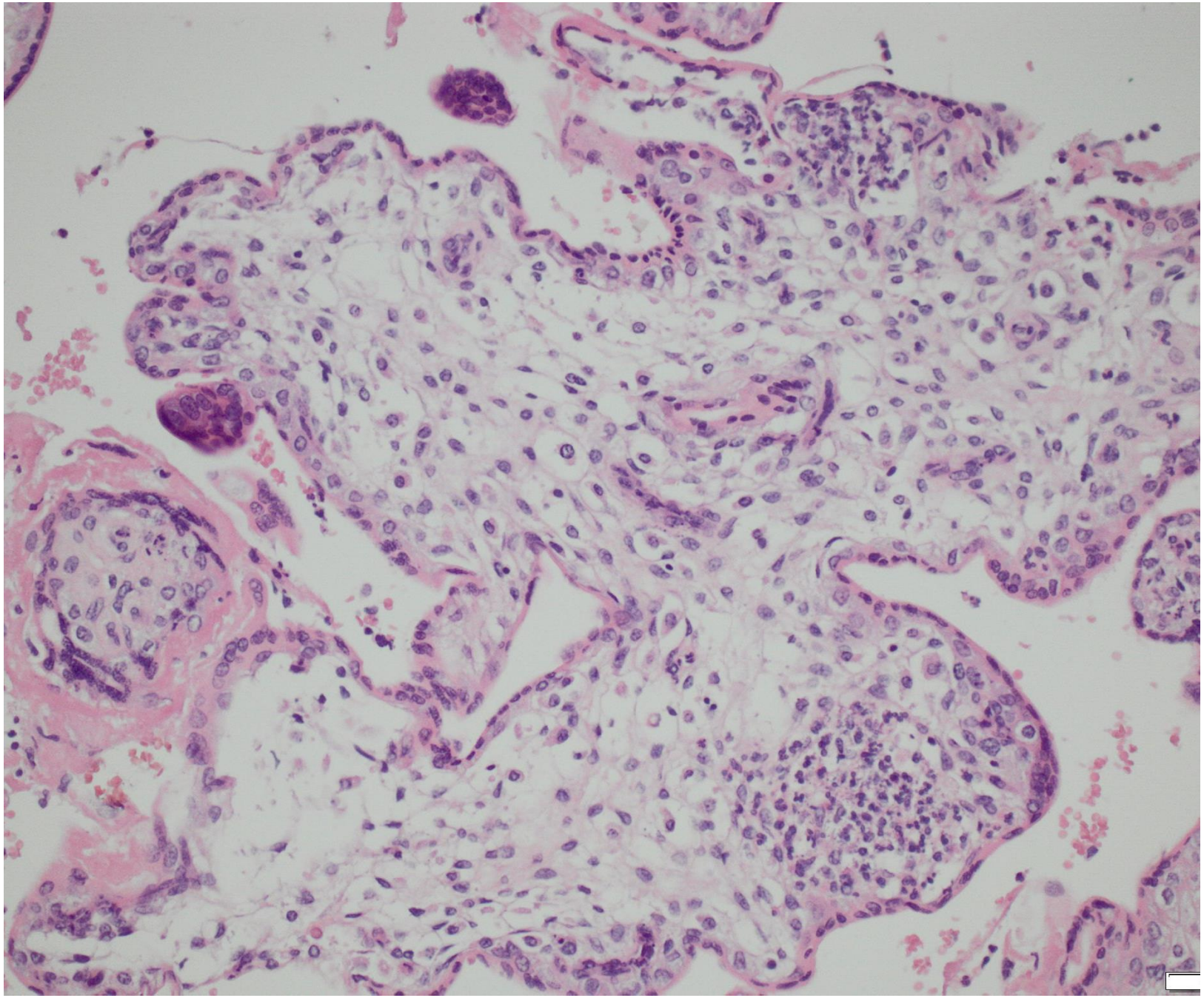

Acute villitis

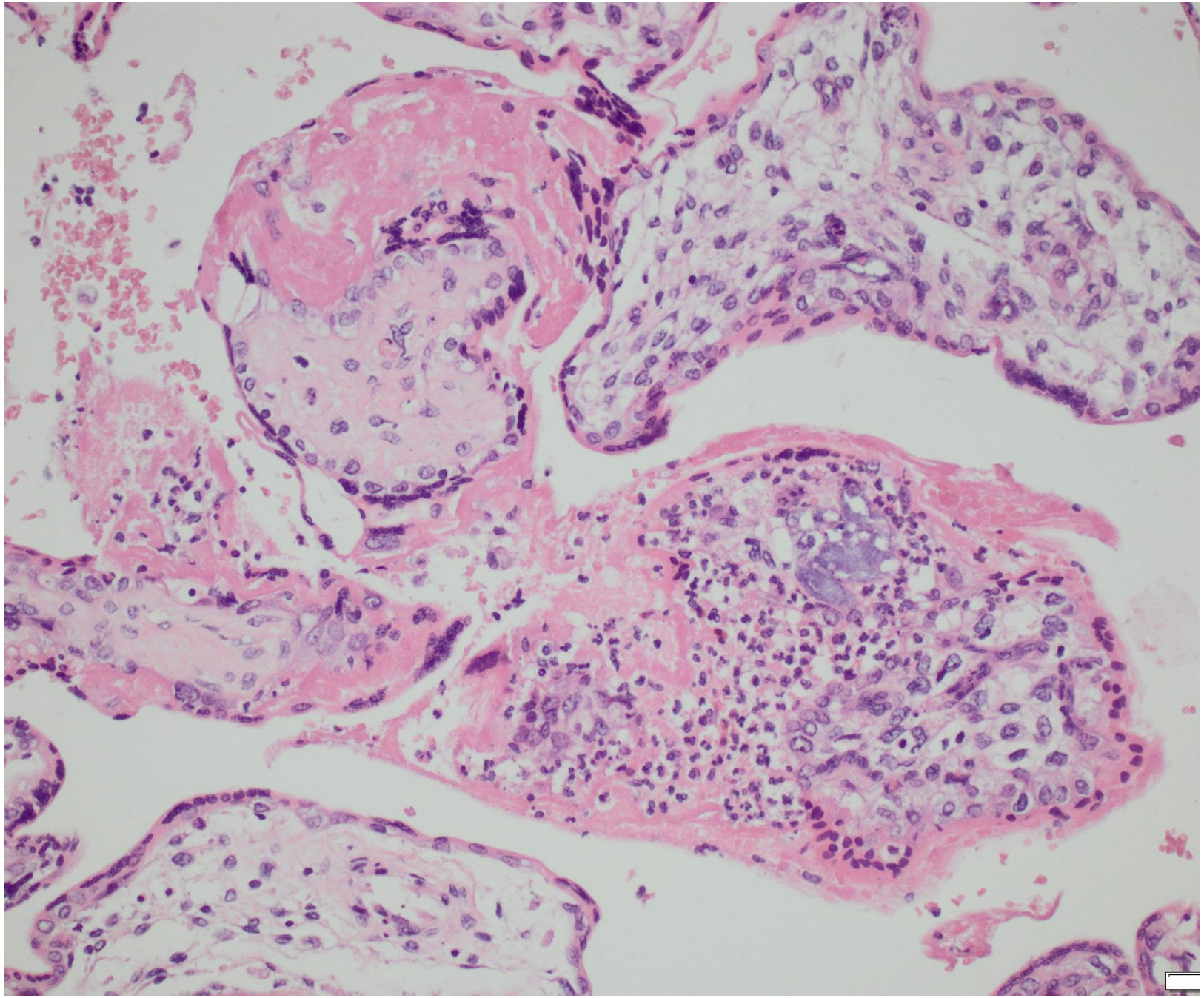

Acute villitis

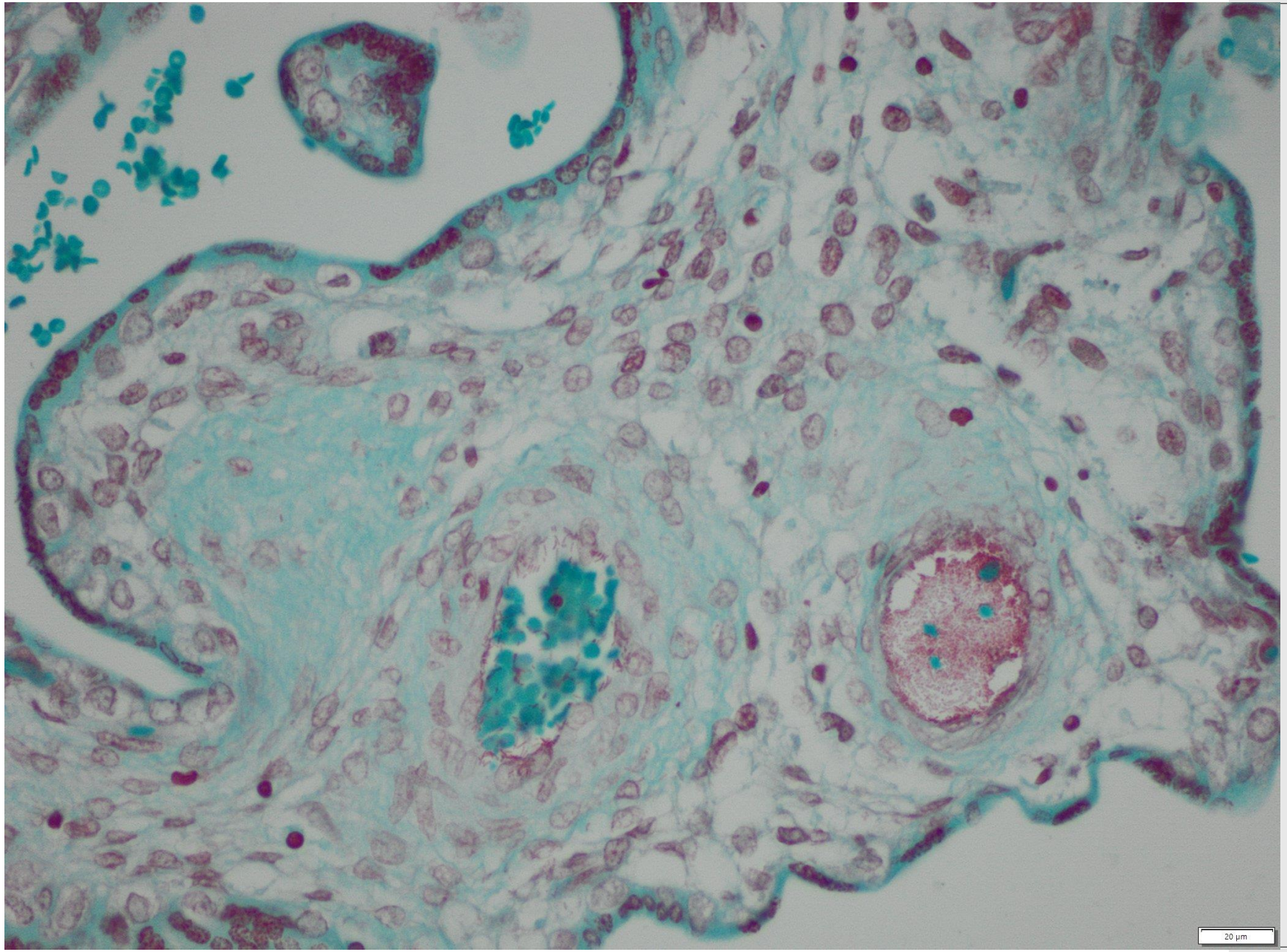

Gramkleuring

Gramnegatieve staafjes:

E-coli sepsis

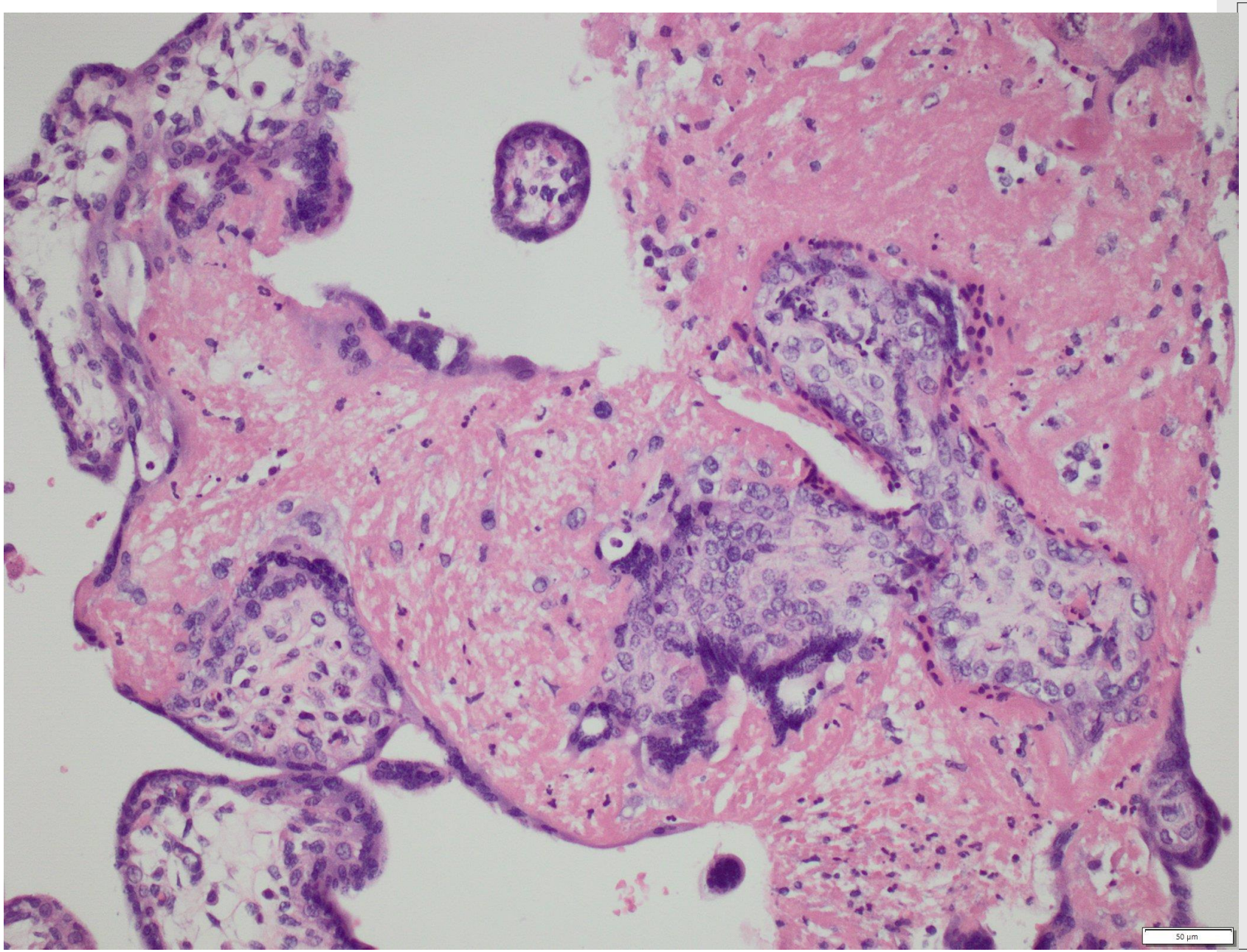

Acute intervillositis

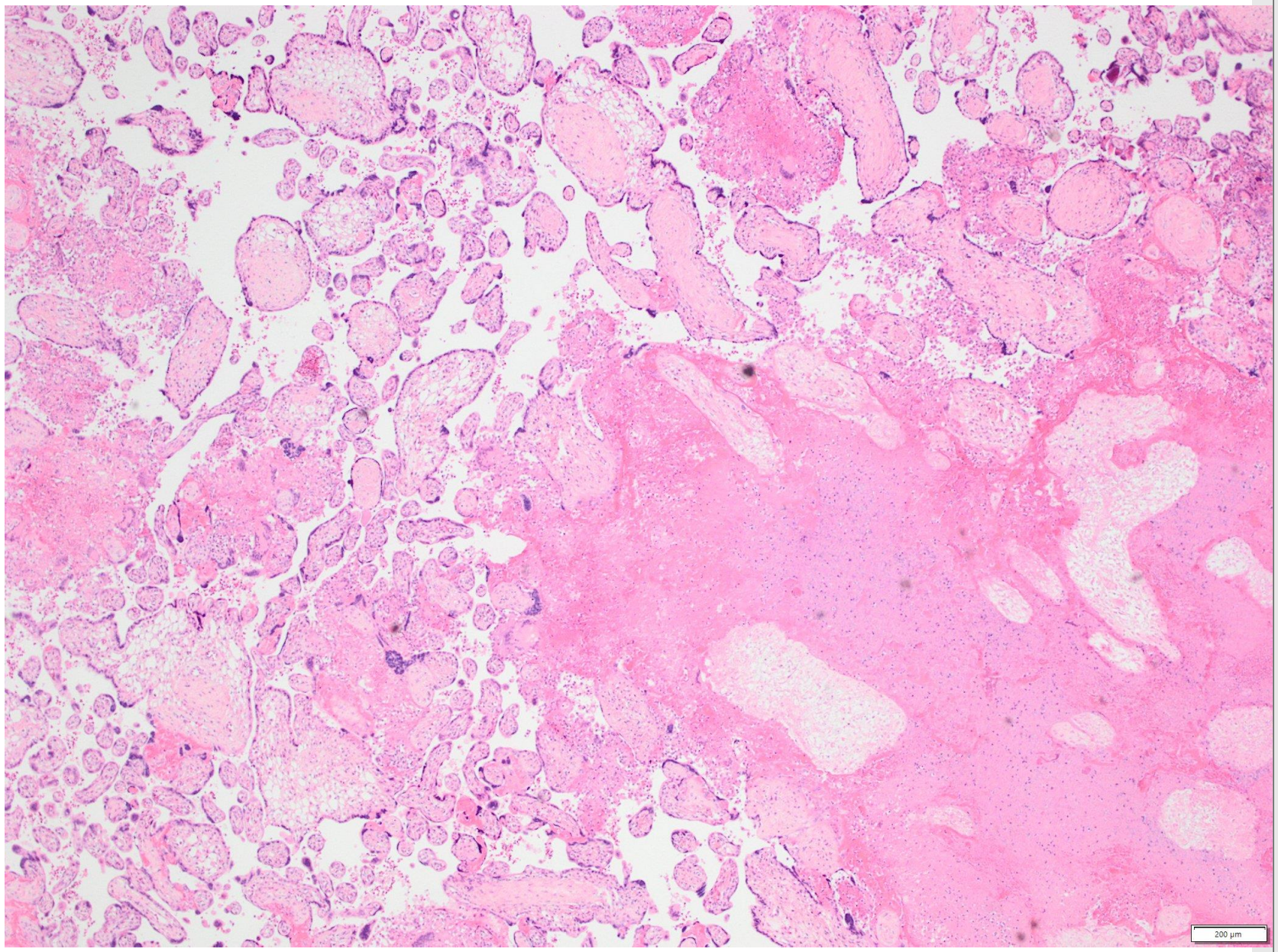

Tbc placenta

Casus van
Prof. Dr. Koen Van de Vijver

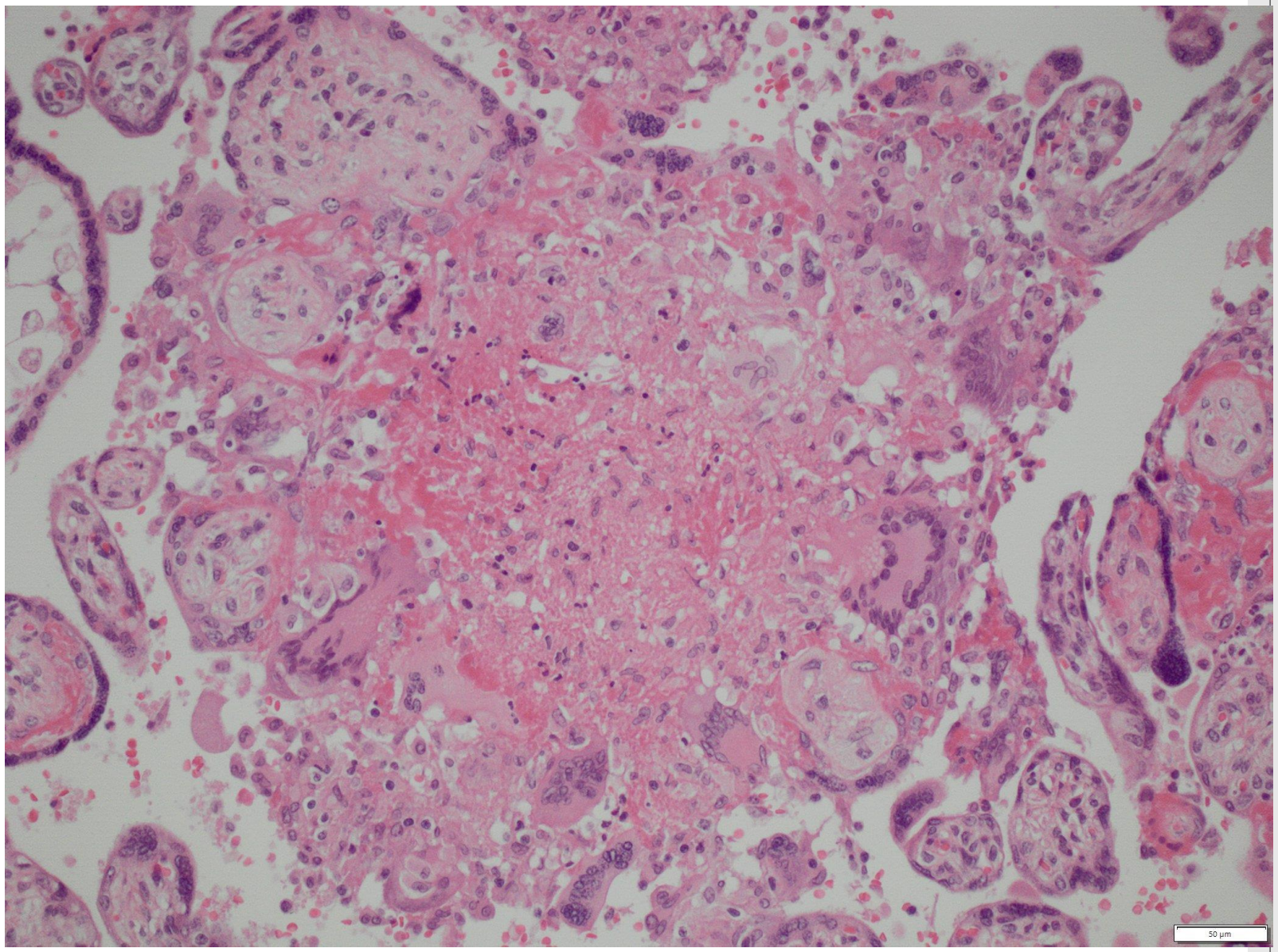

Tbc placenta

- Meest frequent door Mycobacterium bovis: drinken van niet gepasteuriseerde melk van besmette koe
- Hier: Mycobacterium tuberculosis

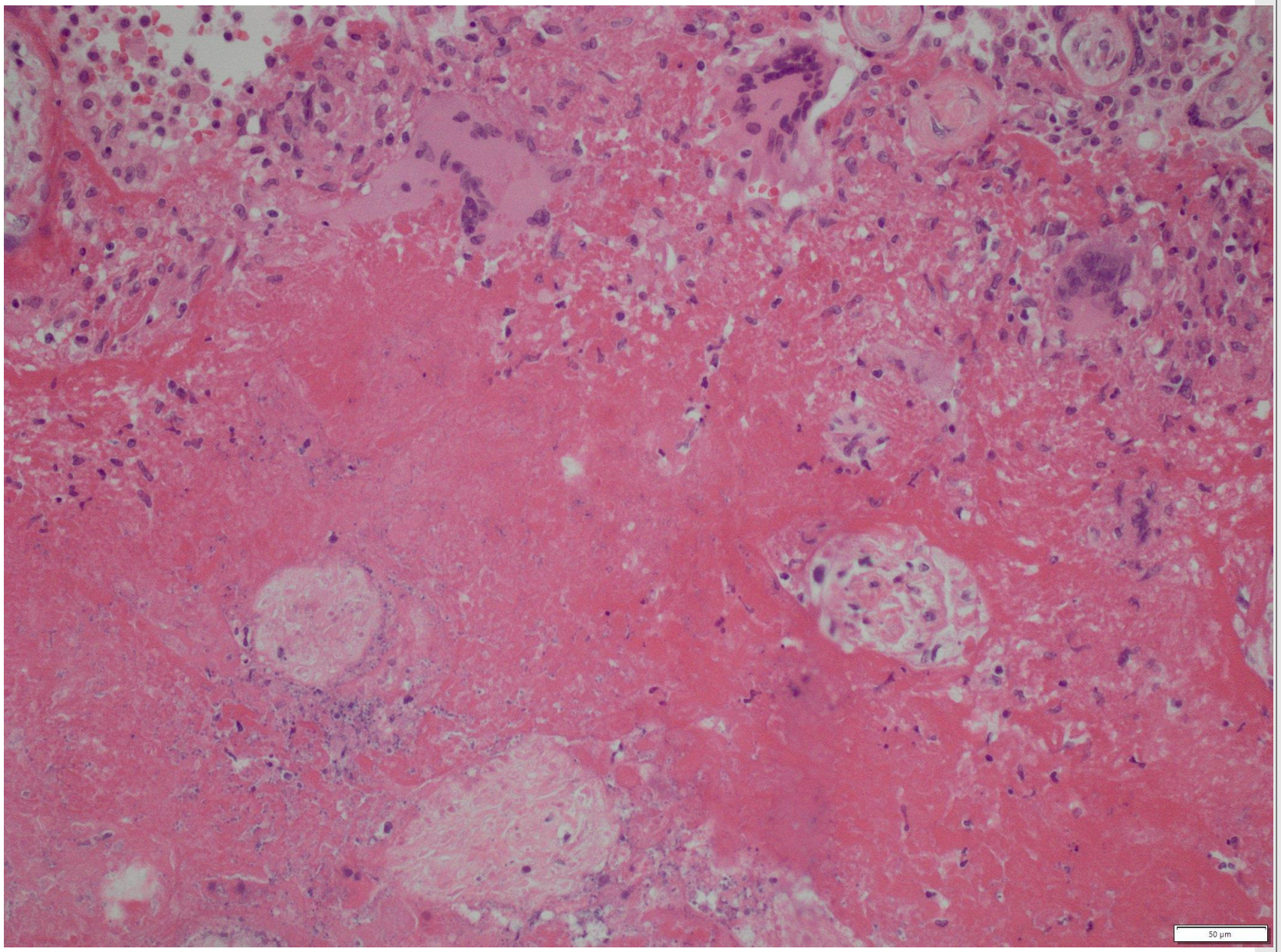

Tbc placenta

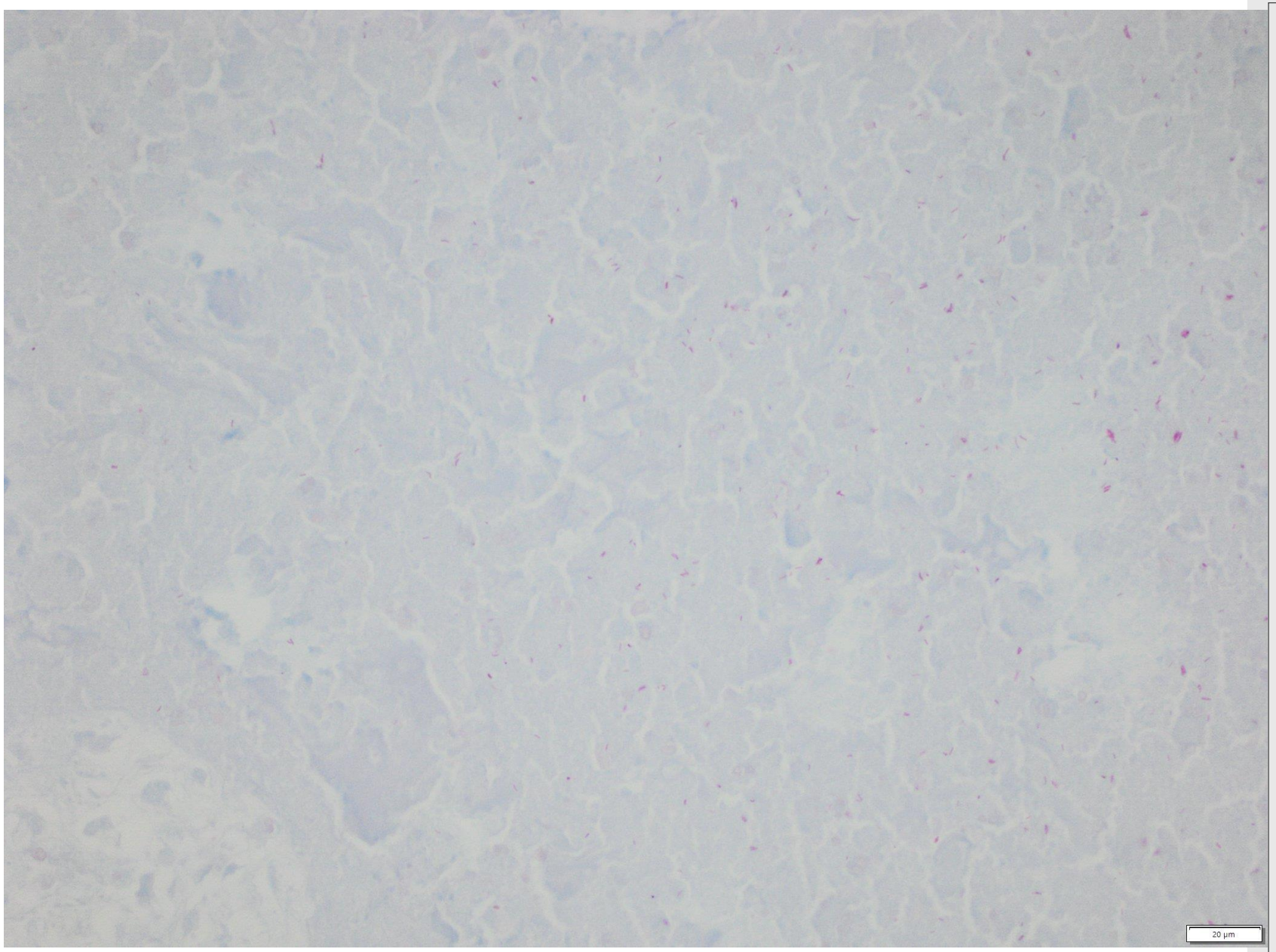

Tbc placenta Ziehl-Neelsen

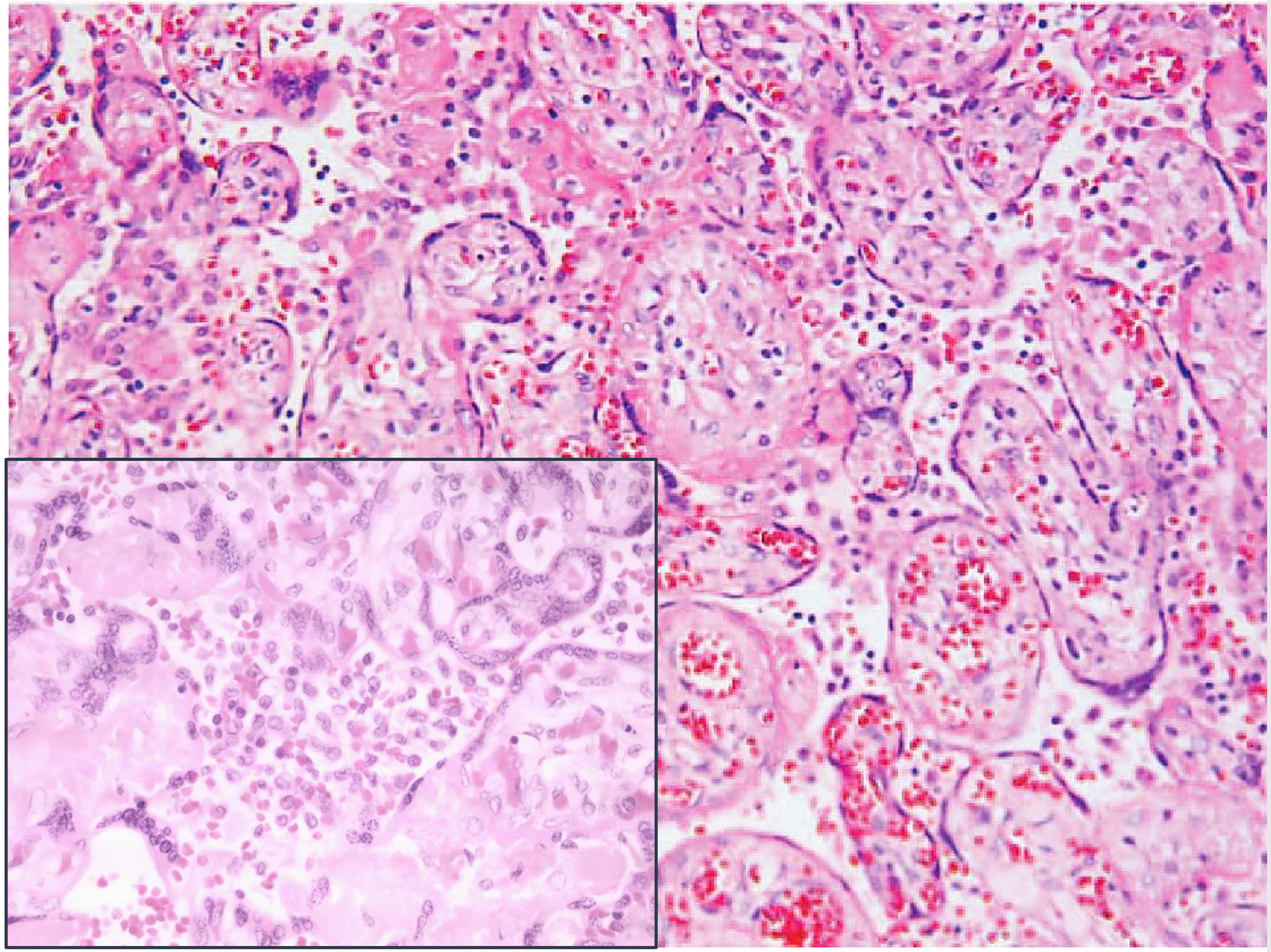

Massive chronische intervillositis

- Macrofagen (CD68+) en fibrine intervilleus
- Meest frequent in 1e zwangerschapstrimester (=zeldzame oorzaak van 1e trimester miskraam zonder chromosoomafwijking)
- Meest kans op recidief en op foetale dood van alle placentapathologieën
- Onvoorspelbaar: normale zwangerschap kan tussen miskramen
- Materneel alfafoetoproteine kan gestegen zijn
- Maternele gastheer tegen foetale allograft rejectie

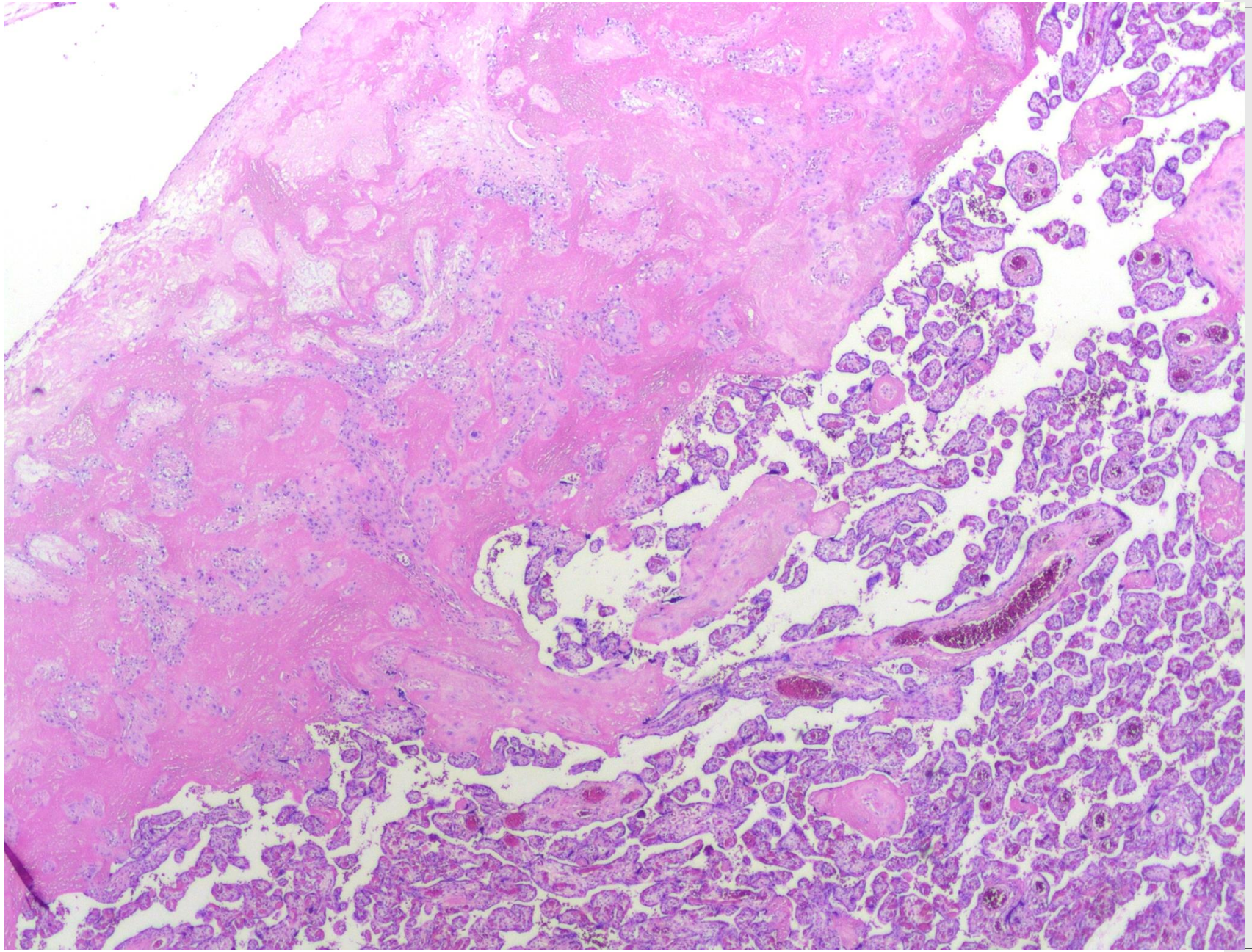

“Maternal floor infarction”

- Maternele gastheer tegen foetale allograft rejectie
- Basale confluente zone van perivilleuze fibrinedepositie, meer dan 4 villi boven elkaar → maternele ruimte wordt bevloeid door bloed van aanpalende normale zones
- Hoog risico op foetale groeiretardatie/dood
- Hoge recidiefkans in volgende zwangerschap
- Materneel alfafoetoproteine kan gestegen zijn = follow-up parameter

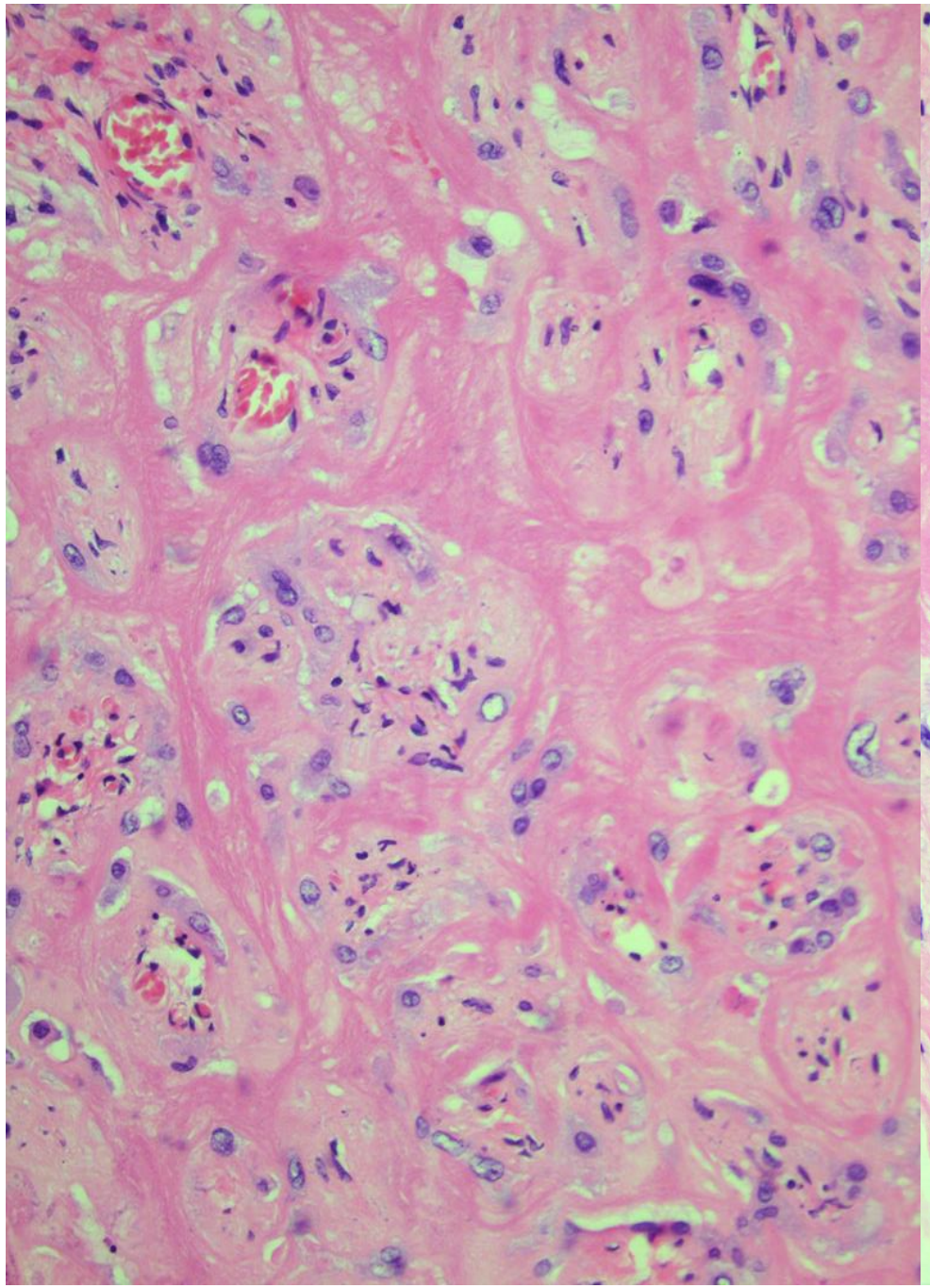

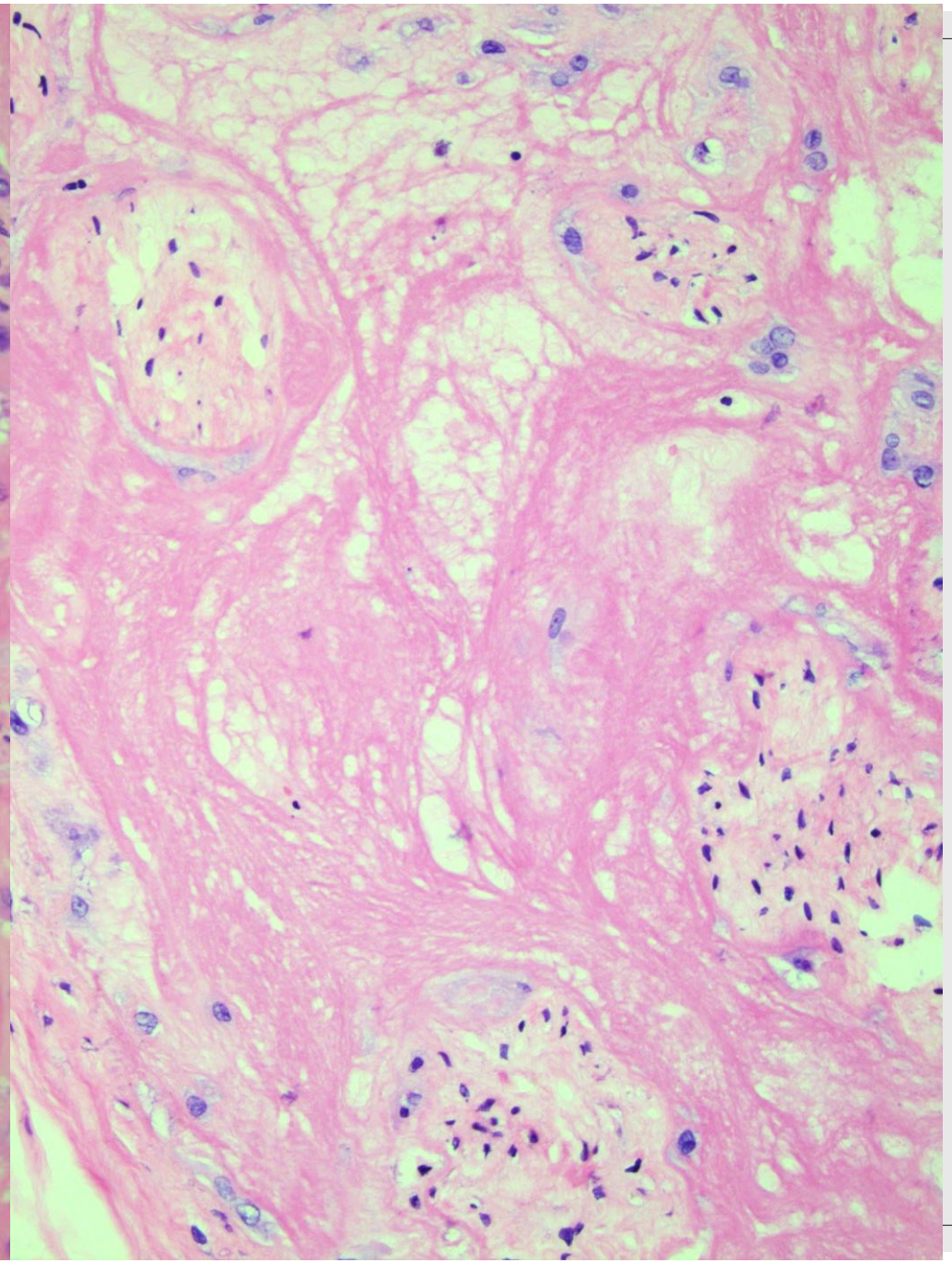

Perivilleuze fibrine-depositie

Trofoblast differentieert naar infiltrerende intermediaire trofoblast

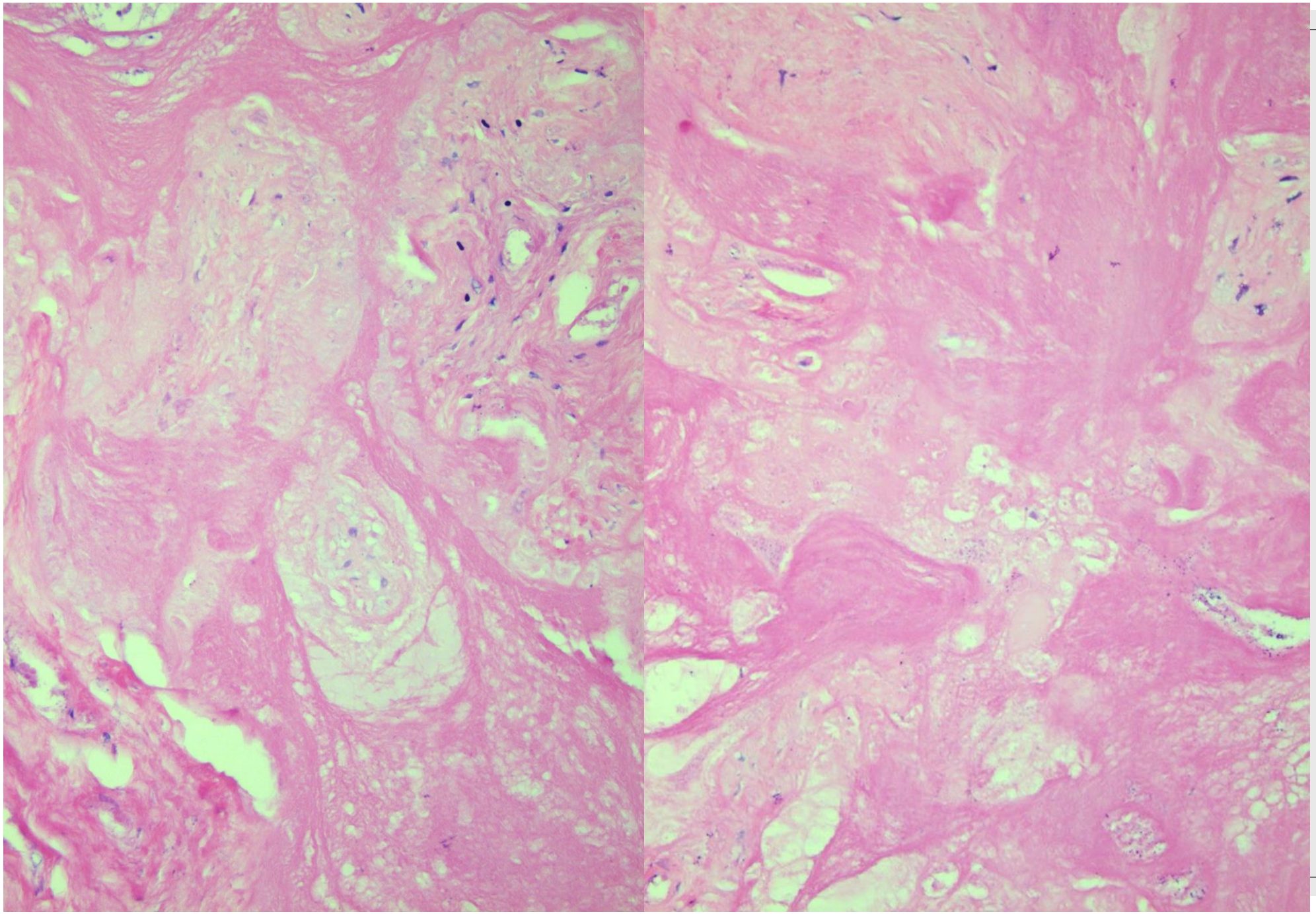

Secundaire vlokfibrose

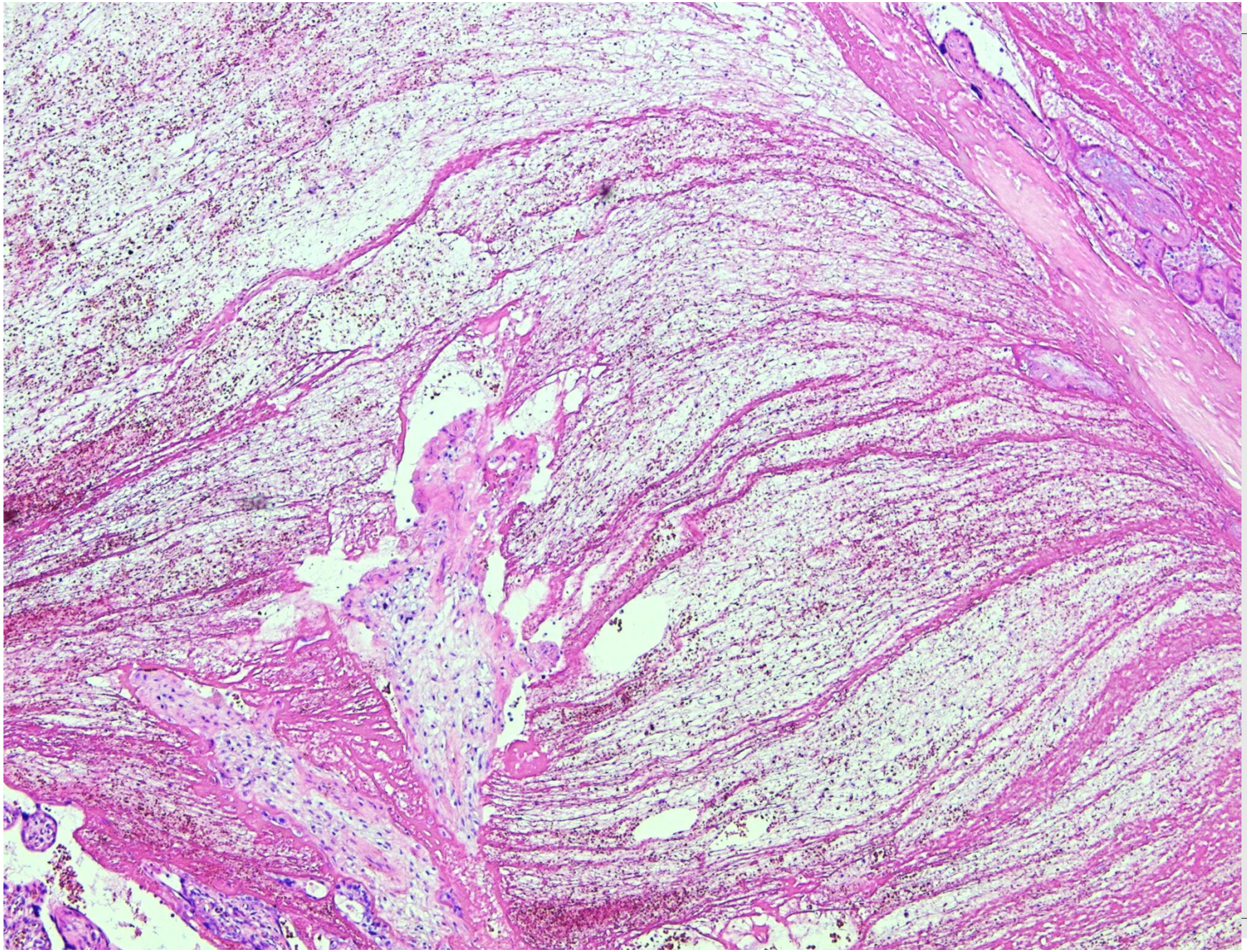

gelaagde
intervilleuze
fibrinethrombus

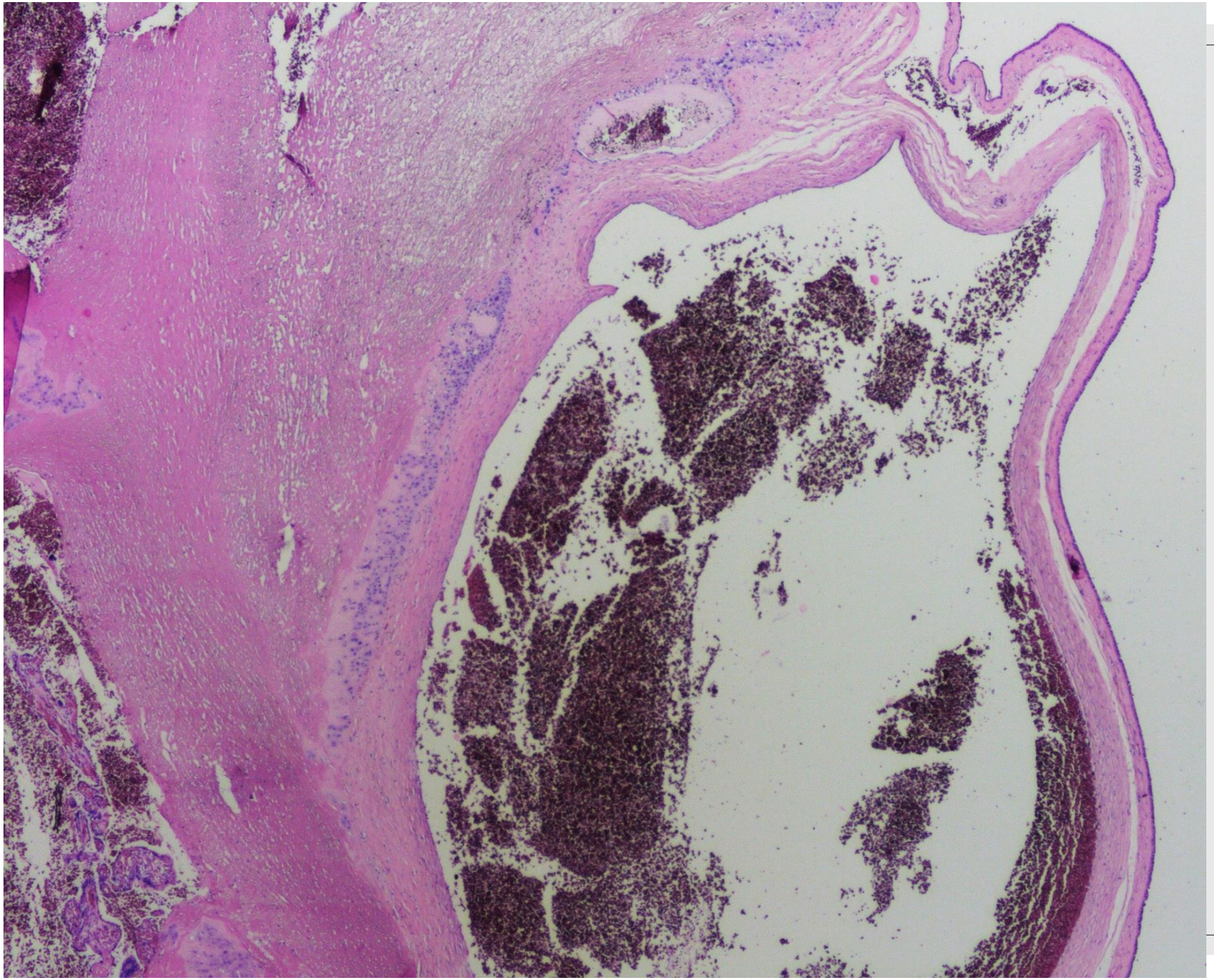

Subchoriale gelaagde fibrinethrombus

- Stoort flow in materneel bloedcompartiment
- Hier: vasculaire ectasie = bloedvat met 4x kaliber van gelijkaardige bloedvaten in de buurt
- Wijst op FVM: foetale vasculaire malperfusie
- Oorzaak en betekenis onduidelijk: navelstrengcompressie? Gestoorde flow door onderliggende fibrinethrombus?

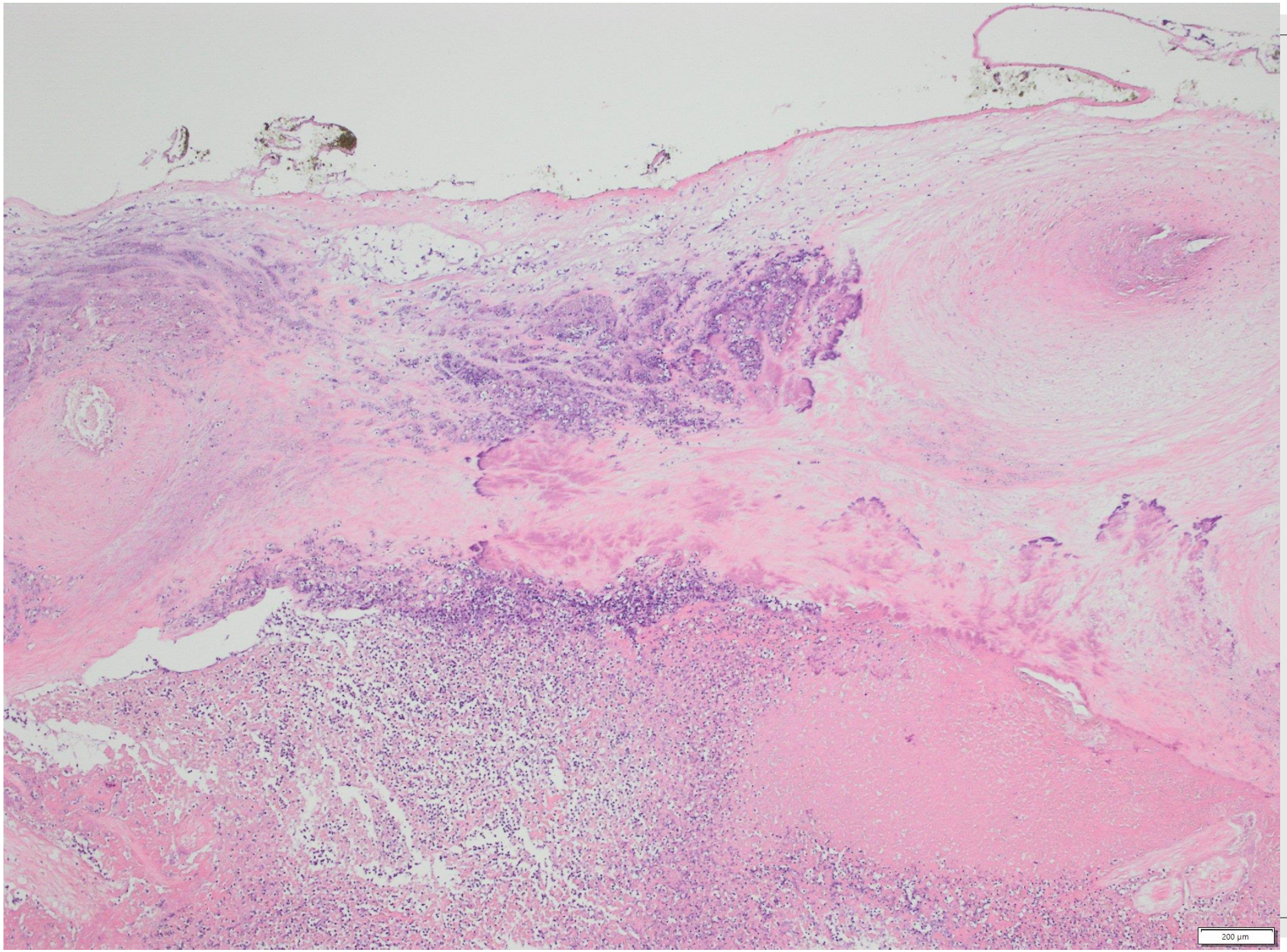

Necrotisch amnion en chorion post laser therapie voor vasculaire anastomosen in monochoriale tweeling-zwangerschap

Biamniotisch monochoriaal septum

1 chorion → bloedvaten lopen door onder de insertie van het septum

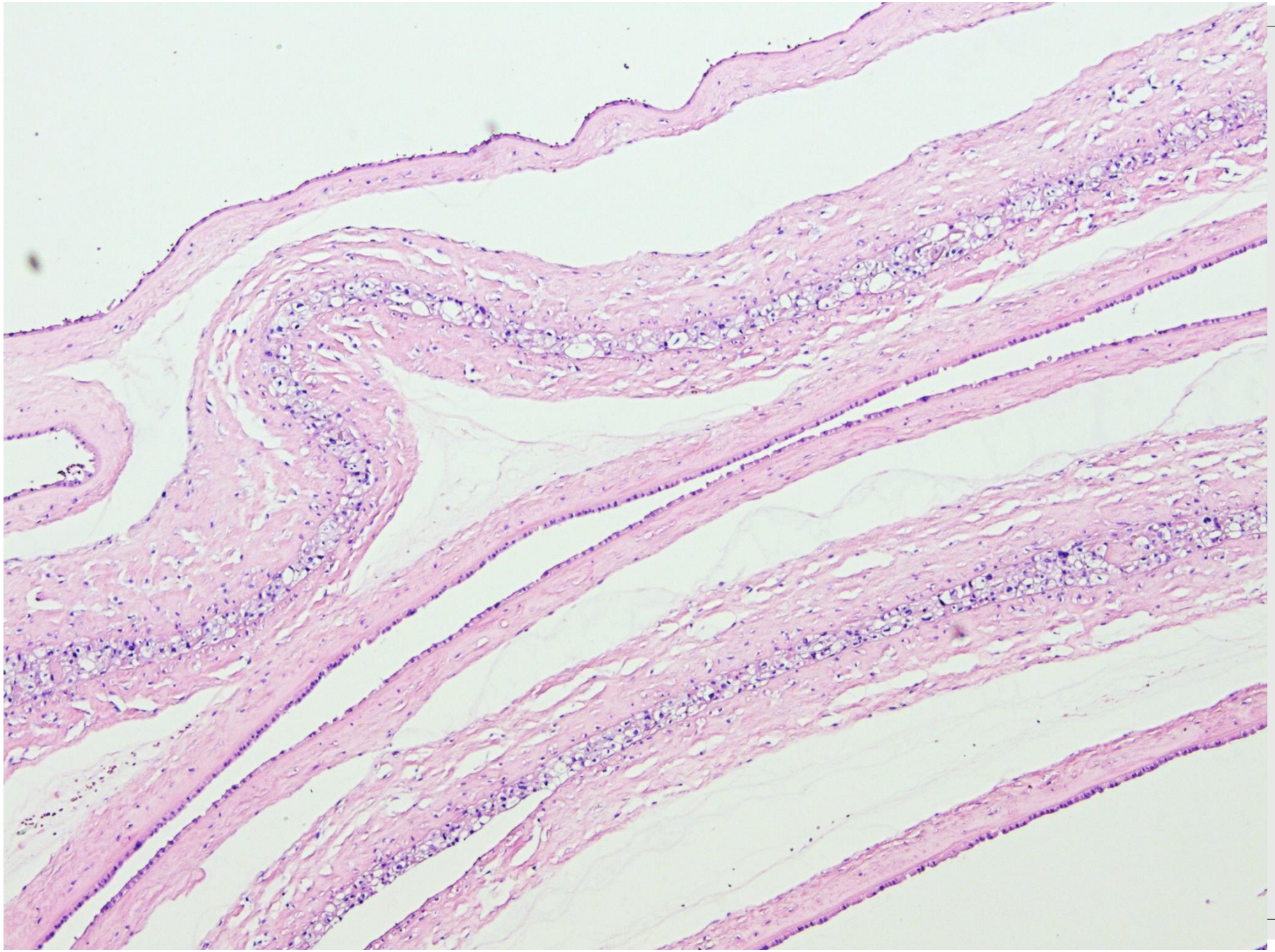

Biamniotisch bichoriaal septum

2 chorions → bloedvaten stoppen aan de insertie van het septum, geen anastomoses

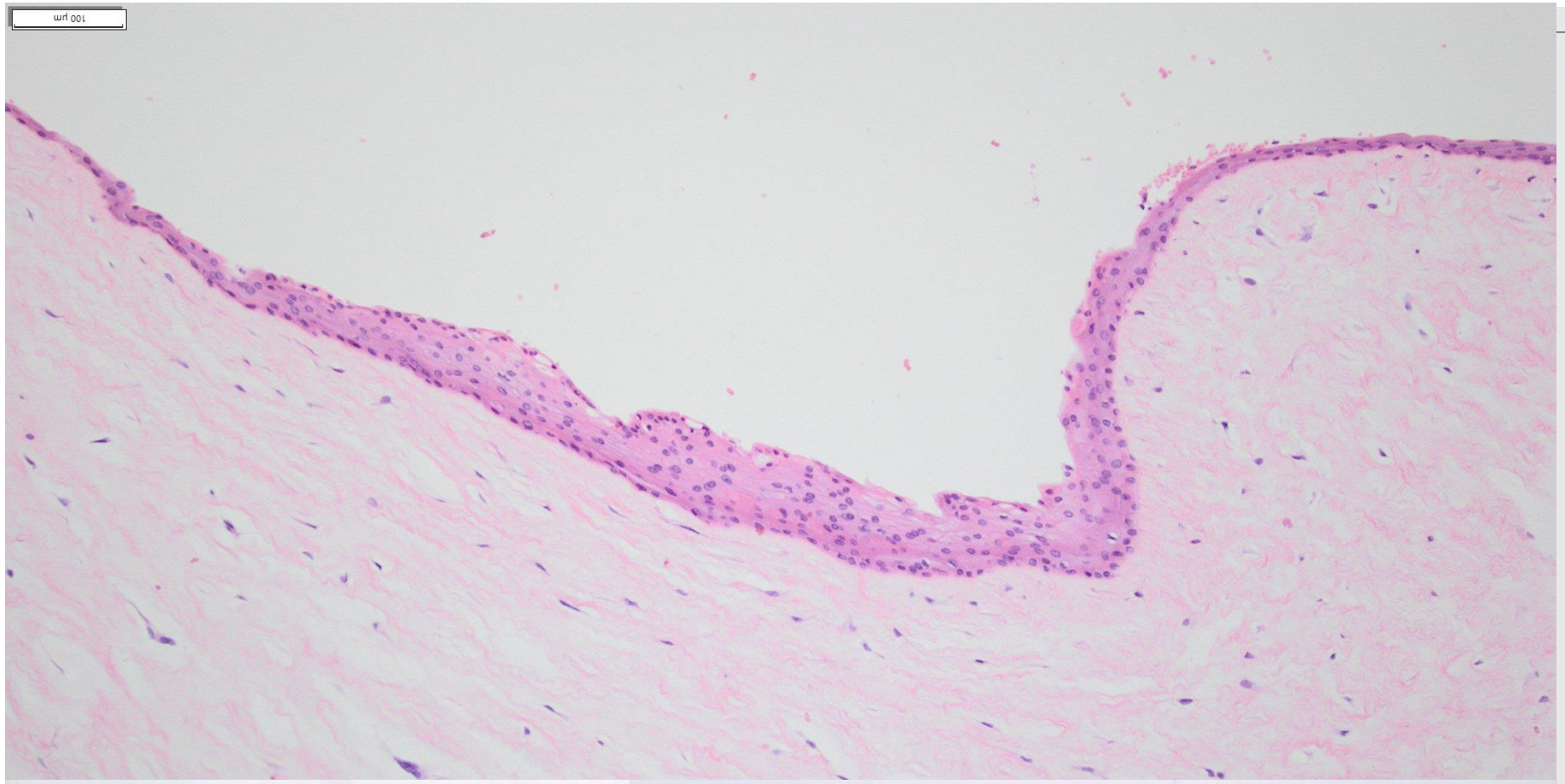

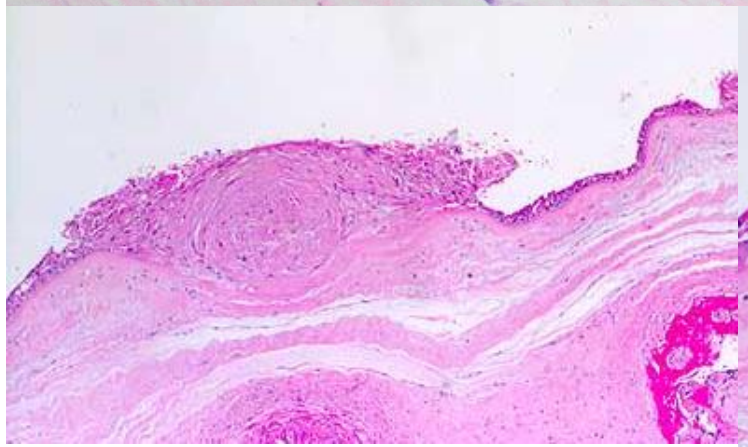

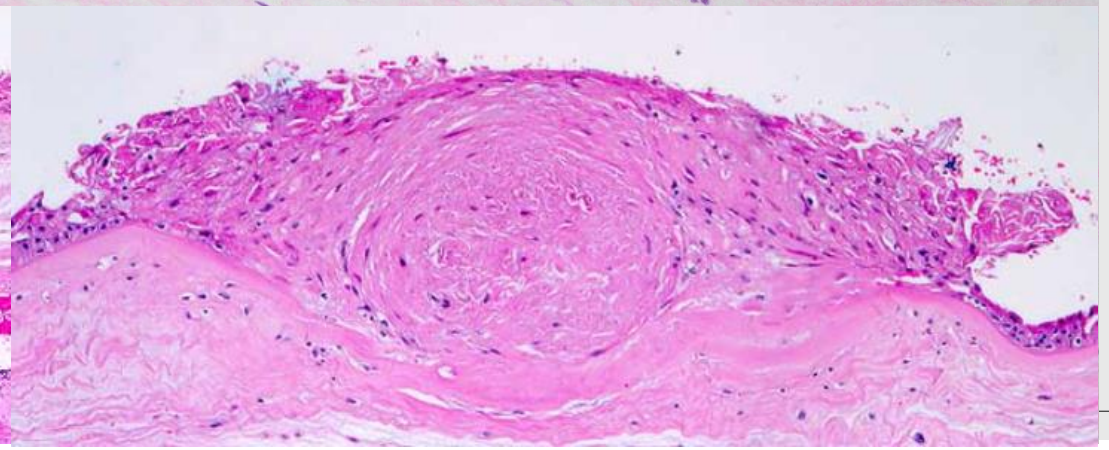

Squameuze metaplasie van het amnion epitheel

- Wrijving
- Insertie navelstreng
- D.D. **amnion nodosum** = hoopjes fibrine en squamae (huidschilfers van foetus) wijzend op oligo-/ anhydramnion

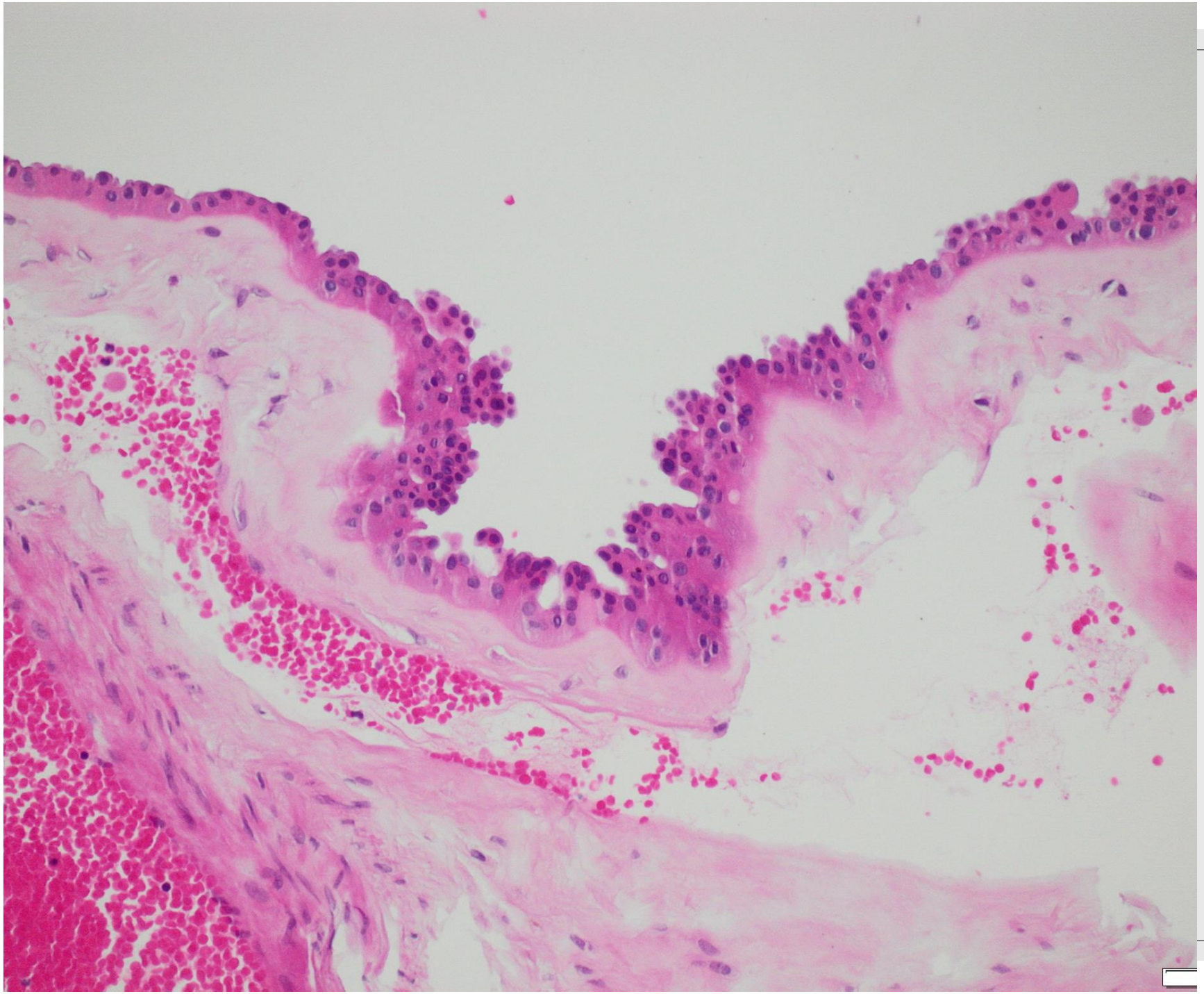

Columnaire metaplasie van het amnionepitheel

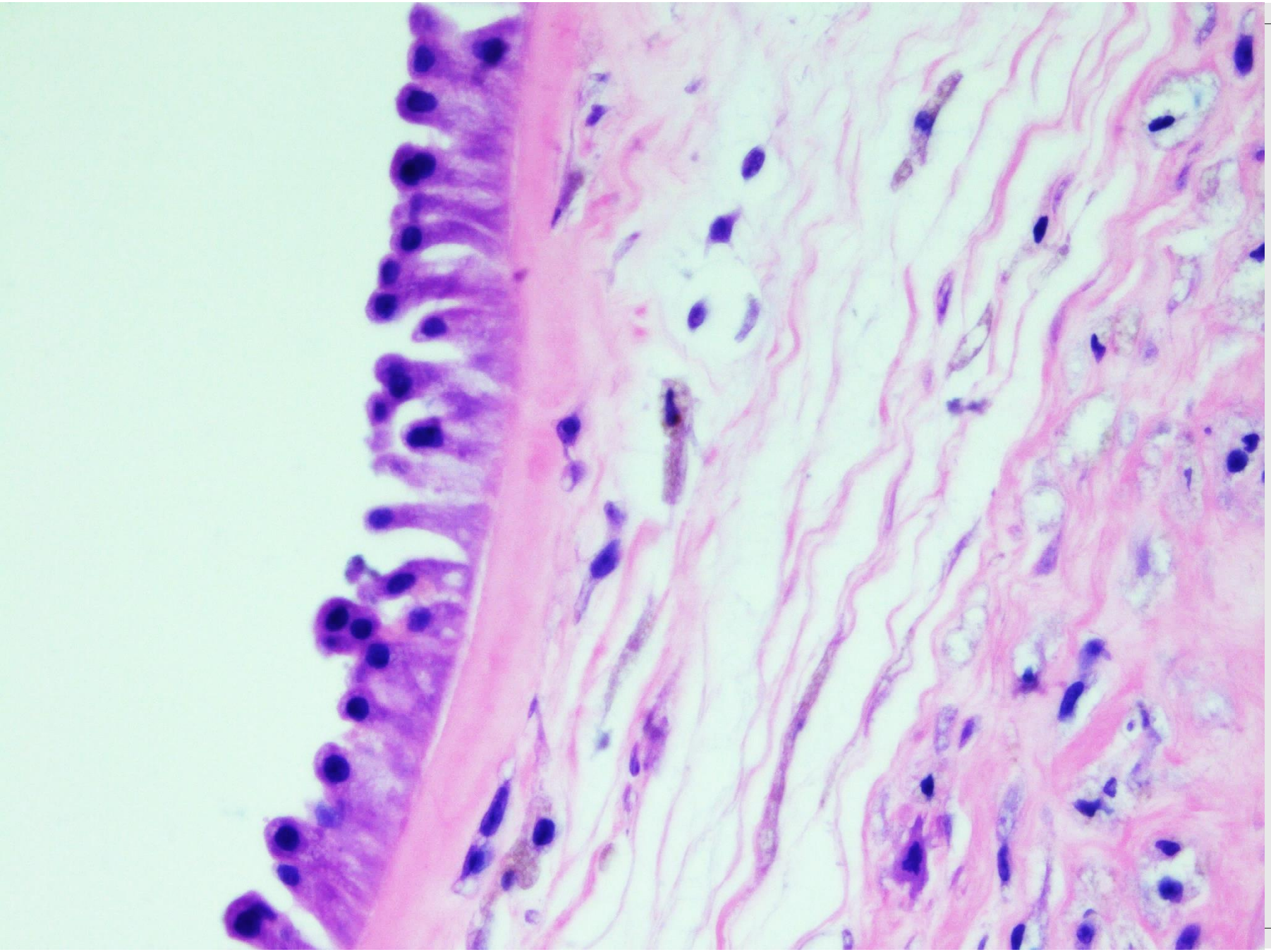

Columnaire metaplasie/ pseudo-stratificatie

Zoek meconiummacrofagen!

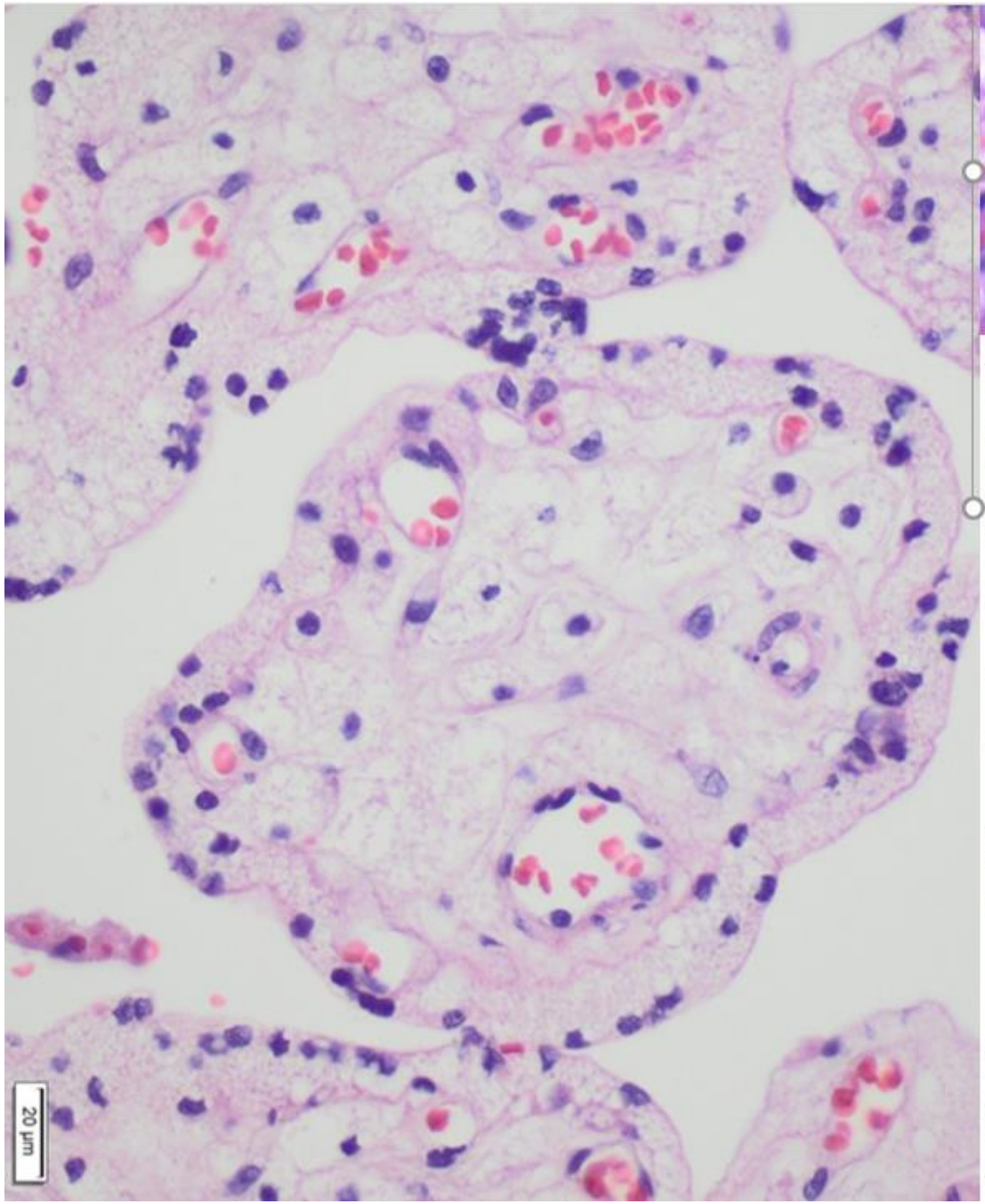

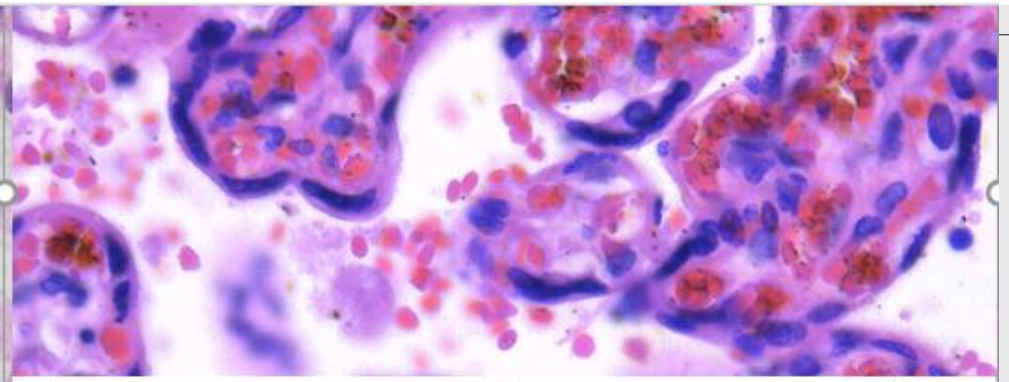

7

Disease	Findings	Reference
Glycogen storage type II Pompe's disease	Vacuoles full of glycogen in EM in stroma, endothelium, cytotrophoblast, lysosomes	Bendon and Hug, 1985 Jones et al., 1990 Roberts et al., 1991
Mucopolysaccharidosis Hurler's disease	Vacuolization of fibroblasts and syncytium	Jones et al., 1990
Sanfilippo's disease	Vacuolated syncytium, absent heparin-N-sulfatase in CVS	Jones et al., 1990 Kleijer et al., 1986
Morquio's disease, type IV	Edema of villi	Applegarth et al., 1987
β-glucuronidase deficiency	Hofbauer cell vacuolization, hydrops	Nelson et al., 1993
Sialic acid storage Salla's disease	Vacuolated syncytium and Hofbauer cells with amorphous and fibrillar material, vacuolated extravillous trophoblast and amnionic epithelium	Gillan et al., 1984 Jauniaux et al., 1987 Jones et al., 1990 Roberts et al., 1991
Gaucher's disease	Hydrops	Ginsburg and Groll, 1973 Gillan et al., 1984 Rice et al., 1984 Sidransky and Ginns, 1993
Sphingomyelin storage Niemann-Pick's disease types A and C; Type B may have inclusions	Vacuolization and laminated inclusions (myelin bodies) in syncytium, stroma, Hofbauer cells, umbilical cord fibrocytes, hydrops	Sarrut and Belamich, 1983 Vanier et al., 1989 Meizner et al., 1990 Schoenfeld et al., 1985
Gangliosidoses GM 2, gangliosidosis type I, Tay-Sachs' disease	Vacuolated trophoblast and Hofbauer cells, amnion Absent hexosaminidase in CVS	Lowden et al., 1973 Grebner et al., 1983 Roberts, 1991 Beinrschke and Kaufmann, 1995
Type II Sandhoff's disease	Multiple parallel arrays in lysosomes of stroma, vacuolated syncytium, myelin bodies	Fox, 1997
Fabry's disease Glycosphingolipidosis	Lamellar lysosomal inclusions in decidual cells, chorionic cells normal, in heterozygous carrier	Popli et al., 1990
Mucolipidoses Type I Sialidosis	Vacuolated trophoblast and stroma, normal amnion	Riches and Smuckler, 1983 Laver et al., 1983 Stevenson et al., 1983 Gillan et al., 1984 Baldwin et al., 1985 Mahmood and Haleem, 1989 Bouvier and Maire, 1997
Type II I-cell disease	Vacuolated syncytium, vacuolated Hofbauer and X cells Occasional myelin figures in EM	Powell et al., 1976 Rapola and Aula, 1977 Sarrut and Belamich, 1983
Type IV Galactosialidosis	Vacuolated stroma with lamellar inclusions of endothelium Vacuolated trophoblast and stroma, hydrops	Sekeles et al., 1978 Scully, 1997
Neuronal ceroid lipofuscinosis	Vacuoles in syncytium, amnion, endothelium with "fingerprint" inclusions	Rapola et al., 1988 Conradi et al., 1989

CVS, chorionic villus sampling; EM, electron microscopy.

Meta-bole ziekten

Galacto-sialidose

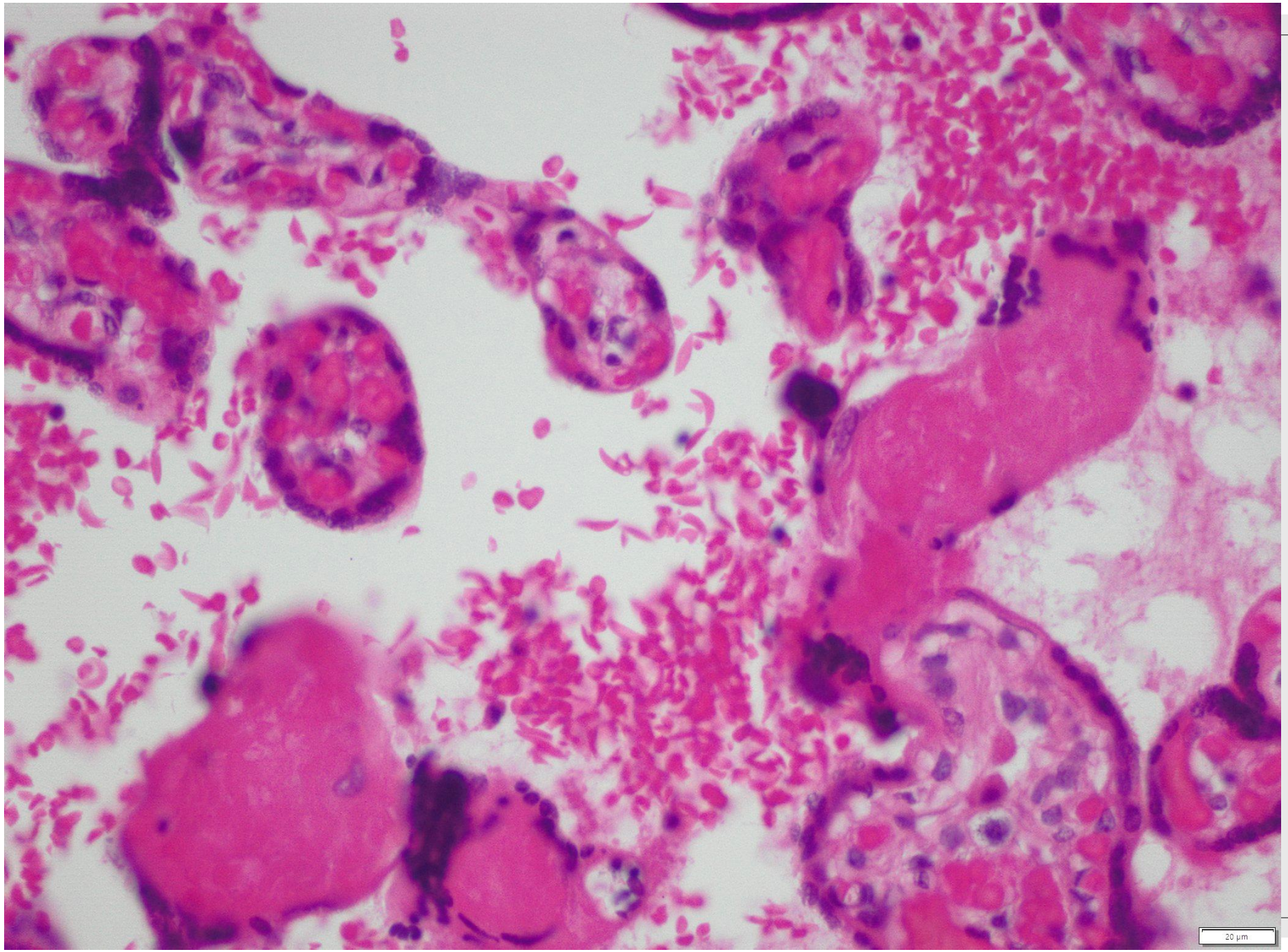

Moeder met sikkelcel-anemie

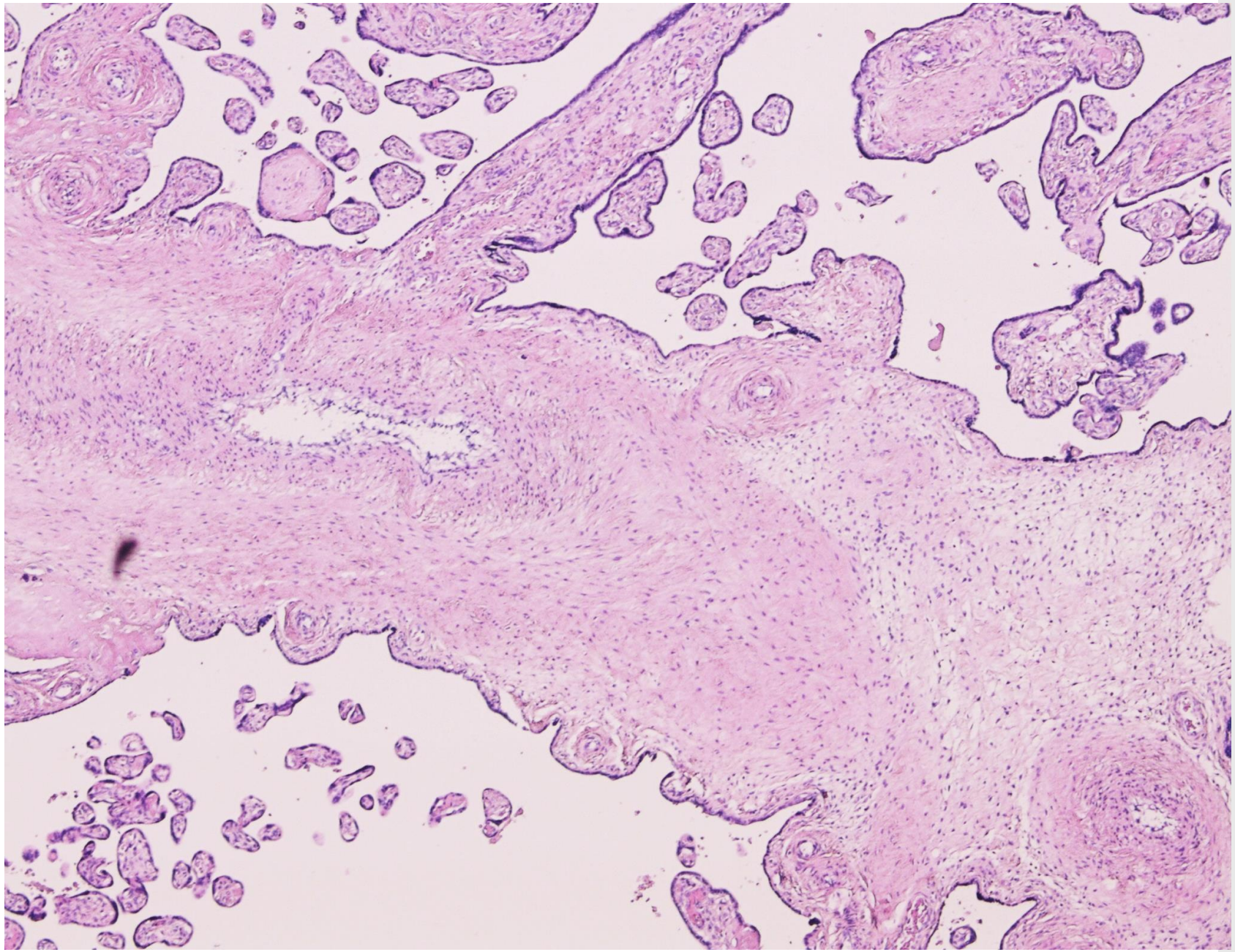

Placentaire mesenchymale dysplasie

Grote vlokken

Dikwandige bloedvaten

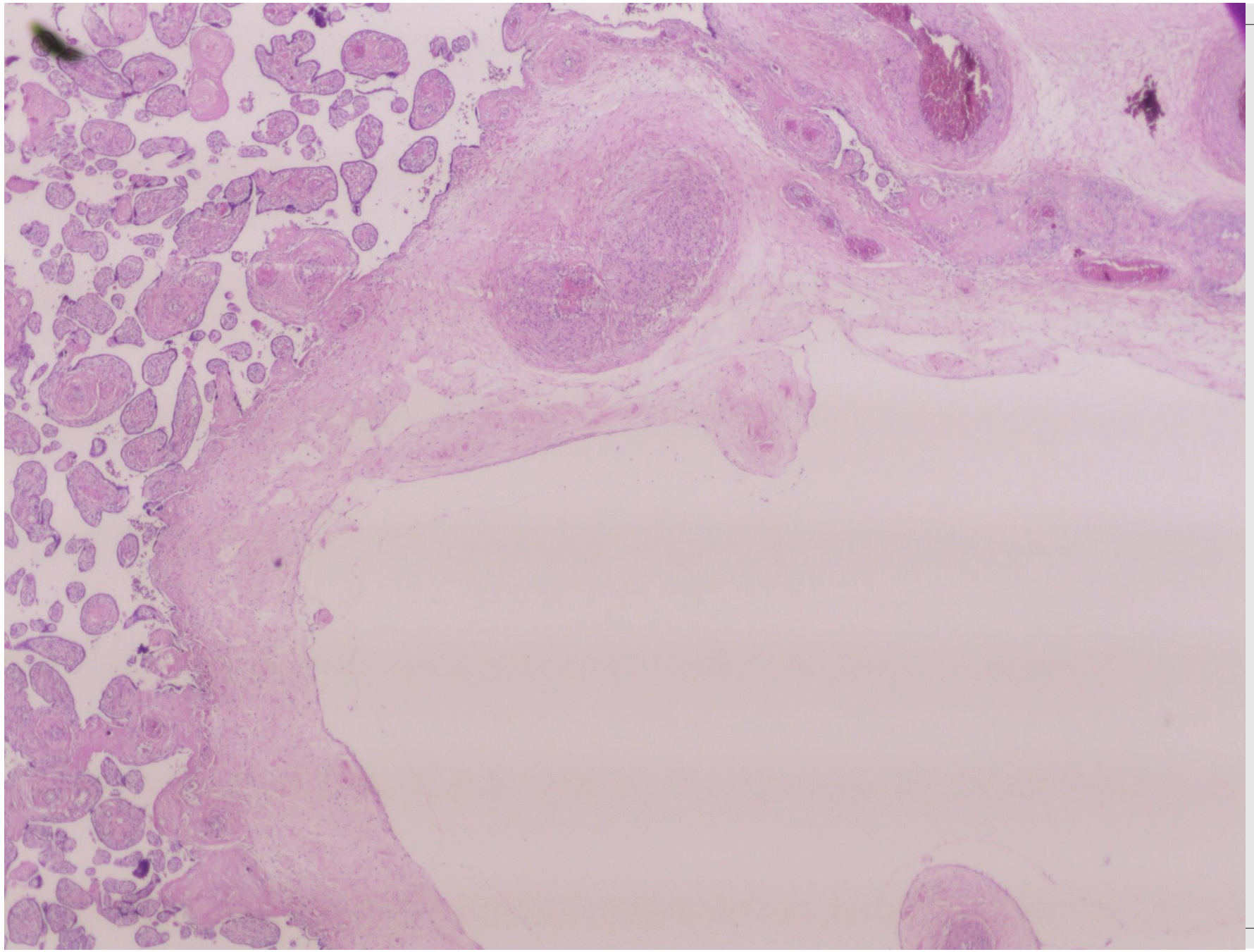

Placentaire mesenchymale dysplasie

Grote vlok met cisternevorming

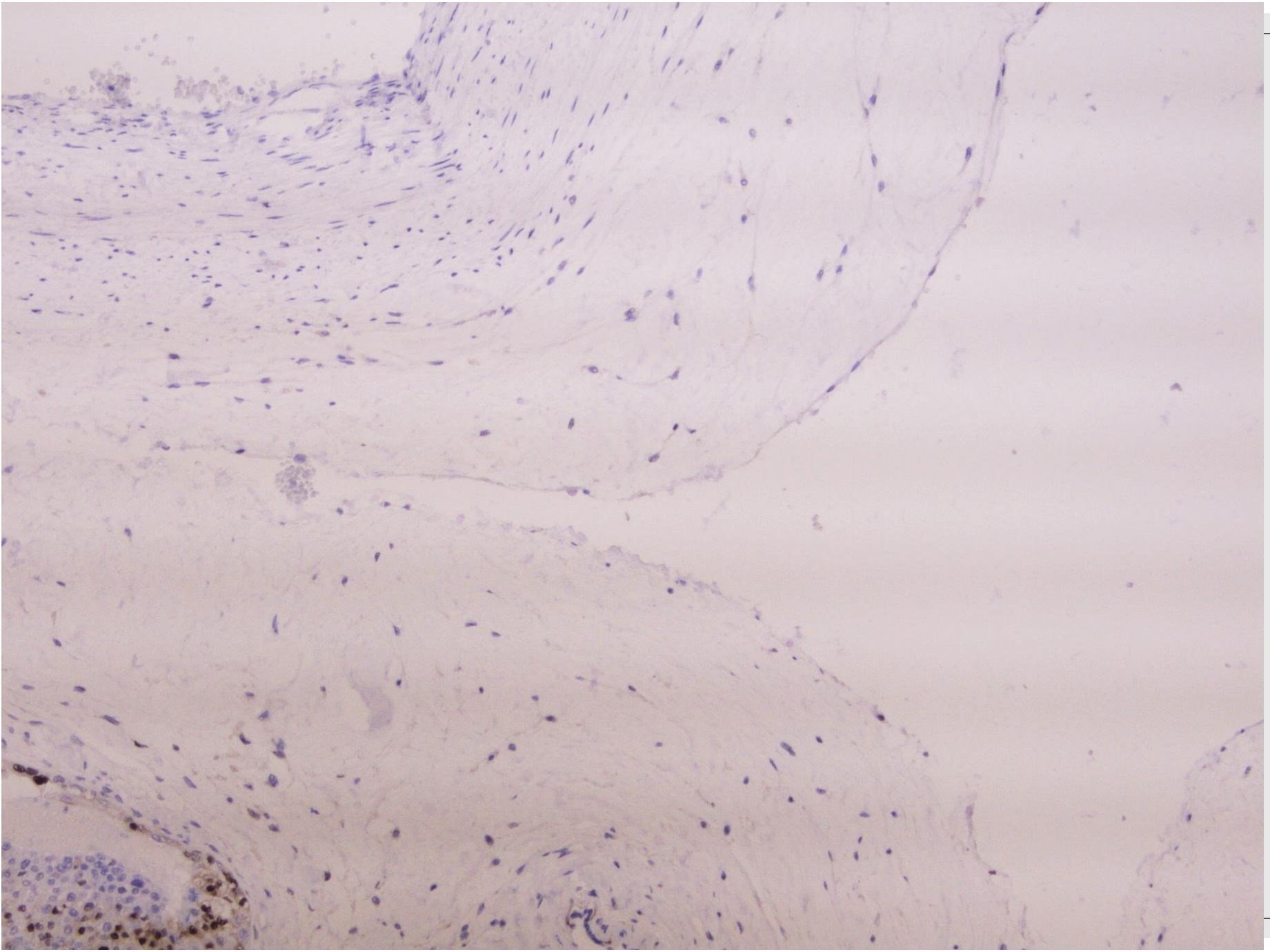

Placentaire mesenchymale dysplasie

P57 afwezig in het stroma, doch aanwezig in trofoblast DD mola

Foetus kan normaal zijn, doch vaak associatie met IUGR, IUVD en Beckwith-Wiedemann syndroom (macrosomie, macroglossie, omfalocoele, visceromegalie…)