FINE NEEDLE ASPIRATION BIOPSY OF THE PANCREAS

METHODS OF SAMPLING

- Endoscopic retrograde cholangiopancreatography (ERCP):
  - **Brush cytology**
    - Biliary duct
    - Pancreatic duct
- Percutaneous transhepatic cholangiography (PTC)
  - < performed because of their interventional capabilities
    - < stenting of the ductal system
- Percutaneous FNA under image guidance
  - < Transabdominal ultrasound (US)
  - < Computed tomography (CT)

ENDOSCOPIC ULTRASOUND-FINE NEEDLE ASPIRATION EUS-FNA

Brush cytology (ERCP)

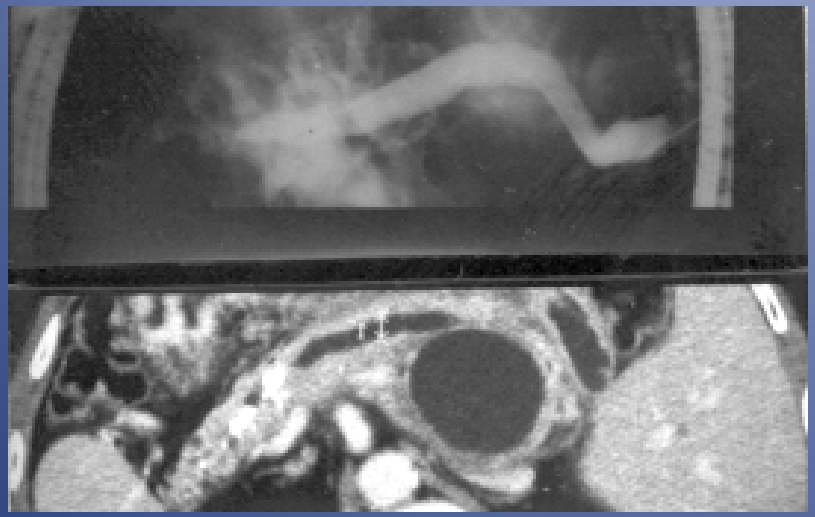

ERCP PERFORMANCE

- Sensitivities for the diagnosis of pancreatic neoplasia between 45% and 70%

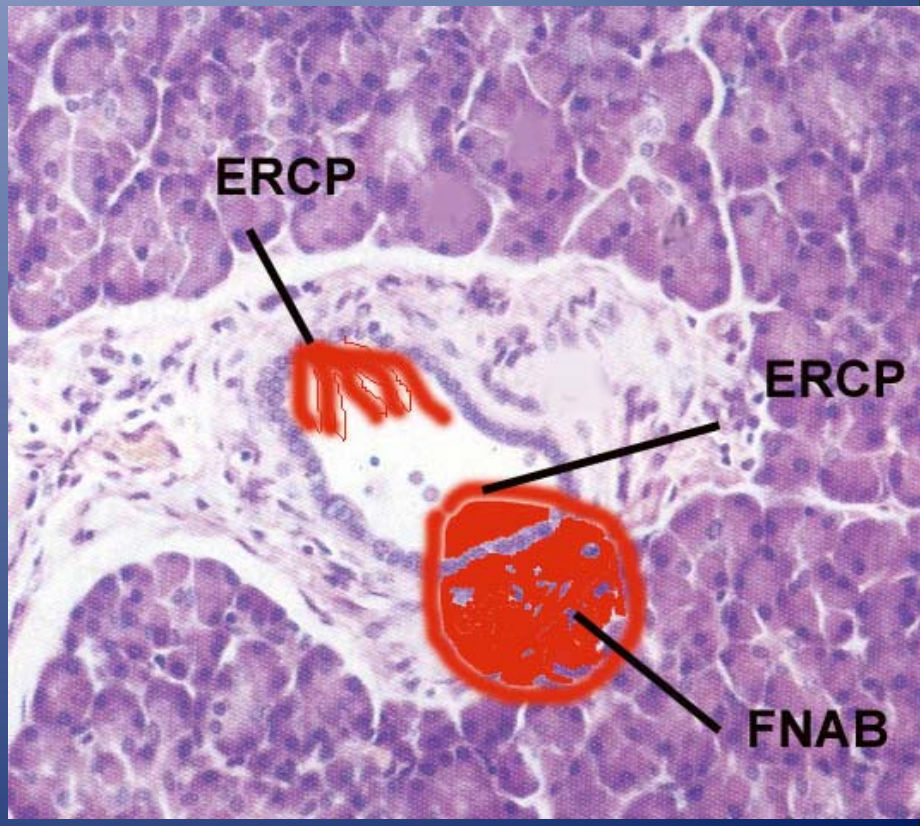

- Sampling improvement
- Diagnosis improvement
  - Thin layer slides

DIFFERENTIAL DIAGNOSIS

	ERCP	FNAB
Benign Pathologies	Pancreatitis Cholangitis IPMN	Pancreatitis Pseudocyst Abcess Cystadenoma Endocrine Hyperplasia
Malignant Pathologies	Cholangiocarcinoma Ductal pancreatic Adenocarcinoma IPMN	Ductal pancreatic Adenocarcinoma Endocrine Tumour Cystadenocarcinoma Lymphoma Metastasis

< Percutaneous aspiration→ Ct

Sensitivities for the diagnosis of pancreatic neoplasia
85 to 95%

< EUS-FNAB

75 to 95%

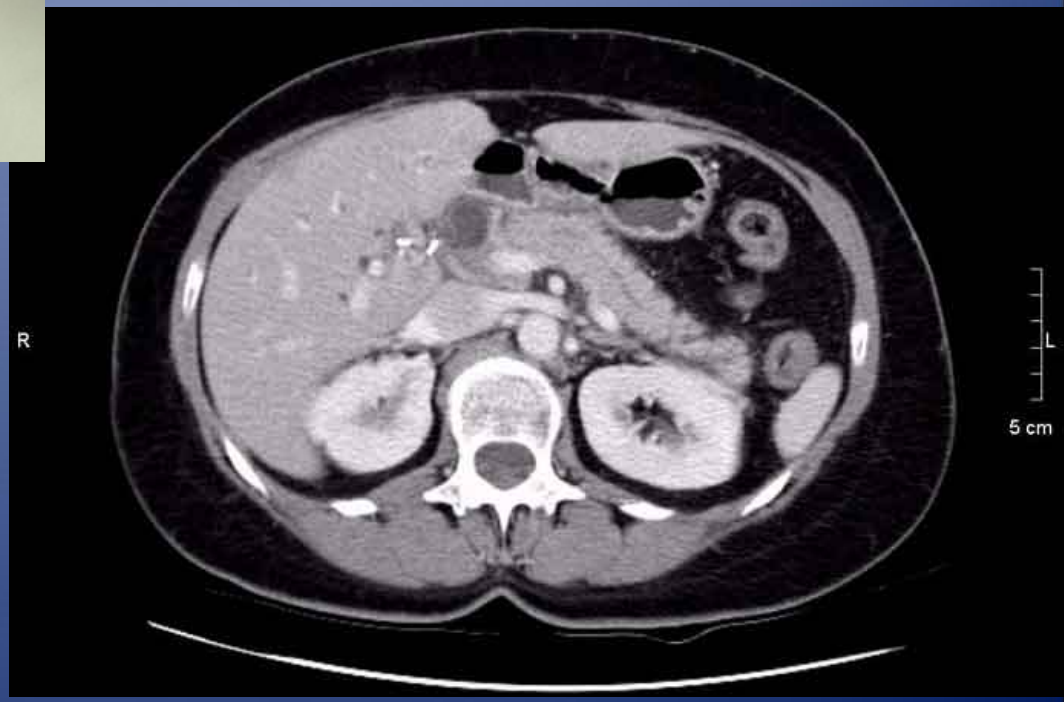

COMPLICATIONS

Percutaneous aspiration 3%	EUS-FNA 0-2%
Major Complications Haemorrhage Acute Pancreatitis Sepsis < cystic lesion	**Major Complications** EUS complication perforation associated with luminal strictures Perforation Haemorrhage Sepsis < cystic lesion Acute Pancreatitis
TUMOR SEEDING ALONG NEEDLE TRACT <1%	
Minor Complications Abdominal discomfort Hematoma Vasovagal reaction	**Minor Complications** Abdominal discomfort Hematoma Vasovagal reaction

PANCREATIC EUS-FNA

- Part of a routine algorithm
  - Small lesions < 5mm
  - Proximity of the lesion
    - ↓ dissemination
  - During staging
  - No complications 0-2%

- Sensitivity: 76 - 94%
- Specificity: 100%
- False positive cases: rare
- False negative cases: 9% (4-14)
  - < Percutaneous biopsies: 20%
  - < ERCP: 30%

➔ **Suspicious cases: 5.4 - 12%**

Eloubeidi MA et al, Cancer Cytopathol 2003
Lin F et al, Cancer Cytopathol 2003
Larghi A et al, Gastrointest Endoscopy 2004
Raut CP et al, J Gastrointest Surg 2003

CONTRAINDICATIONS

- **Contraindications for upper endoscopy**
  - Absolute contraindications
    - Patient instability to cooperate
    - Severe shock
    - Respiratory distress
  - Relative contraindication
    - Coagulopathies

SAMPLE PREPARATION

⇨ ADEQUATE SAMPLES

⇨ CORRECT INTERPRETATION

CAUSES OF FALSE-NEGATIVE DIAGNOSIS

- **Sampling errors**
  - Small lesions
  - Difficult anatomic location
    - Isthmus, uncinate processus
  - Extensive fibrosis
  - Extensive necrosis
  - Excessive bleeding
  - Operator’s inexperience

CAUSES OF FALSE-NEGATIVE DIAGNOSIS

- **Obscuring factors**
  - Excessive air drying
  - Obscuring inflammation
  - Obscuring necrotic debris
  - Contamination by benign gastrointestinal epithelium

CAUSES OF FALSE-NEGATIVE DIAGNOSIS

- **Interpretative errors**
  - Under diagnosis of well-differentiated or low grade neoplasms
  - Non specific cyst fluid findings

ASSESSMENT OF SPECIMEN ADEQUACY

- « Even trained endosonographers were not able to provide a reliable assessment of pancreatic-mass FNA adequacy by using gross visual inspection of the specimen on a slide. »

- « Rapid on-site cytopathology reduced the number of passes, ensured specimen adequacy, provide definitive diagnosis and should be used if possible. »

  - ↑ 7 à 10% diagnostic value

- Number of passes
  - → 10-50

Binmoeller et al, Gastrointest Endosc 2002,56:suppl S86-91
Chang et al, Gastrointest Endosc 2002,56:suppl S28-34
Klapman et al, Am J Gastroenterol 2003,98(6);1289-94
Savoy AD et al, Gastrointest Endosc. 2007
Nguyen YP et al, Gastrointest Endosc. 2009

SAMPLE PREPARATION

- 1. **Air dried smears**
  - Diff-Quik stain
    - Onsite assessment
      - specimen adequacy
        - » ↓ numbers of required passes
        - » ↓ risk and unpleasantness for the patient
      - Preliminary diagnosis
        - » Need for additional material for ancillary studies



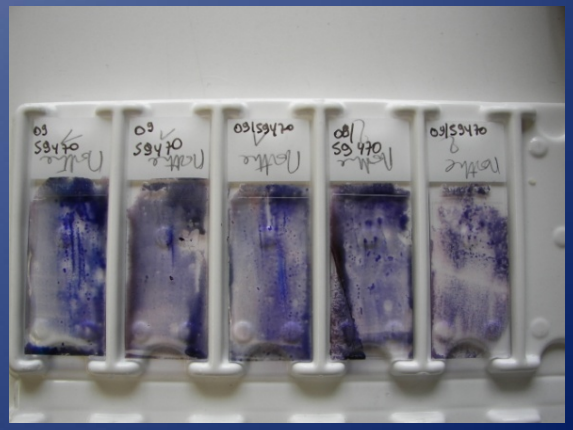

SAMPLE PREPARATION

- 2. **Sample rinsed in alcohol-based solution**
  - Thin layer slides
  - Papanicolaou stain

  - Lost of background material

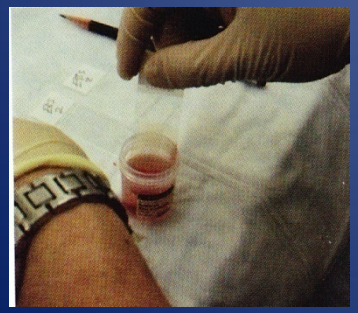

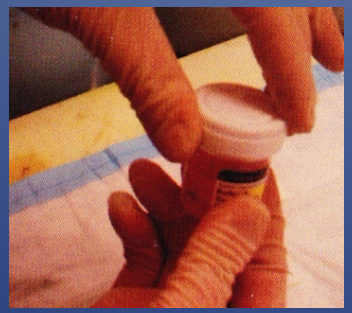



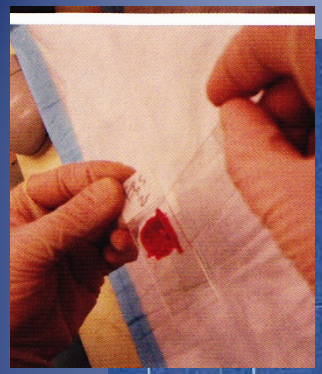

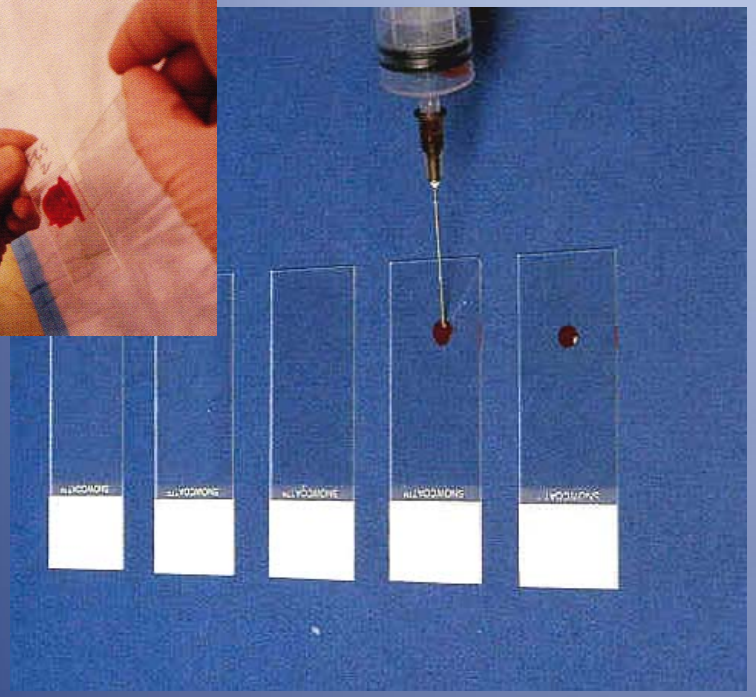

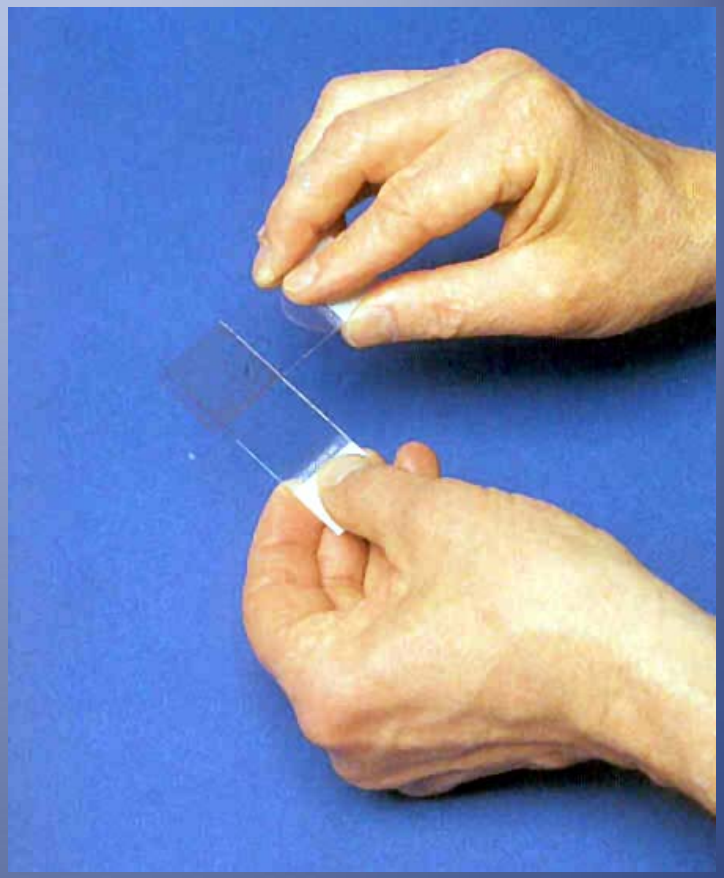

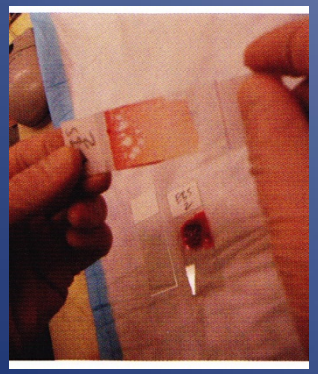

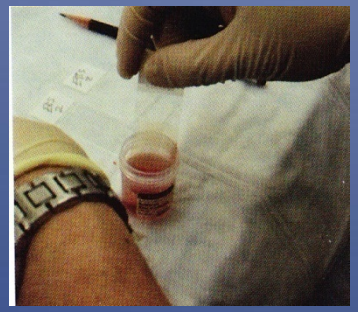

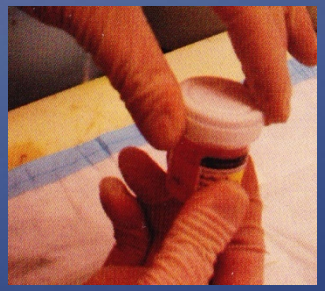

	Diff Quick	PAPANICOLAOU
Technical dependence	No	Yes
Air dried	No artefact	Artefacts
Liquid-based preparation	Artefacts	No artefact
Cellular size	Increased	Same as histology
Cytoplasm	Well seen	Less well seen
Nuclei	Not always seen	Well seen
Nucleoli	Well seen	Well seen
Stroma	Well seen	Well seen

SAMPLE PREPARATION

- 3. **Cell block** < clotted bloody material
  - Alcohol based solution
  - 10% neutral buffered formalin

  - Information about cellular architecture
  - Immunocytochemistry

CYTOBLOC

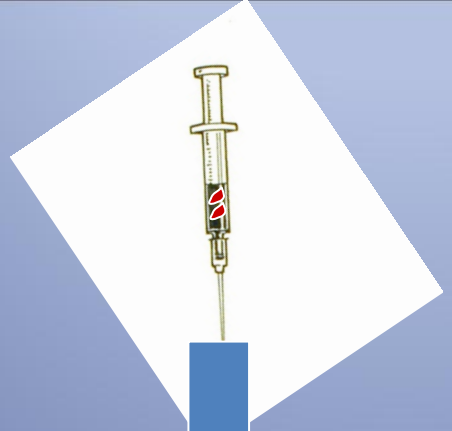

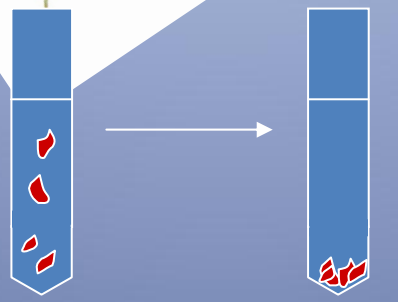

fixation

centrifugation

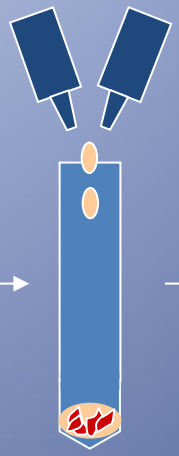

polymerisation

inclusion in paraffine

Histologic slides

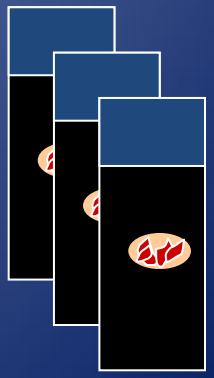

HE stain
Spécial stains
immunohistochemistry

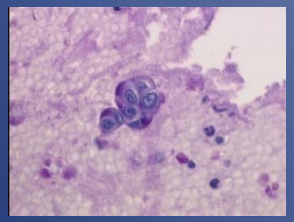

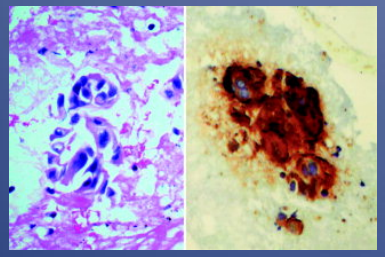

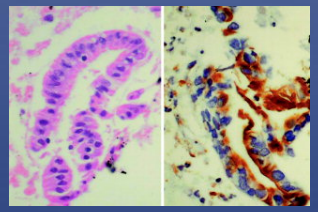

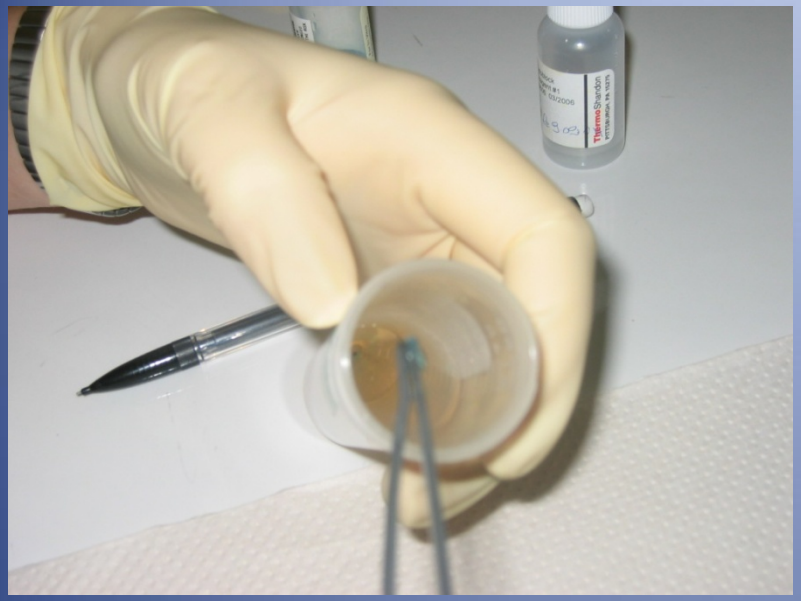

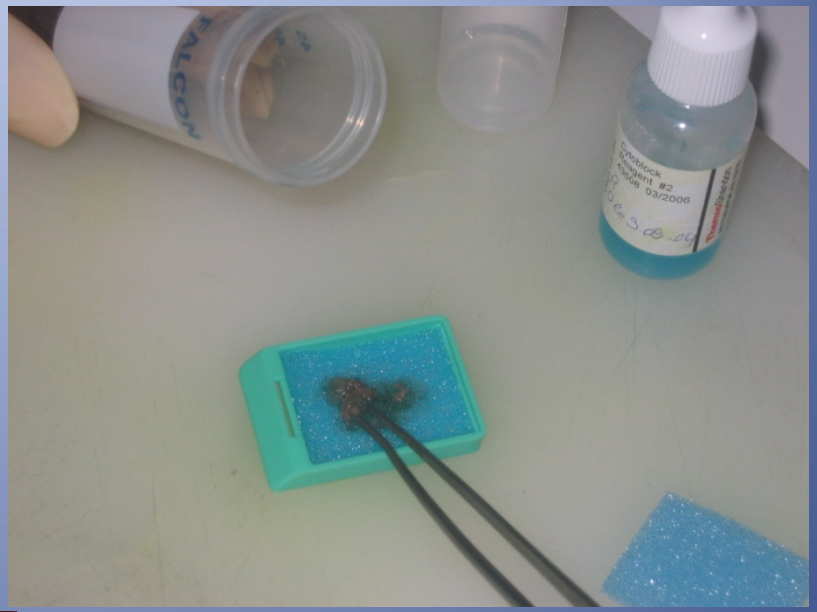
FALCON
Crystalock
Reagent #2
Issue 03/2006

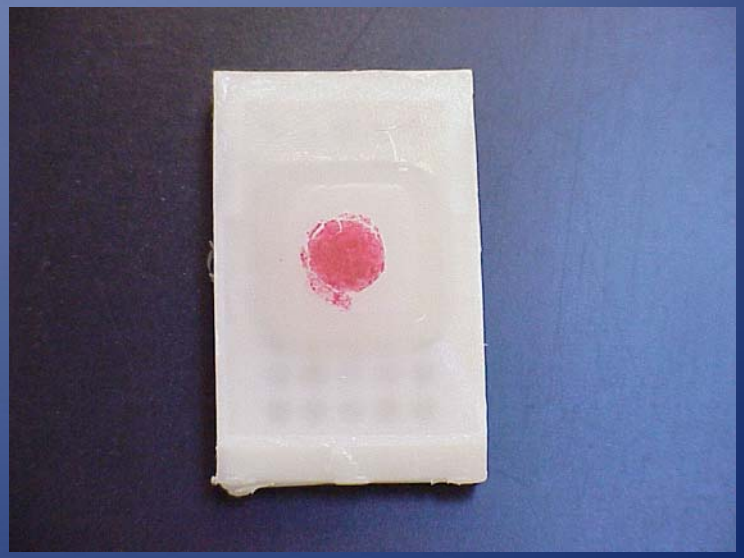

PANCREATIC CYTOPATHOLOGY

CYTOLOGY OF NORMAL PANCREAS

- **Acinar cells = predominant cell type**
  - Small to medium-sized cohesive groups
  - Some single cells
  - Pyramidal or triangular shape
  - Abundant granular cytoplasm
  - Round, eccentric or central nuclei
  - Fine chromatin
  - Often distinct nucleoli

- Papanicolaou stain
  - Blue-green

- Air dried Diff quik stain
  - Enhance abundance and granularity of the cytoplasm

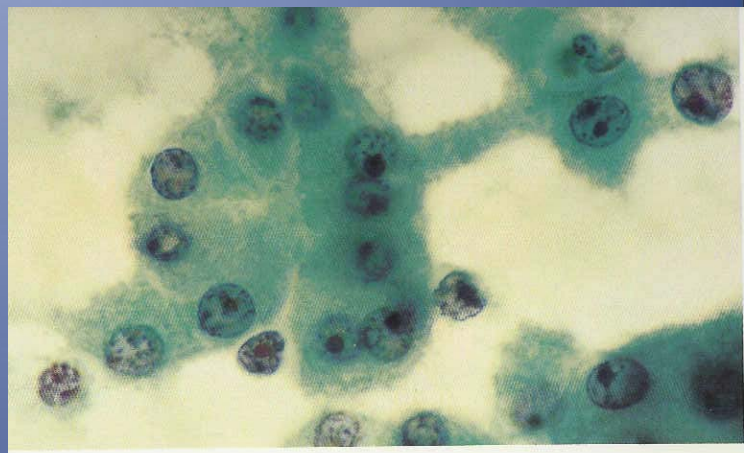

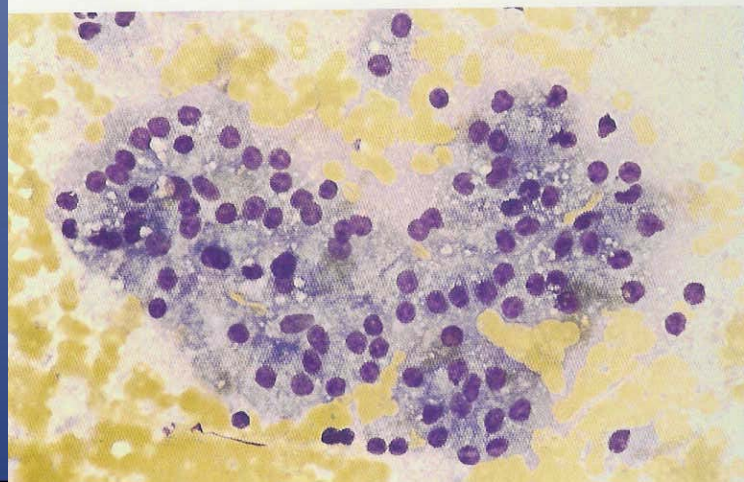

CYTOLOGY OF NORMAL PANCREAS

- Ductal cells < larger interlobular ducts
  - Two-dimensional flat sheets with « honeycomb » appearance
  - Cuboidal to columnar shape
  - Basally located nuclei
  - Scant pale cytoplasm
  - Round to oval nuclei
  - Occasional goblet cells

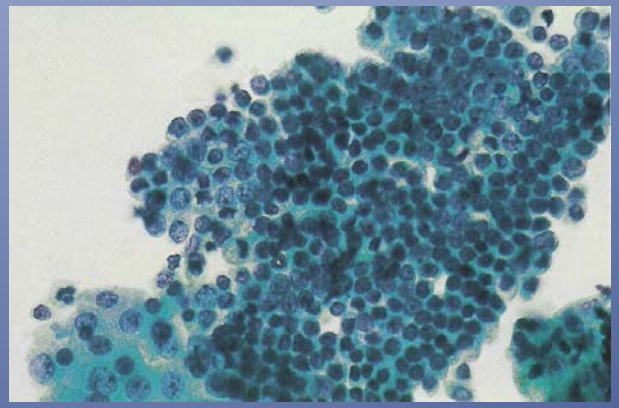

- Papanicolaou stain
  - Blue
- Papanicolaou stain
  - Purple

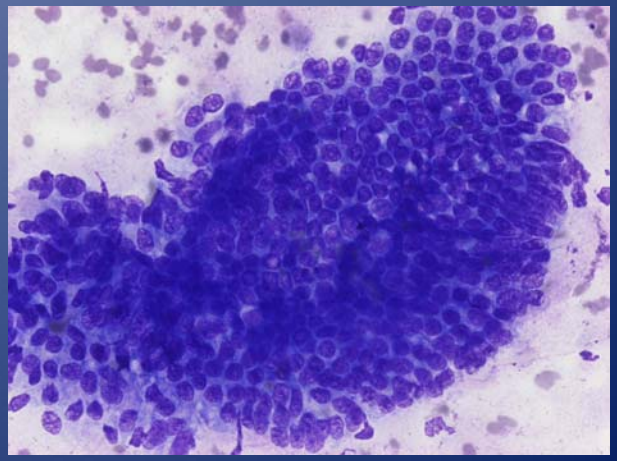

CYTOLOGY OF NORMAL PANCREAS

- Islet cells
  - Rarely identified
  - Tail of the pancreas

CONTAMINANTS < EUS-FNA

- **Duodenal mucosa**
- **<Trans duodenal** < lesion in the head and uncinate
  - Two-dimensional flat sheet
  - Variable single cells
  - Round nuclei
  - Pale cytoplasm with well-defined borders
  - Intermixed goblet cells
  - Thin extra cellular mucus

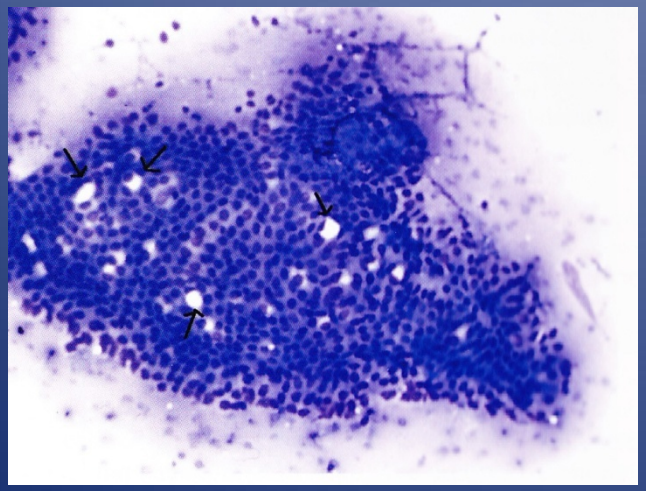

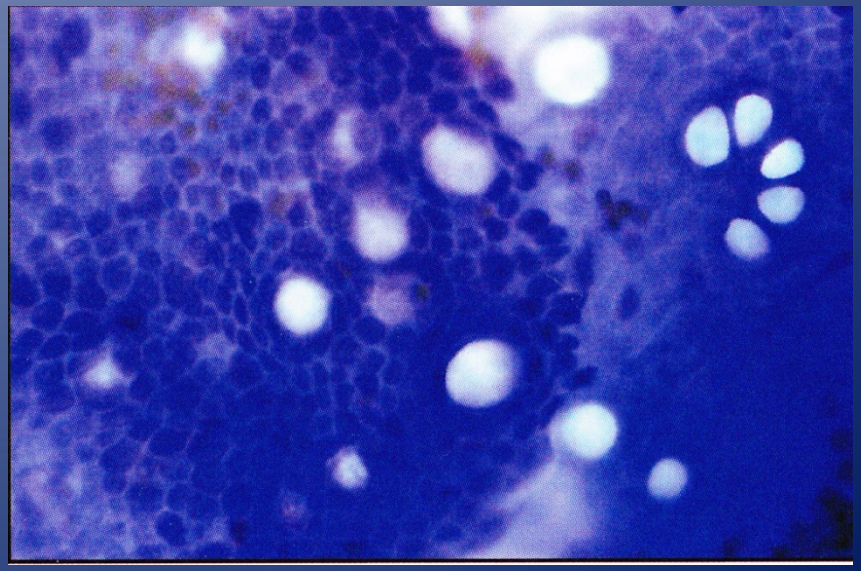

CONTAMINANTS < EUS-FNA

- **Gastric mucosa**
  - < transgastric < lesions of the pancreatic body or tail
  - Two-dimensional flat sheet
  - Variable single cells
  - Round nuclei
  - Pale cytoplasm with well-defined borders
    - Frequently admixed with mucus

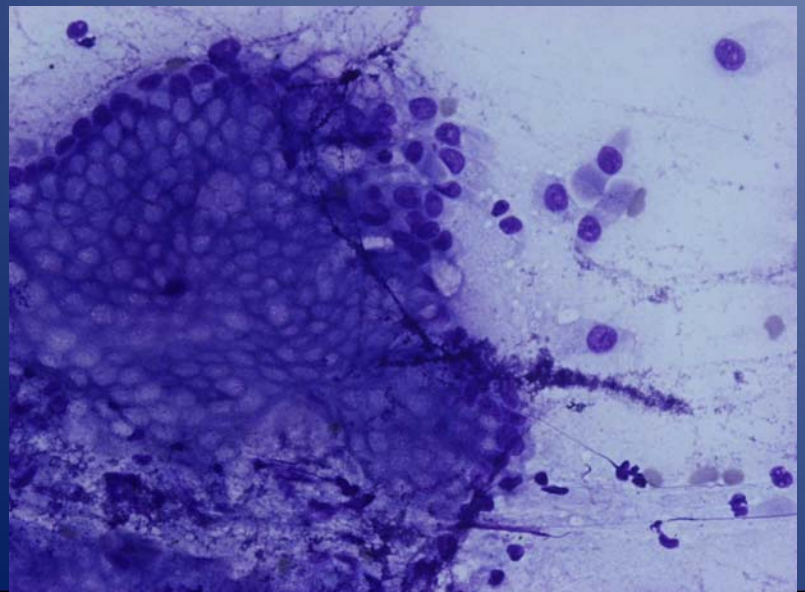

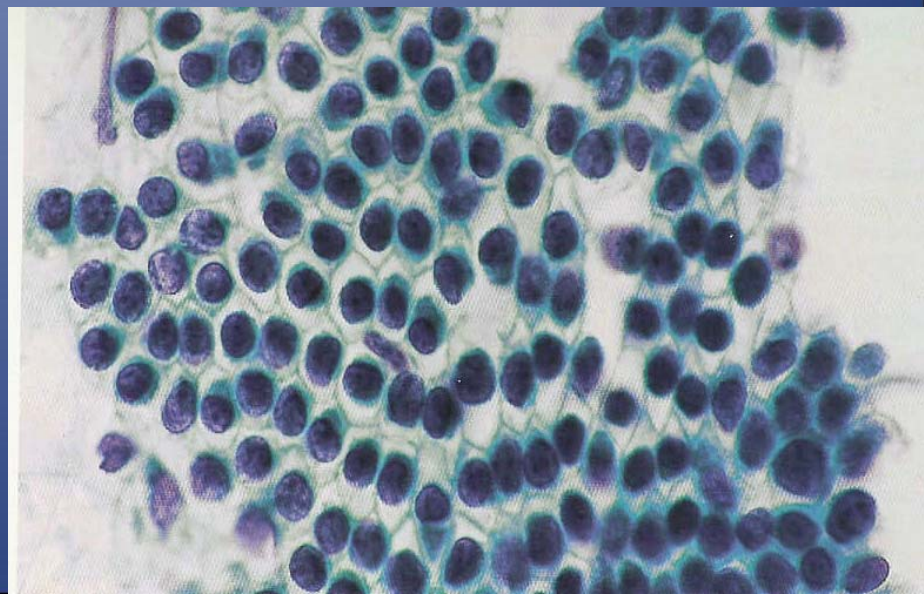

CONTAMINANTS < PERCUTANEUS ASPIRATION

- **Mesothelial cells**
  - Mistaken for ductal epithelium
    - Two-dimensional flat sheet
    - Round to oval nuclei
    - Moderate amount of pale cytoplasm
    - Intercellular windows

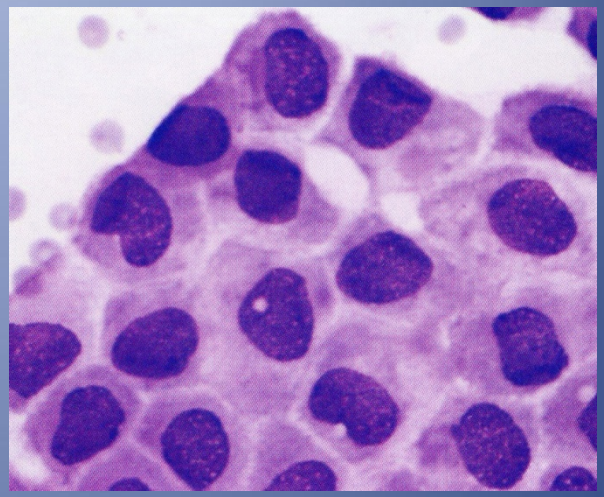

- **Hepatocytes**
  - Polygonal cells Abundant well defined granular cytoplasm
  - Round to oval nuclei
  - Prominent nucleoli

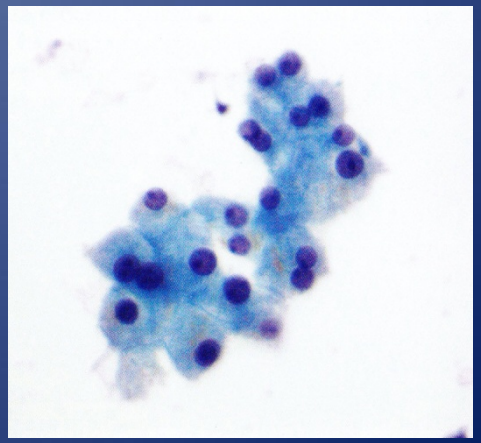

GENERAL APPROACH OF PANCREATIC CYTOPATHOLOGY

- Clinical and imaging data are essential to provide diagnosis
- Starting point: solid or cystic lesion
  - Quite different differential diagnosis
- Trans duodenal or gastric EUS-FNA
- Presence of chronic pancreatitis

REPORTING TERMINOLOGY

- Critical for the clinical management

- **Solid lesions**
  - No neoplasm seen
  - Atypical/indefinite diagnosis
  - Definitive diagnosis of neoplasm

- **Cystic lesions**
  - Non-specific cyst
  - Descriptive/qualified diagnosis
  - Definitive diagnosis of neoplasm

I Solid lesions

PANCREATIC DUCTAL ADENOCARCINOMA

↕

CHRONIC PANCREATITIS

PANCREATIC DUCTAL ADENOCARCINOMA

- Most common cytological neoplastic diagnosis

- 85 to 90% of all pancreatic cancers
- Location
  - 50% < head
  - 15% < body
  - 5% < tail
- Imaging technique = solid mass

PANCREATIC DUCTAL ADENOCARCINOMA

- **Cytological features**

- High cellularity

- Background
  - Clean
  - Inflammatory
  - Mucinous
  - Necrotic

- Predominantly ductal cells

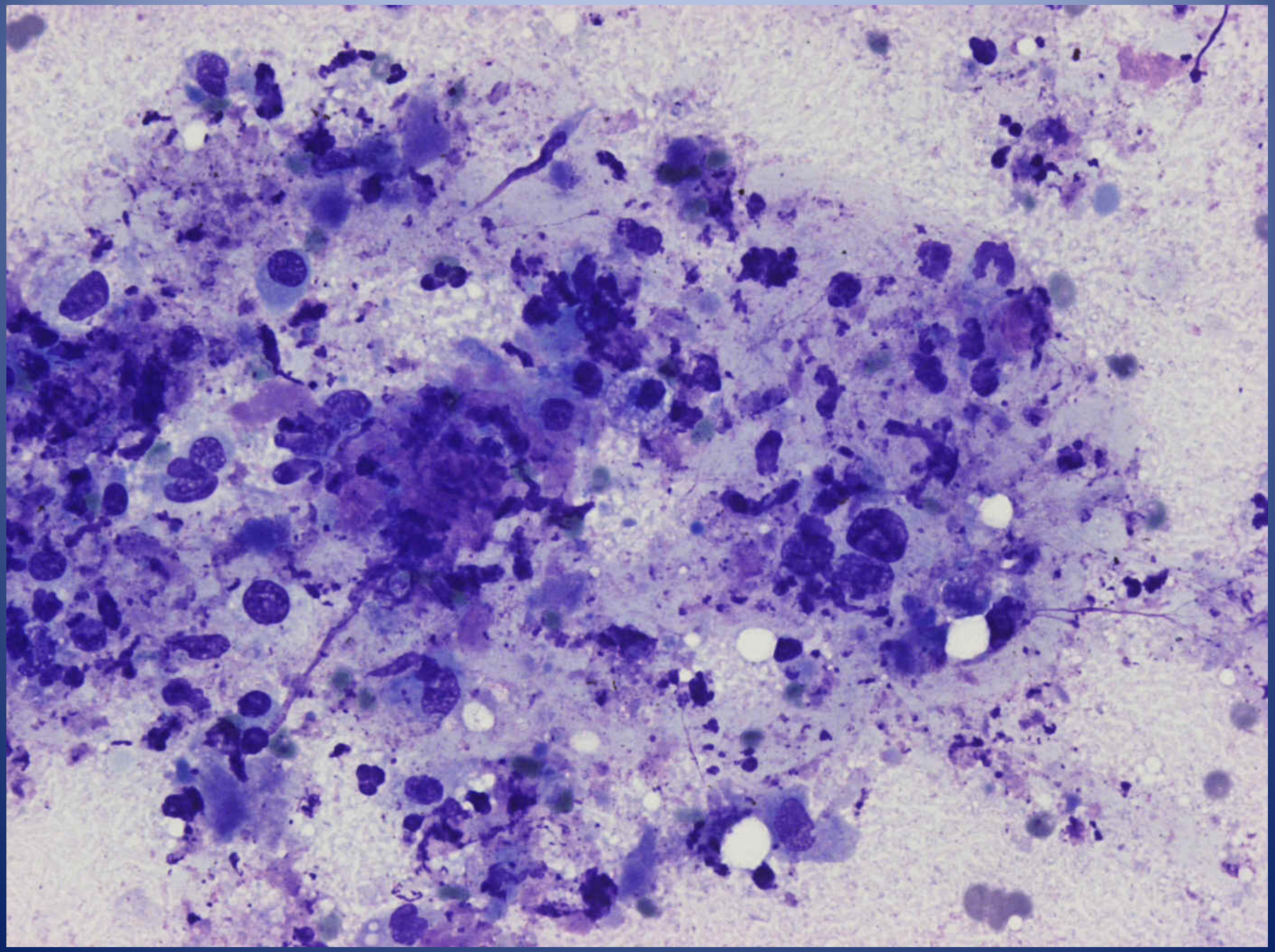

PANCREATIC DUCTAL ADENOCARCINOMA

- **Cytological features**
- Cell groups with overcrowding and/or distorderly arrangement
- Isolated atypical cells
  - Often few in number
  - Extremely helpful for making the diagnosis
- Nuclear atypia
  - Nuclear enlargement (at least 2X the size of red blood cells)
  - Irregular nuclear contours
  - Coarse chromatin
  - Macro nucleoli
  - Bi- and multinucleation
  - Mitotic figures

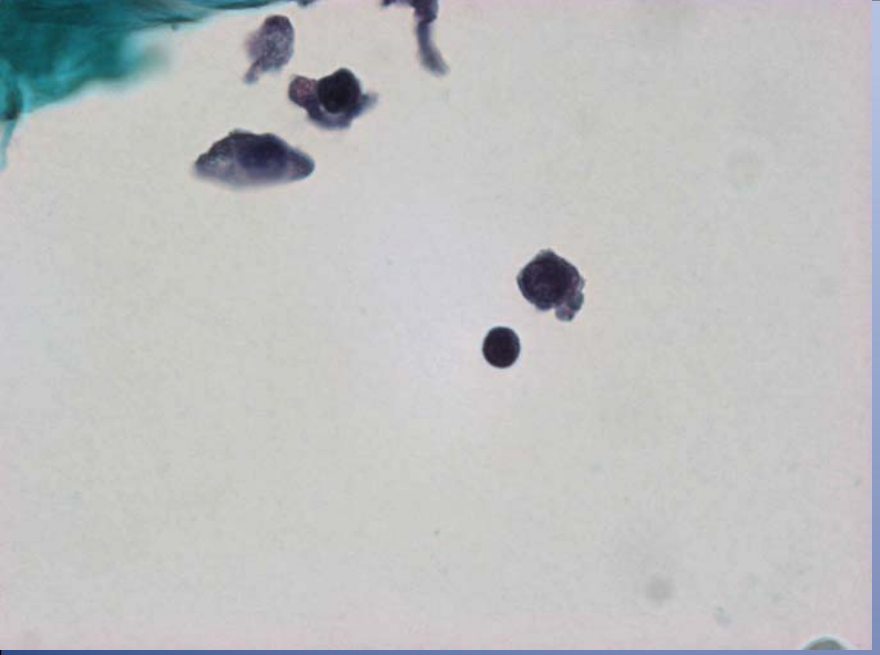

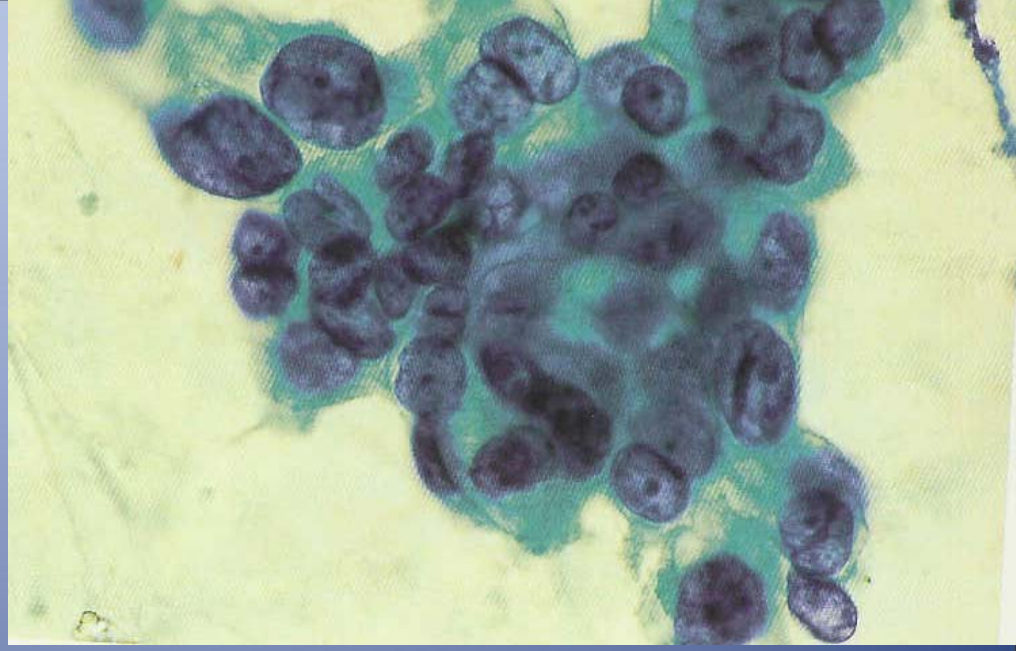

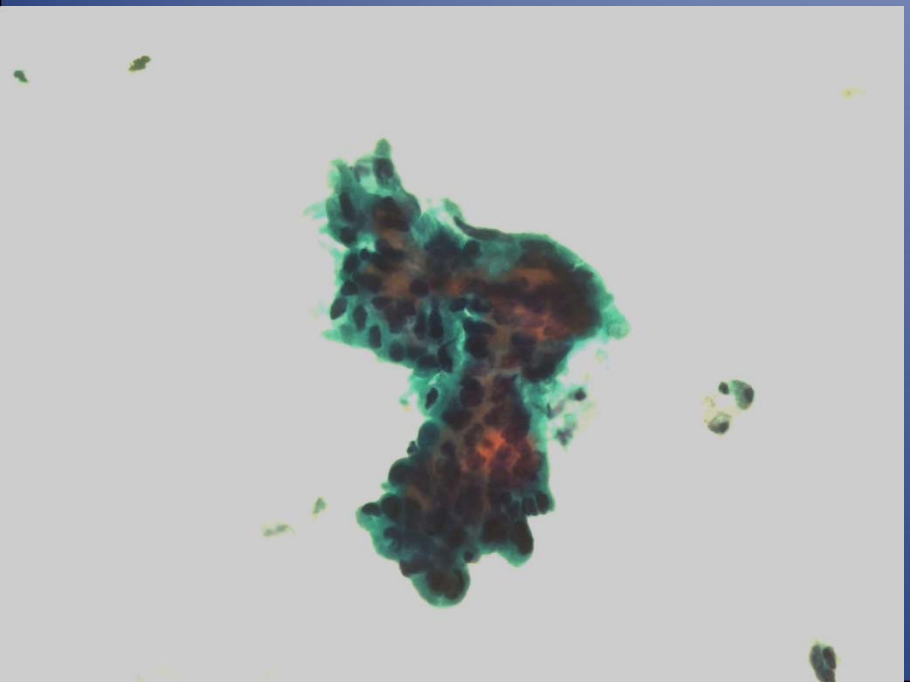

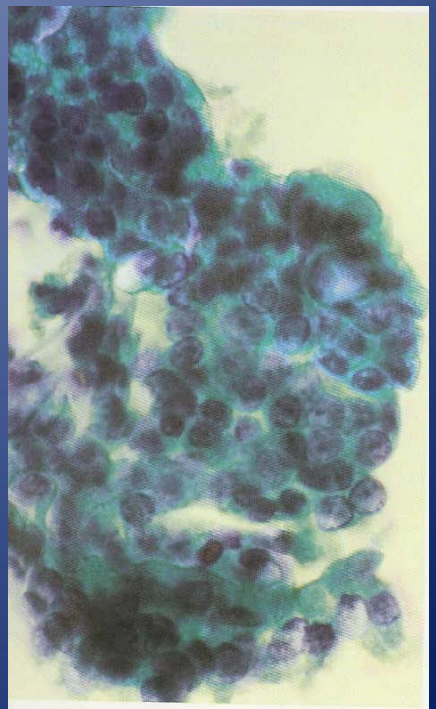

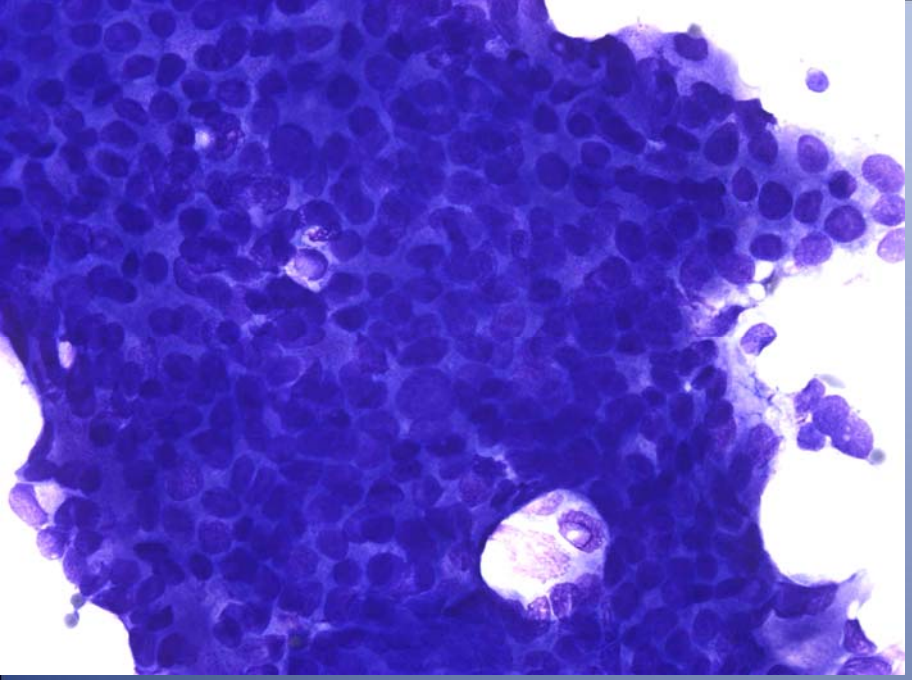

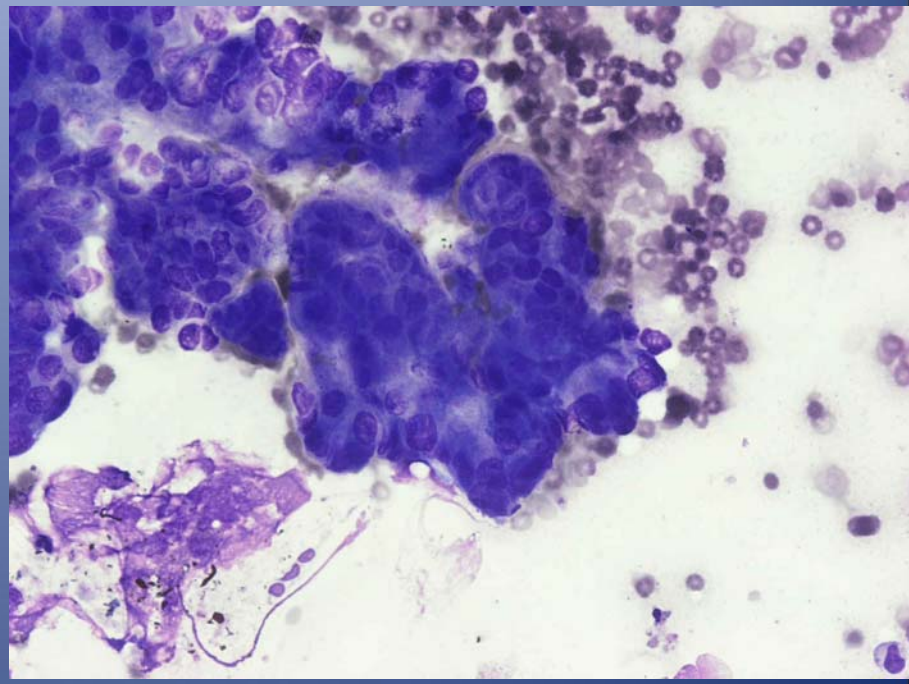

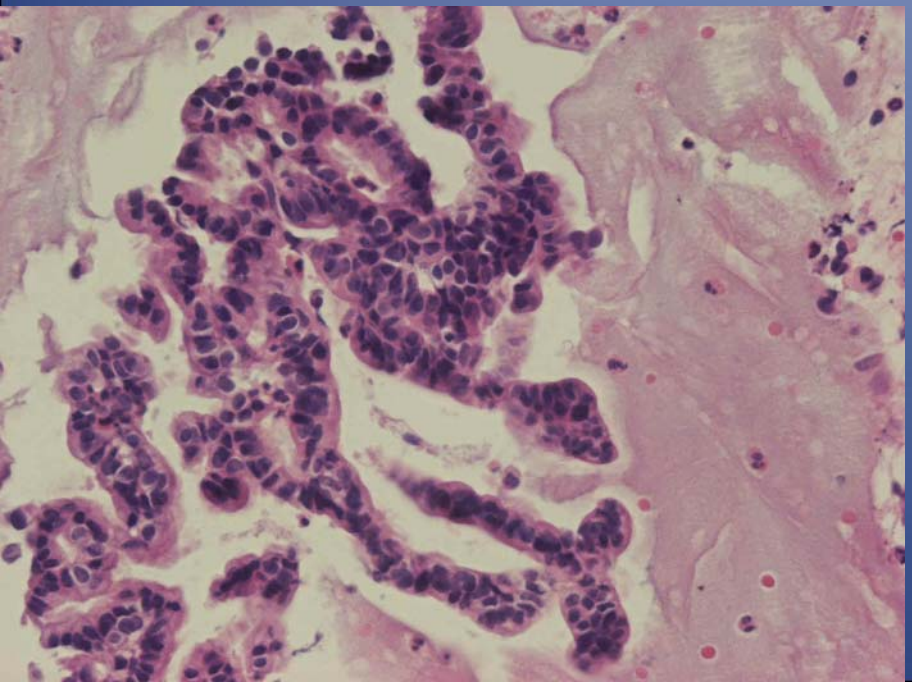

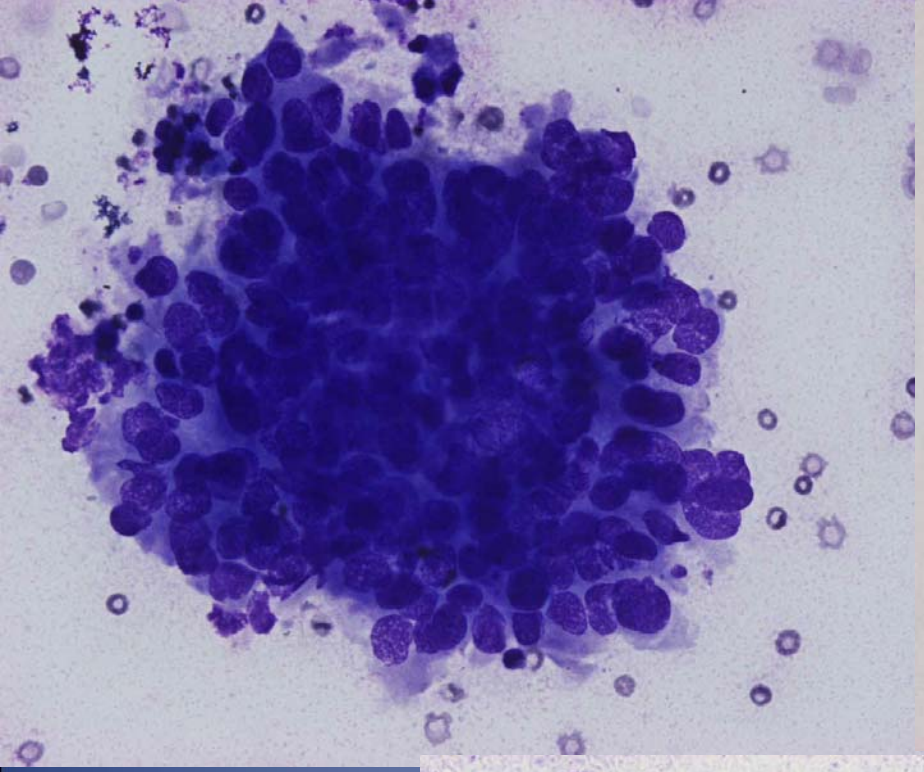

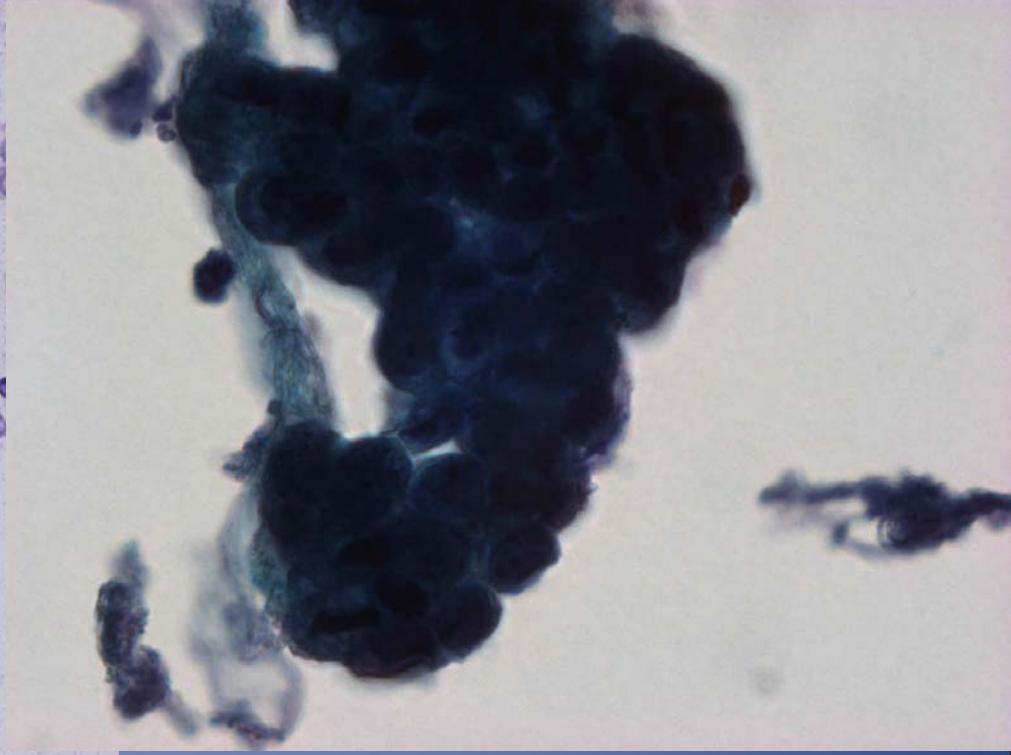

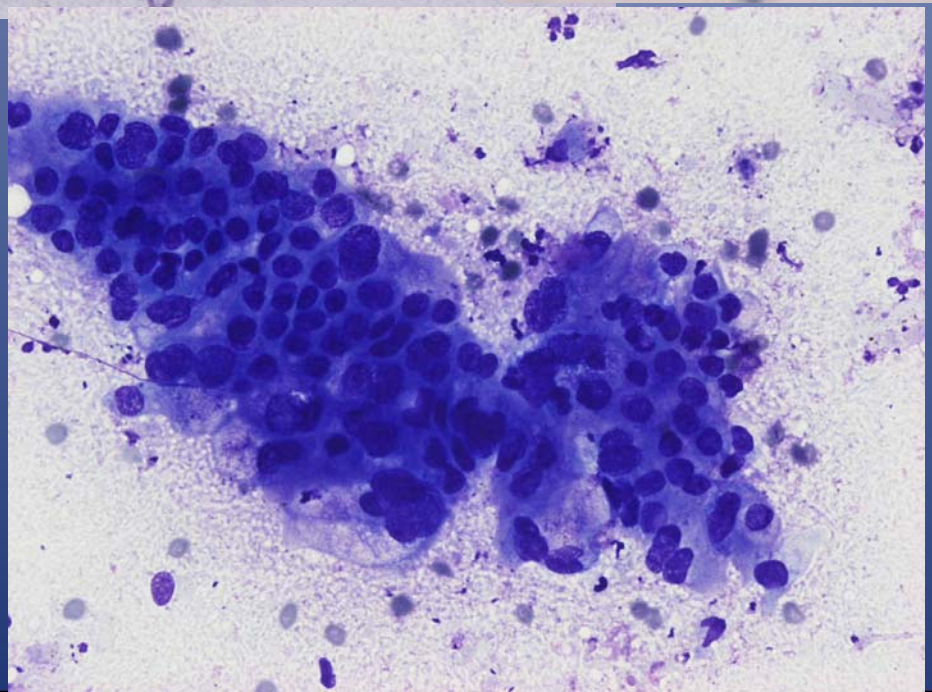

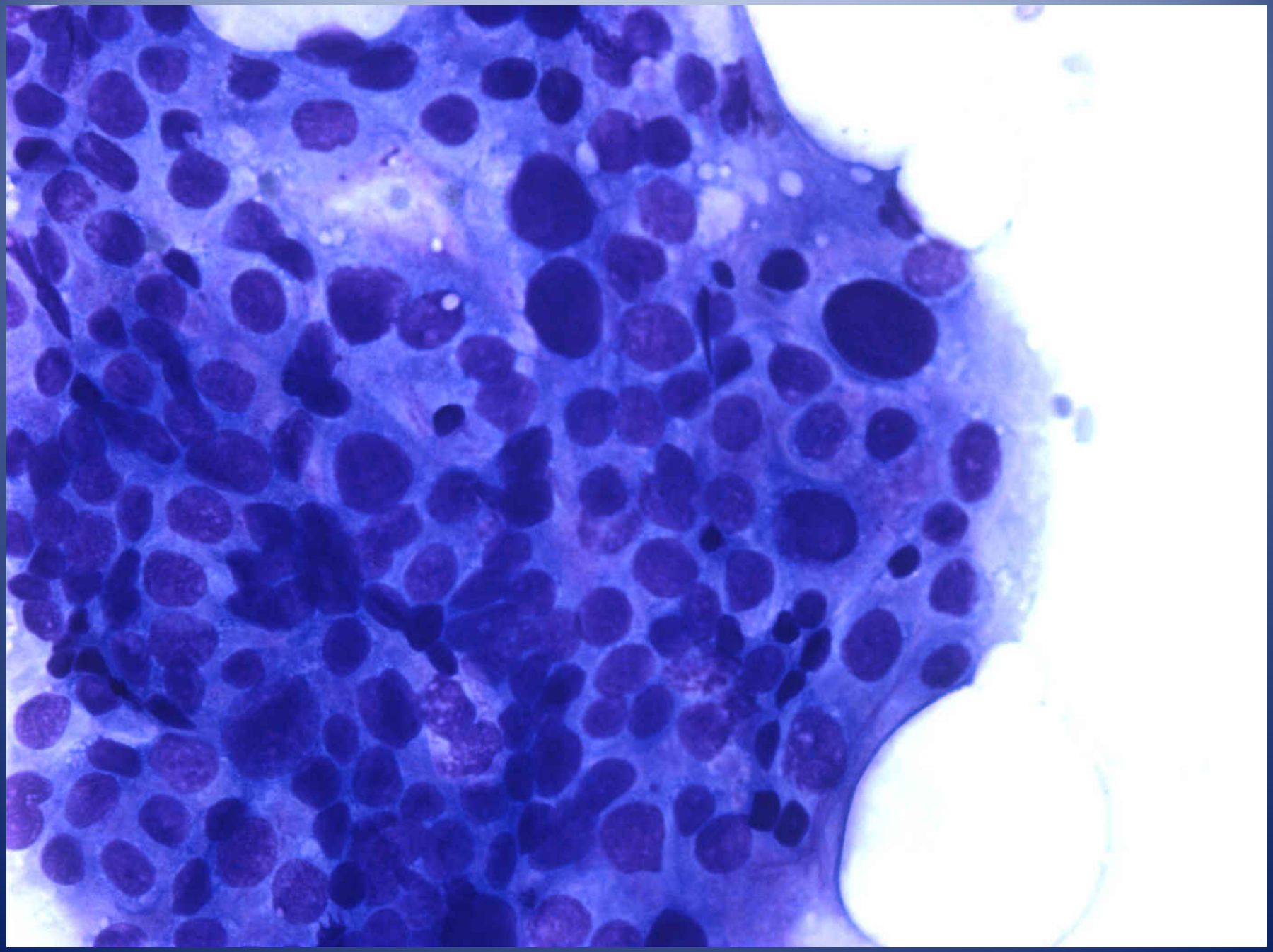

VARIANTS OF PANCREATIC DUCTAL CARCINOMA

- Adenosquamous carcinoma (5%)
- Anaplastic carcinoma
  - DD:melanoma, lymphoma, sarcoma
- Osteoclastic giant cell carcinoma
- Signet ring cell carcinoma (1%)
- Foamy gland adenocarcinoma
- Small cell undifferentiated carcinoma
  - DD: metastatic small cell carcinoma

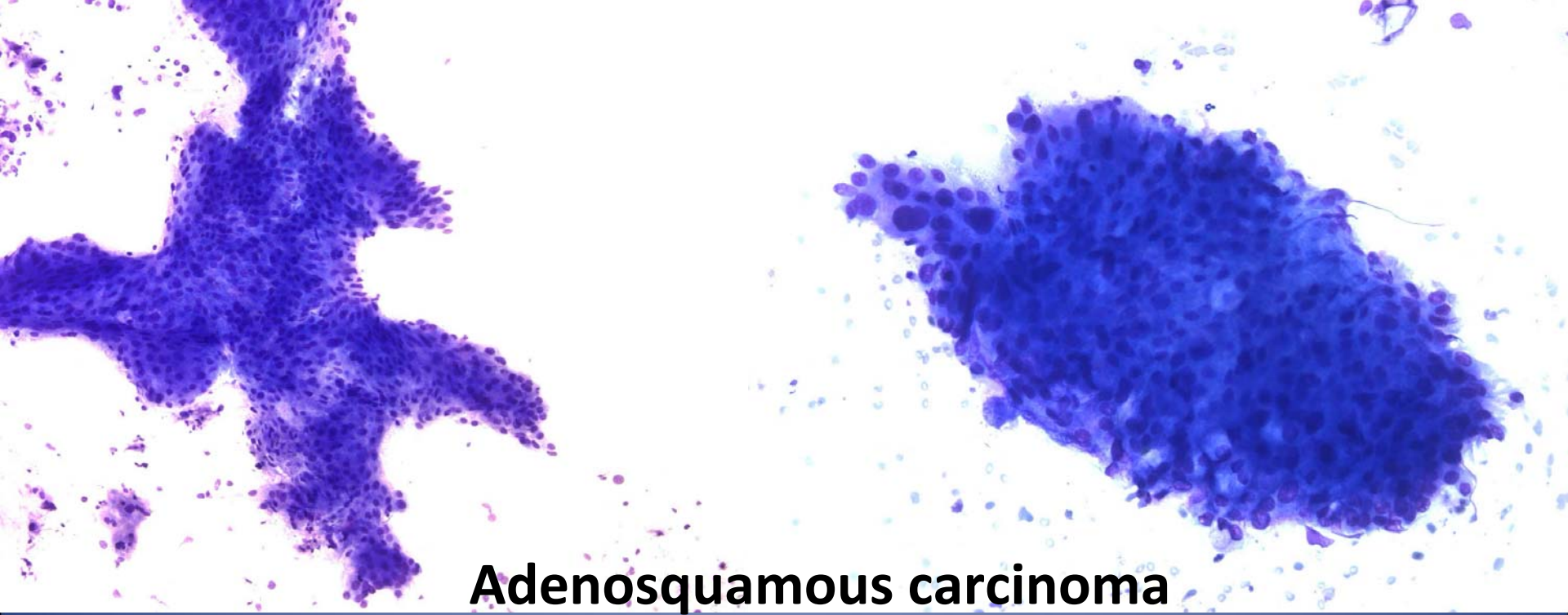

Adenosquamous carcinoma

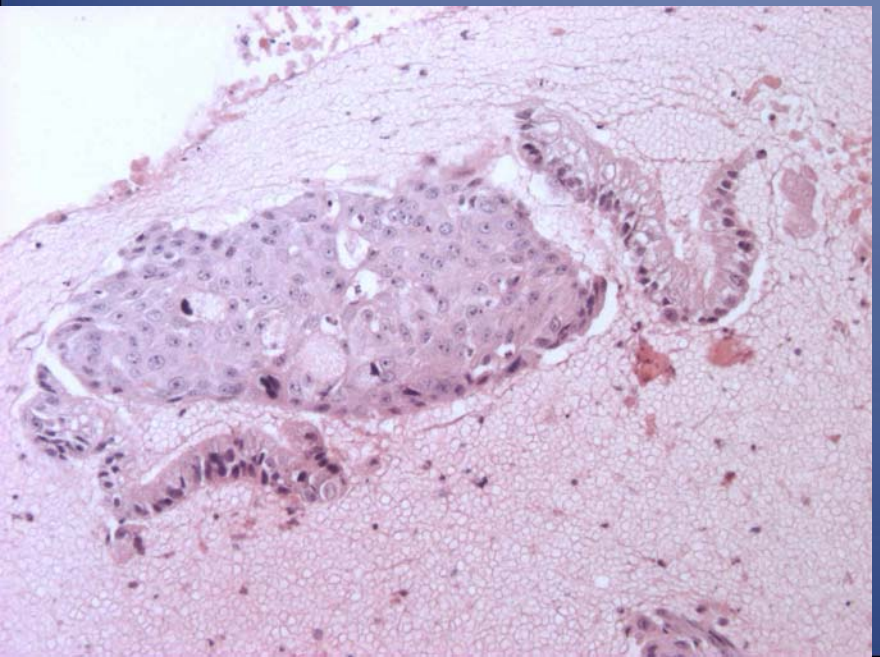

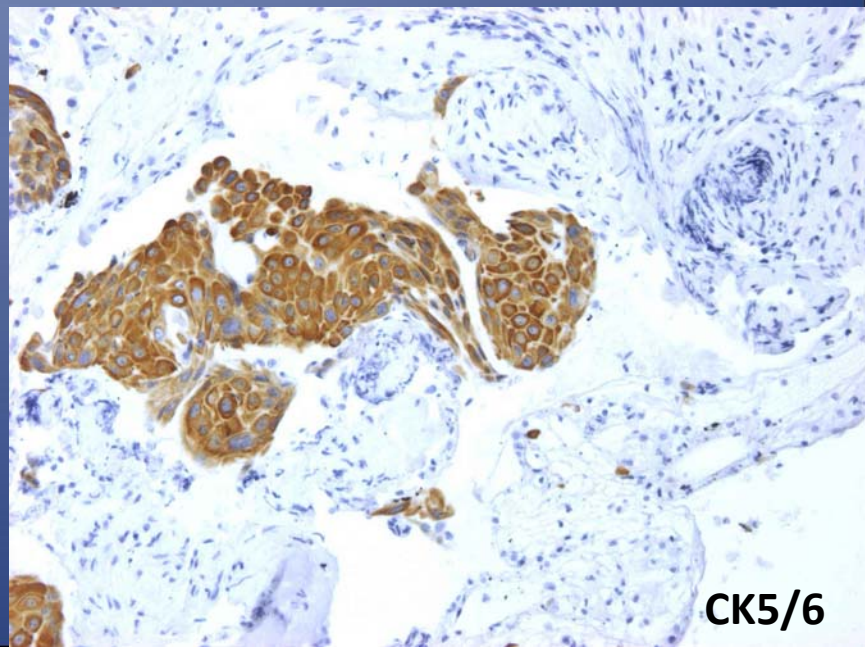

Anaplastic carcinoma

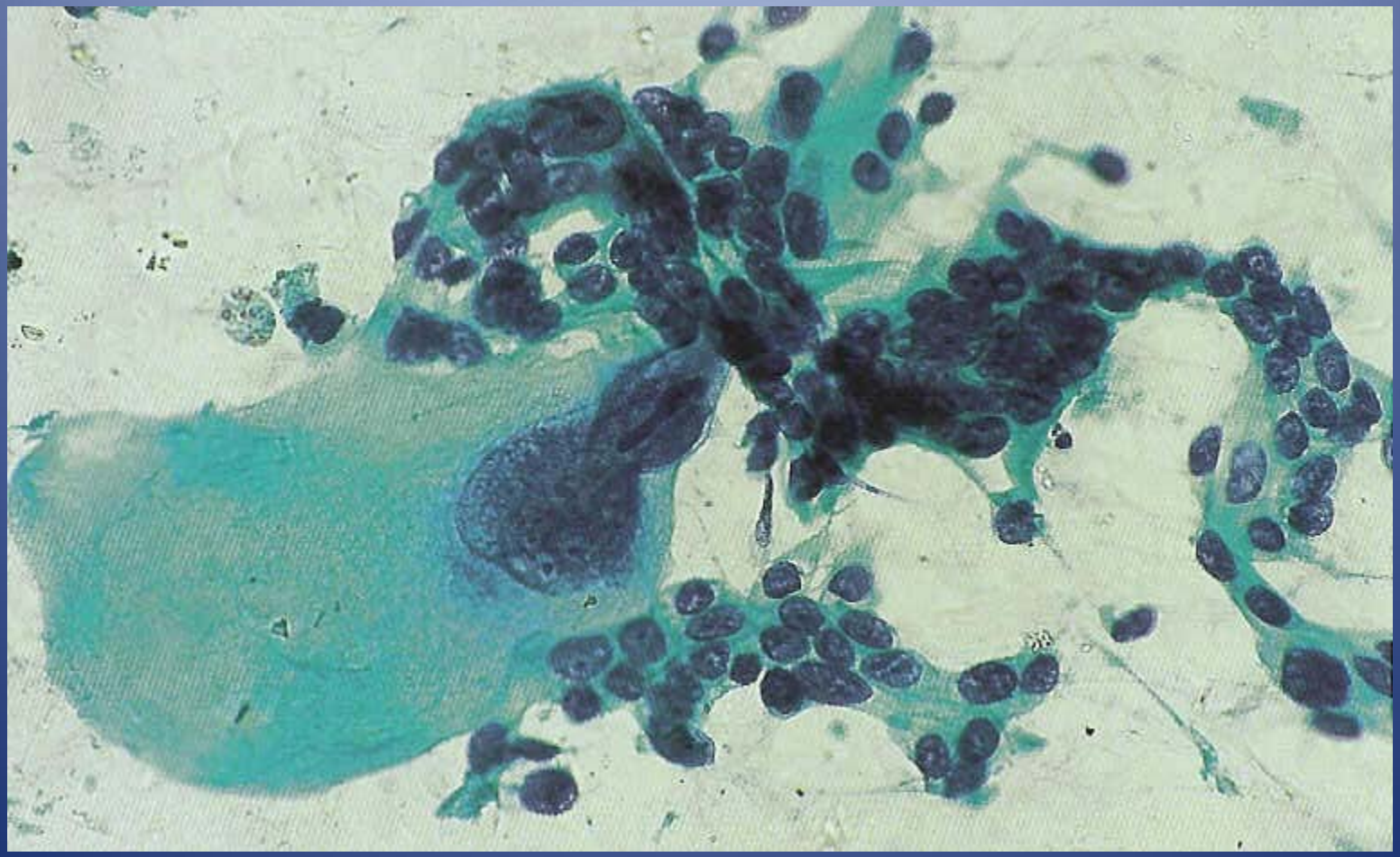

SIGNET RING CELL CARCINOMA

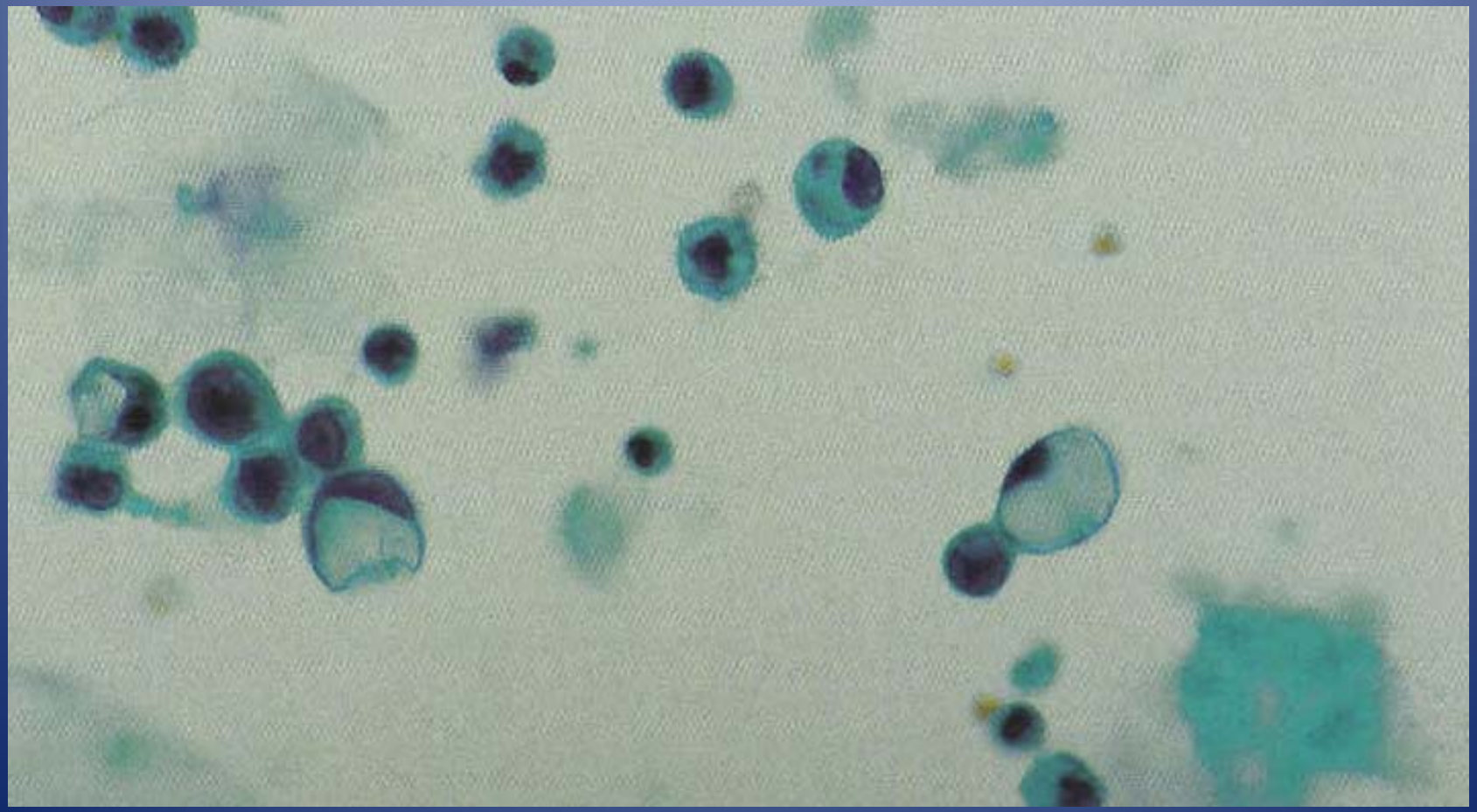

DIFFERENTIAL DIAGNOSIS OF PANCREATIC DUCTAL ADENOCARCINOMA

- **Chronic pancreatitis**
- Acinar cell carcinoma
- Endocrine tumour
- Metastases

CHRONIC PANCREATITIS

- Cellularity
  - variable, scant to cellular depending on fibrosis
- Presentation
  - Monolayer cohesive honeycomb pattern tissue fragments
  - Rare single cells
  - Rare focal and mild peripheric crowding
- Type of cells
  - Mixed cellular elements: ducts, acini, inflammatory cells, fibrosis
- Necrosis
  - Rare

Chronic pancreatitis	Well diffrentiated adenocarcinoma
Various cellular elements Ducts Acini Ilets Inflammatory cells	Ducts
Flat monolayered sheets with uniformly spaced nuclei	Flat, monolayered shhets with noticeable nuclear crowding and overlaping
Round to ovale nuclei	Abnormally shaped nuclei: pyramidal, carrot-shaped
Normal chromatin distribution	Frequent chromatin clearing
Few small nuceoli	Many prominent nucleoli
Rare to no intact single epithelial cells	Few to many intact epithelial cells
Rare to no mitosis	Rare to no mitosis
No necrosis	Generally no necrosis

WELL-DIFFRENTIATED DUCTAL ADENOCARCINOMA

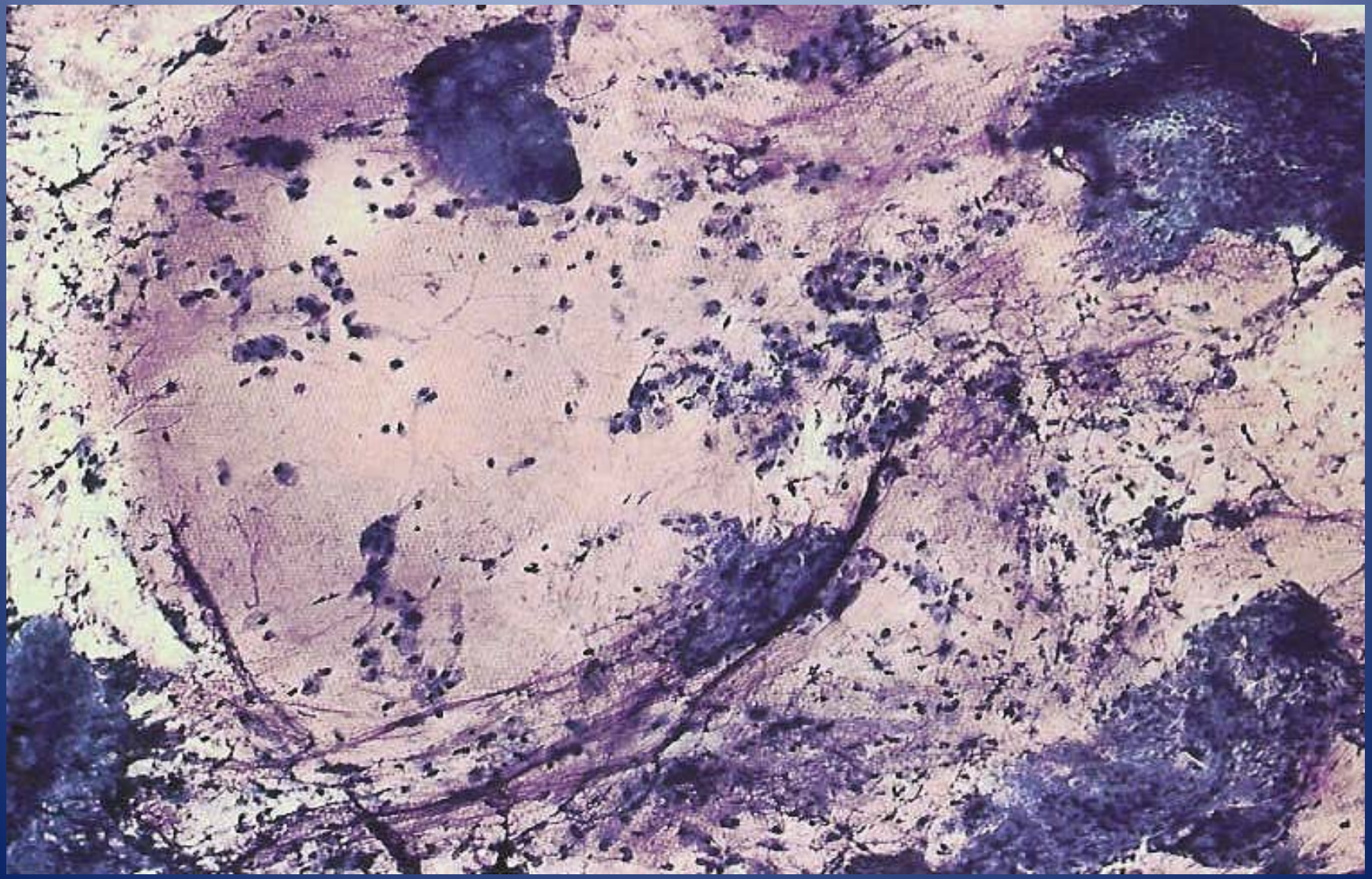

CHRONIC PANCREATITIS

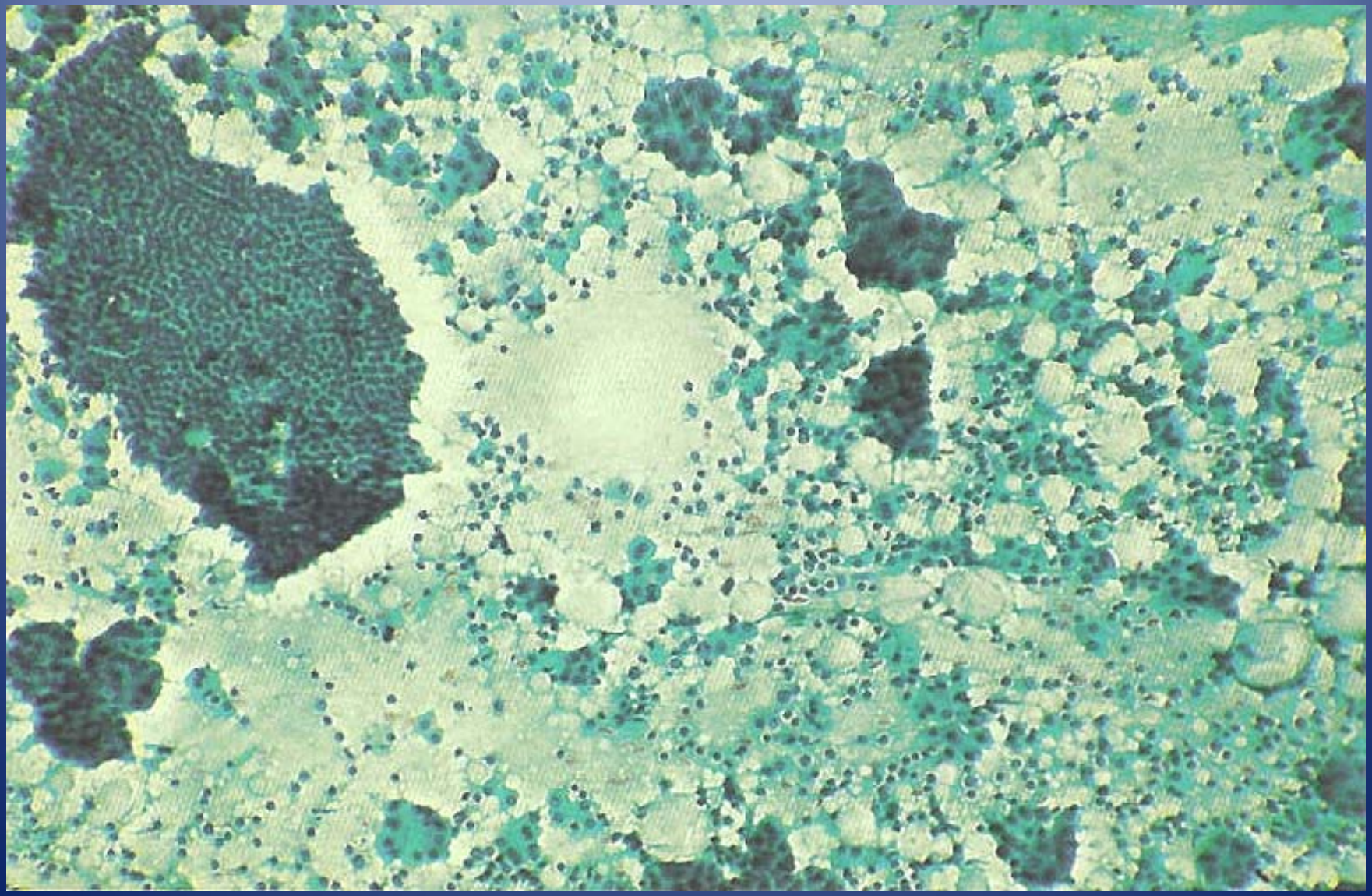

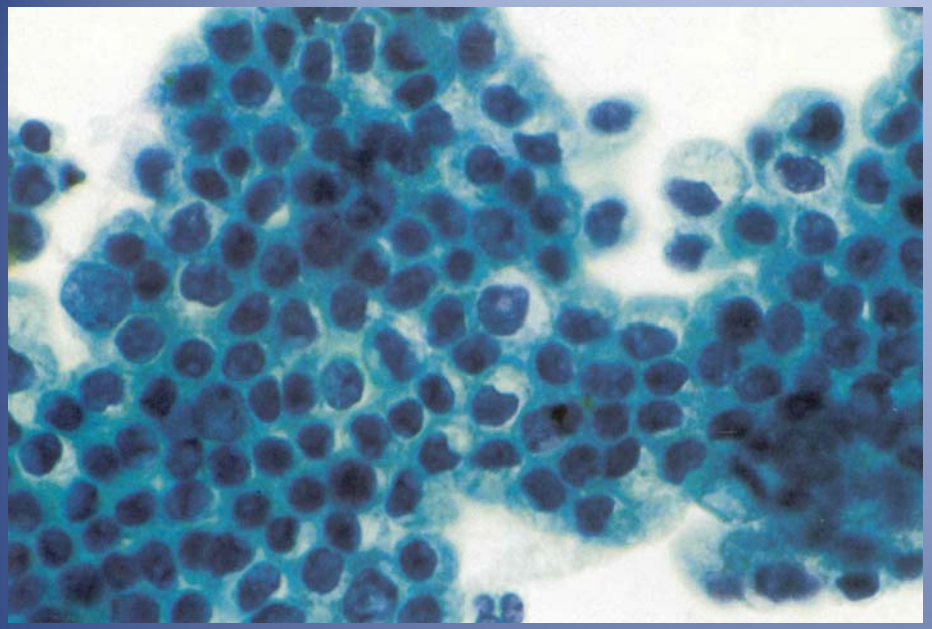

CHRONIC PANCREATITIS

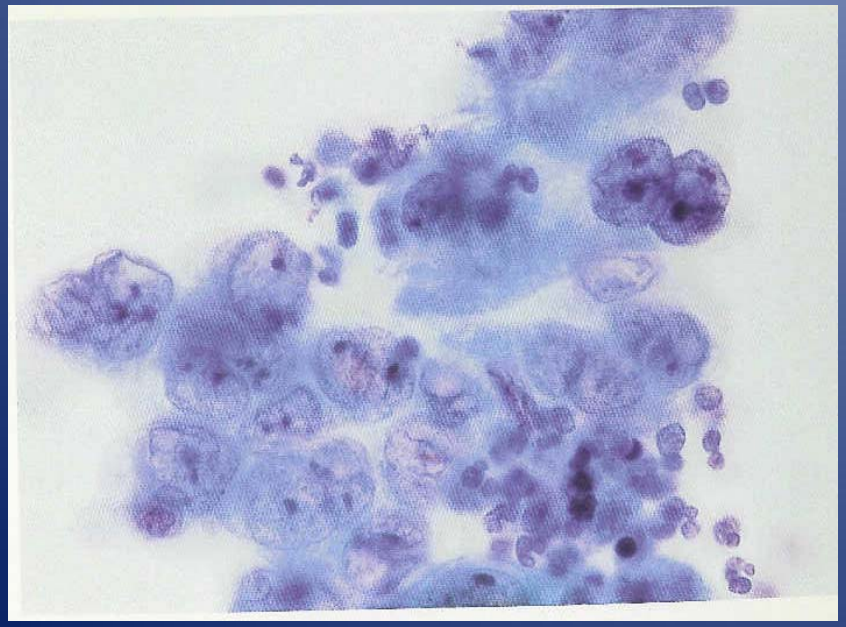

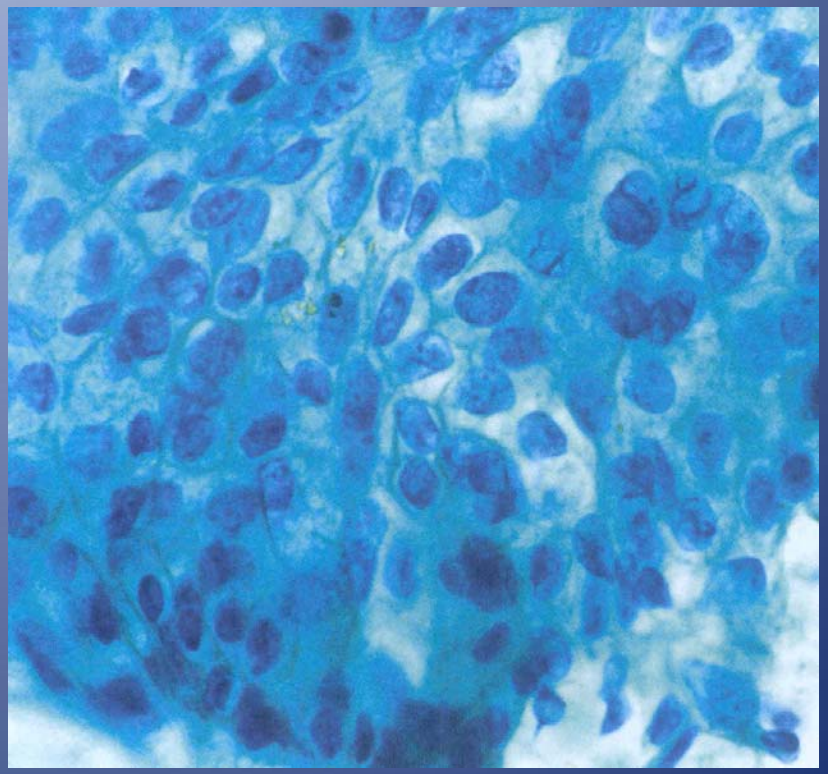

WELL-DIFFRENTIATED DUCTAL ADENOCARCINOMA

DIAGNOSTIC PITFALLS

- **Nature of the lesion**
  - Localisation
  - Prominent fibrosis
- **Chronic pancreatitis**
  - **Reactive architectural and/or cytological atypia = PanIN**
- **Well-differentiated ductal adenocarcinoma**
  - **Lack of obvious cytological features of malignancy**
- **Conservative attitude of the cytopathologists**

MAJOR AND MINOR CRITERIA FOR DIAGNOSIS OF ADENOCARCINOMA

- **Major**
  - Nuclear crowding or overlapping
  - Irregular nuclear membrane
  - Irregular chromatin
- **Minor**
  - Nuclear enlargement
  - Single epithelial cells
  - Necrosis
  - Mitoses

Minimum 2 major criteria
or
1 major criteria and 3 minor criteria

↓

100% de diagnostics

Robins DB et al, Acta Cytol,1995

APPROPRIATE DIAGNOSTIC CRITERIA

- Major and minor Robin ’s criteria
  - Nuclear membrane irregularity (M)
  - Nuclear crowding and overlapping (M)
  - Nuclear enlargement (m)

None of these criteria , when present alone is enough to diagnose malignancy

Inspection of all epithelial sheets

Eloubeidi MA et al, Cancer Cytopathol 2003
Lin F et al, Cancer Cytopathol 2003
Robins DB, Acta Cytol 1995

APPROPRIATE DIAGNOSTIC CRITERIA

- **Minimal number of cells necessary to diagnose malignancy**
  - Subject of debates

- More than six groups of atypical cells showing not all cytological criteria of malignancy

or

- All cytological criteria of malignancy present in less than six epithelial groups

Considered as suspicious for adenocarcinoma

Eloubeidi MA et al, Cancer Cytopathol 2003, Lin F et al, Cancer Cytopathol 2003, Robins DB, Acta Cytol 1995

DIAGNOSTIC CRITERIA ANCILLARY TESTING

Biomarkers	Sensitivity	Specificity
P53	48%	97%
DPC4	21%	100%
P16	82%	73%
MUC1	96%	94%
Mesothelin	68-100%	91-95%
PSCA	84%	91%

Chhieng DC, Stelow EB. Pancreatic Cytopathology
Essential in Cytopathology
Series Editor
Rosenthal DL
Springer 2007

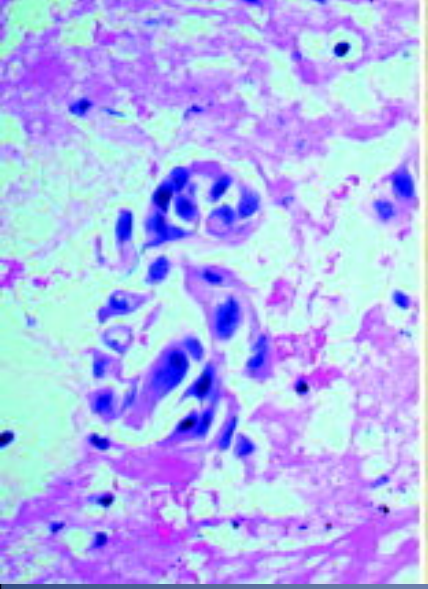

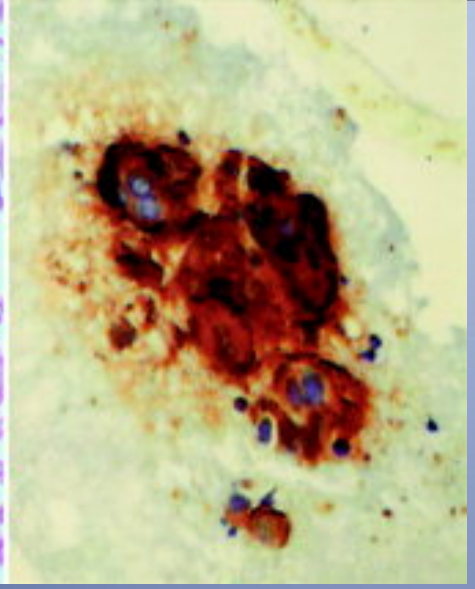

Malignant transformation of ductal cells is associated with a modification of MUC1 expression, characterised by strong cytoplasmic positivity and sometimes focal apical staining, whereas normal expression is limited to the apical/luminal pole of the ductal or acinar cells, which can be used as internal control.

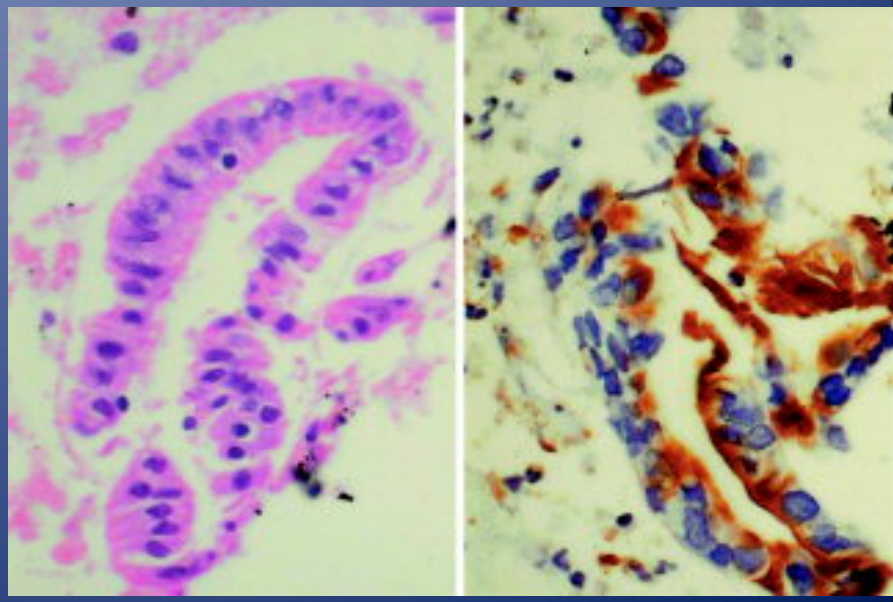

- Malignant transformation of ductal cells is associated with a modification of MUC1 expression, characterised by strong cytoplasmic positivity and sometimes focal apical staining, whereas normal expression is limited to the apical/luminal pole of the ductal or acinar cells, which can be used as internal control.
-

AUTOIMMUNE PANCREATITIS

- « The diagnosis should be suggested with chronic pancreatitis without any apparent risk factors for chronic pancreatitis »
- High degree of clinical suspicion for ductal adenocarcinoma
- IgG4
  - Immunocytochemistry
  - Serum assay

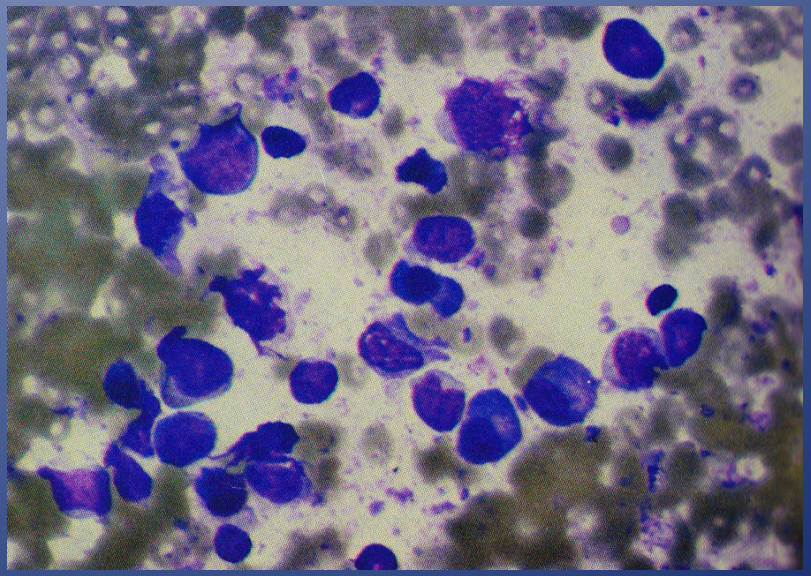

ACINAR CELL CARCINOMA

- Rare primary pancreatic neoplasm
- Affects older individuals
- Men > woman
- Better overall survival rate

ACINAR CELL CARCINOMA

- **Cytological features**
  - Cellular aspirate
    - Single cells
    - Loose clusters with formation of acini

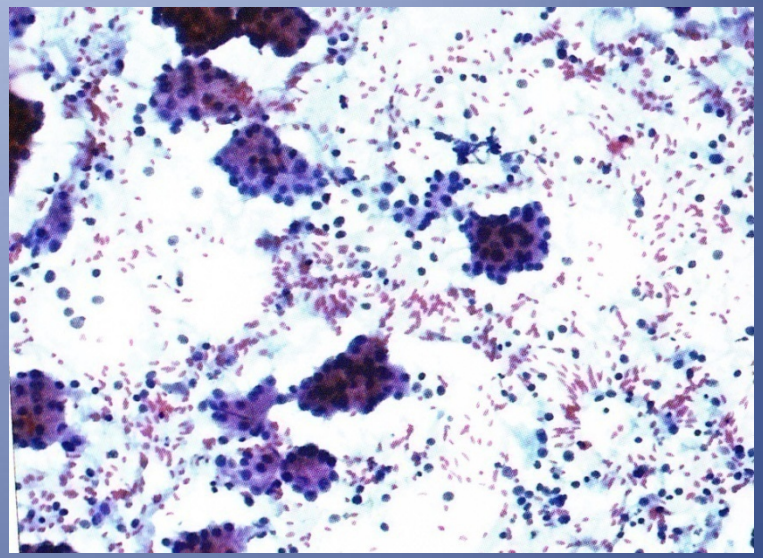

  - Background
    - No necrosis and debris
    - Naked nuclei

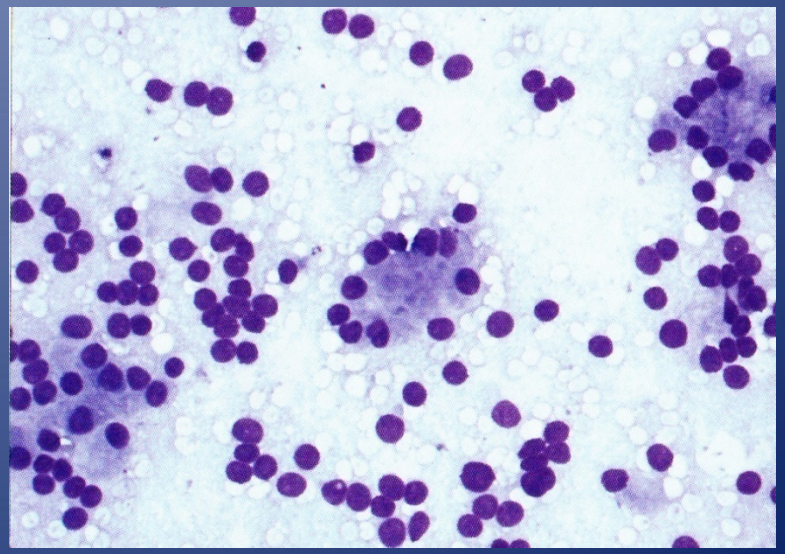

ACINAR CELL CARCINOMA

- **Cytological features**

  Neoplastic cells

  - Abundant granular cytoplasm with indistinct cell borders
  - Atypical central or eccentric nuclei with prominent nucleoli

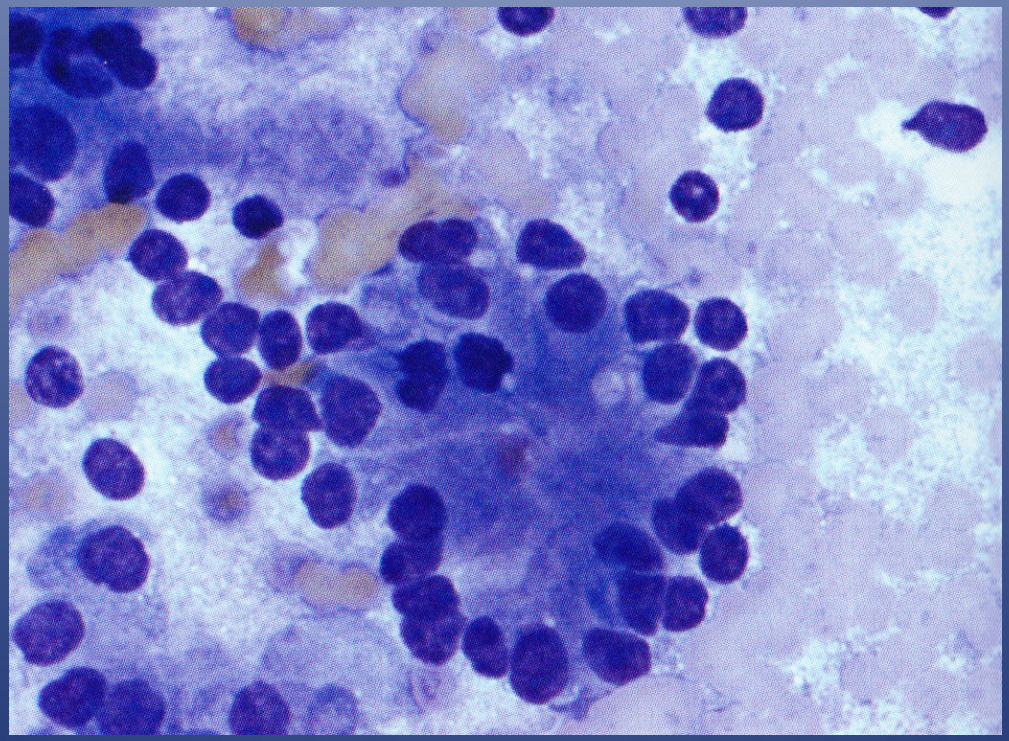

ACINAR CELL CARCINOMA

- **Differential diagnosis**
  - Pancreatic endocrine tumour
    - Rosette formation
    - Smaller cells with scant cytoplasm
    - « plasmacytoid appearance »
    - Salt and pepper chromatin
  - Solid-pseudo papillary neoplasm
    - Cytoplasmic hyaline globules, PASD+
    - Branching papillary clusters
    - Myxoid stroma
  - Pancreatoblastoma
    - Two cell population
      - Primitive epithelial cells
      - Stromal cells
  - Normal pancreatic parenchyma
    - Mixture of acini and ductal elements
    - Acini in small grapelike clusters
  - Ductal adenocarcinoma (undifferentiated variety)

ACINAR CELL CARCINOMA

Ancillary testing

- **Reactive**
  - Pancytokeratin
  - Chymotrypsin
  - Alpha-1-antichymotrypsin
  - Alpha-1-antitrypsin
  - Lipase
  - Trypsin
- **Non reactive**
  - CD56
  - Synaptophysin
  - Chromogranin A
  - Vimentin

PANCREATOBLASTOMA

- 0.5% of epithelial tumours
- Children ≤ 10 years of age
- Slight male predominance

PANCREATOBLASTOMA

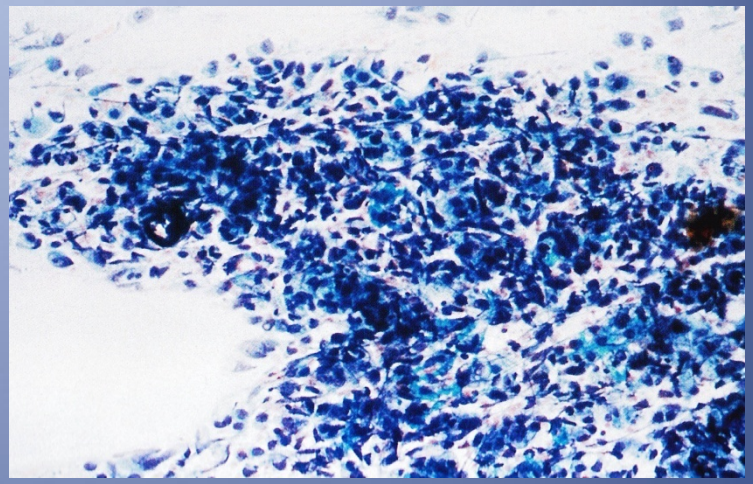

- **Cytological features**
  - Cellular aspirate
  - Biphasic population
    - Epithelial cells
      - Tree-dimensional syncitial groups of pleomorphic cells
      - Acinar structures with abundant cytoplasm and prominent nucleoli
      - Squamoid corpuscles

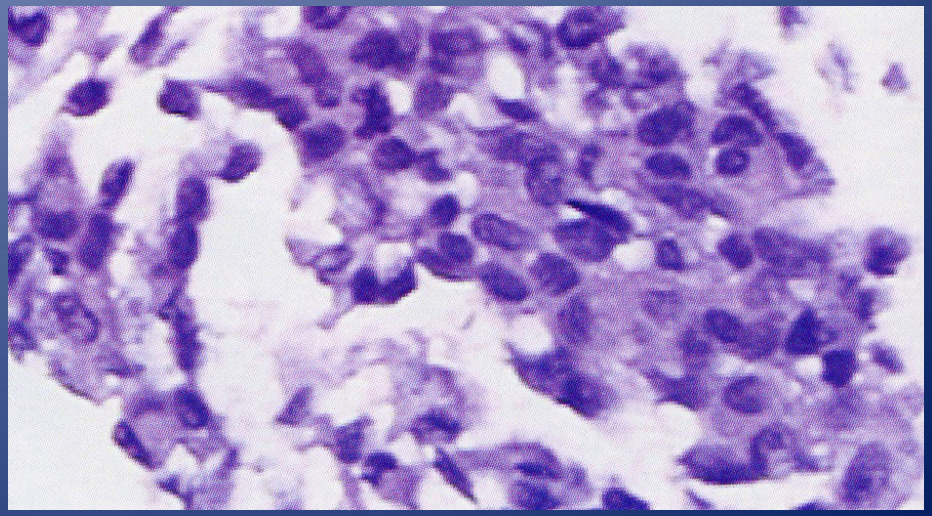

PANCREATOBLASTOMA

- **Cytological features**
  - Biphasic population
    - Stromal component
      - Primitive spindle-shaped cells
      - Heterologous stroma (cartilage)

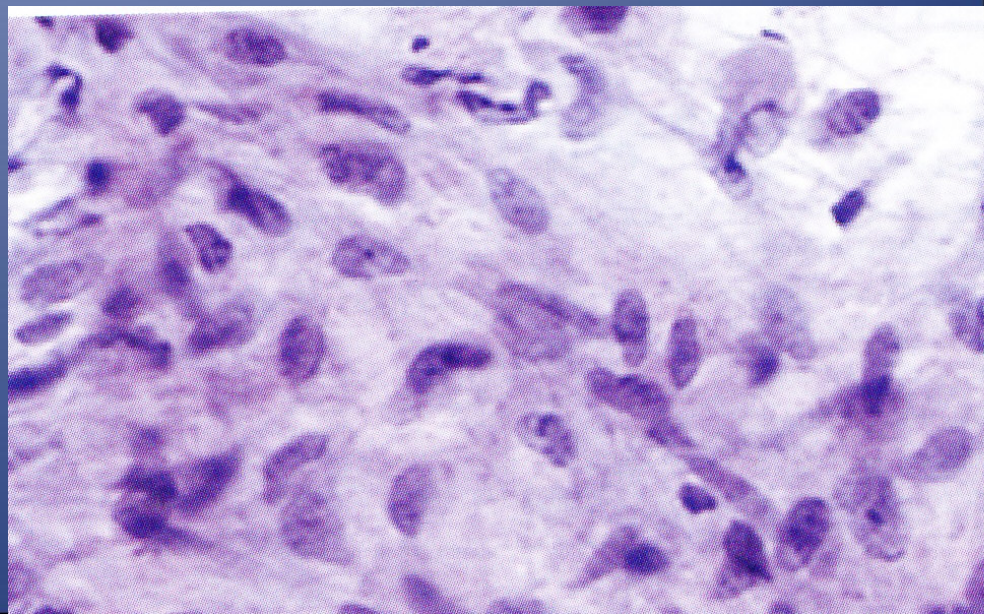

PANCREATOBLASTOMA

- **Differential diagnosis**
  - Primary pancreatic neoplasms
    - Pancreatic ductal carcinoma
    - Solid pseudopapillary neoplasm
    - Pancreatic endocrine tumour
    - Acinar cell carcinoma
  - Childhood malignancies
    - Wilms tumor
    - Neuroblastoma
    - Malignant lymphoma
    - Other

PANCREATOBLASTOMA

- **Ancillary testing**
  - Diffusely positive
    - CAM5.2
    - Lipase
    - Trypsin
    - Chymotrypsin
    - Alpha-1-antitrypsin
  - Sometimes positive
    - αFP
    - CEA
    - Ca19-9
  - Scattered cells positive
    - Chromogranin A
    - Synaptophysin

SOLID-PSEUDOPAPILLARY NEOPLASM

- Solid-cystic tumour
- 1% of all exocrine pancreatic neoplasms
- Predominant in adolescent girls and young women
- Low malignant potential

SOLID-PSEUDOPAPILLARY NEOPLASM

- **Cytological features**
  - Highly cellular aspirate showing relative uniform cell population
  - Single cells
  - Loose clusters
  - Branching papillary tissue with central capillary



SOLID-PSEUDOPAPILLARY NEOPLASM

- **Cytological features**
  - Monotonous bland cells
  - Scant ill-defined, vacuolated amphophilic cytoplasm
    - Occasionally PAS+
    - Granules or vacuolisation Round to oval nuclei
    - Clefted nuclei or nuclear grooves
  - Myxoid and metachromatic stroma and background
  - Rare necrotic debris (areas of cystic degeneration)

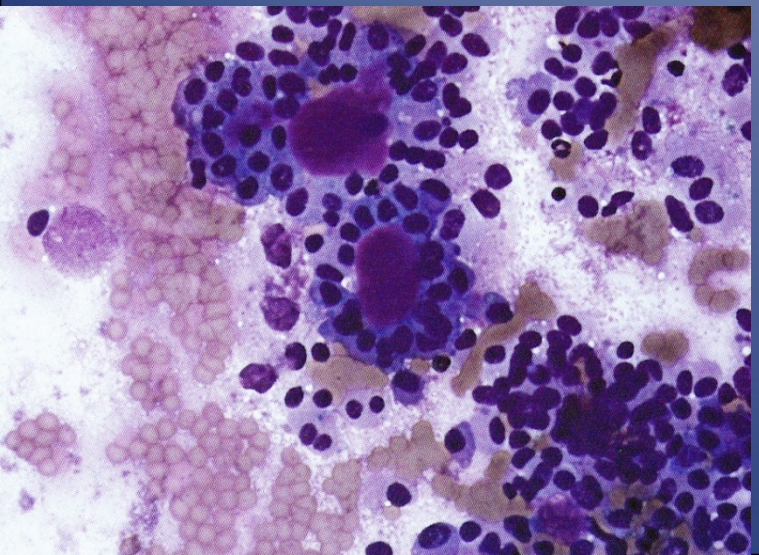

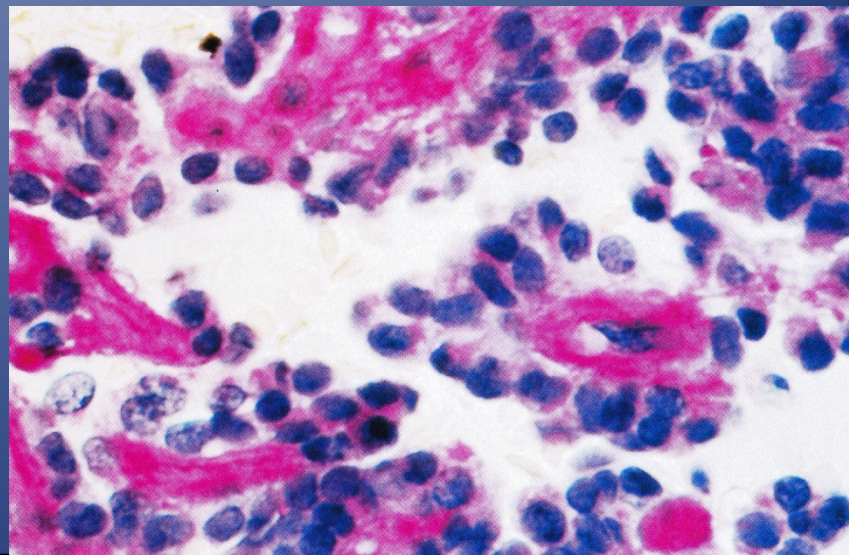

SOLID-PSEUDOPAPILLARY NEOPLASM

- **Differential diagnosis**
  - Uniform cells
    - Pancreatic endocrine tumour
    - Acinar cell carcinoma
    - Pancreatoblastoma
  - Cystic lesion with papillae
    - Intraductal papillary mucinous neoplasm

SOLID-PSEUDOPAPILLARY NEOPLASM
Ancillary testing

- Reactive
  - Vimentin
  - NSE
  - Progeterone receptor
  - B-catenin
  - Alpha-1-antitrypsin
  - Alpha-1-antichymotrypsin
  - CD10
  - CD56
- No reactive
  - Cytokeratin
  - Chromogranin A
  - CEA
  - Ca19-9
  - Synaptophysin
  - Trypsin
  - Chymotrypsin
  - Amylase
  - Estrogen receptor

PANCREATIC ENDOCRINE TUMORS

- Diagnosed in 1/100000 people
- 2% of pancreatic neoplasms
- 2 major types
  - 60-85% functioning tumour: with clinical syndrome directly related to a hormone, secreted by the tumour
  - 20-40% non functioning tumour: incidentaloma or pancreatic mass
- Any age (more common in older adults)
- No sex predilection
- Tail>>>> head
- 20% are calcified
- Association with
  - MENI
  - Von Hippel Lindau syndrome

PANCREATIC ENDOCRINE TUMORS

- **cytological features**
  - Cellular aspirate
  - Monotonous extremely dyshesive cell population
  - Loosely cohesive cell groups
  - Rosette or pseudo rosette formation



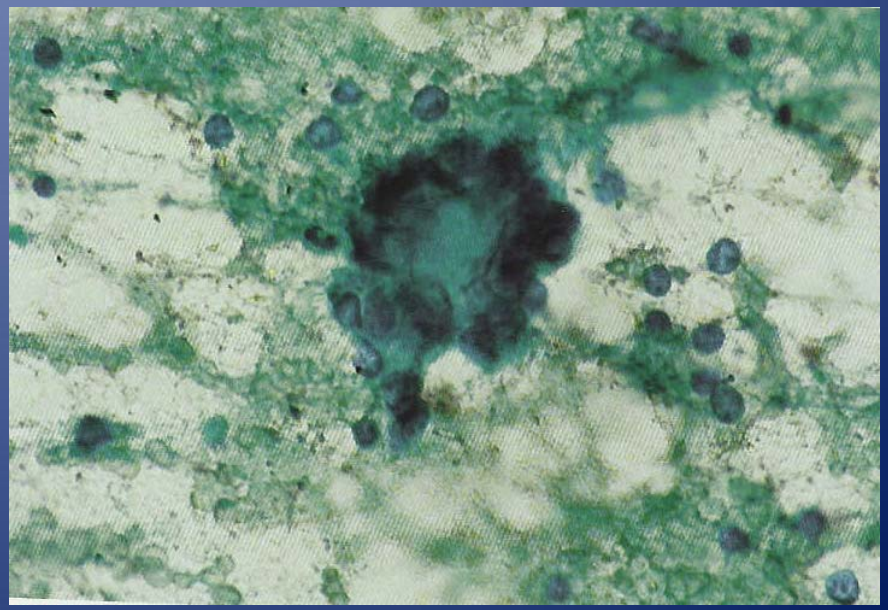

PANCREATIC ENDOCRINE TUMORS

cytological features

- Relative uniform round to polygonal cells
- Plasmacytoid cells
- Delicate, granular amphophilic or basophilic cytoplasm
- Round to oval nuclei, eccentrically located
- Salt and pepper chromatin
- Small inconspicuous nucleoli

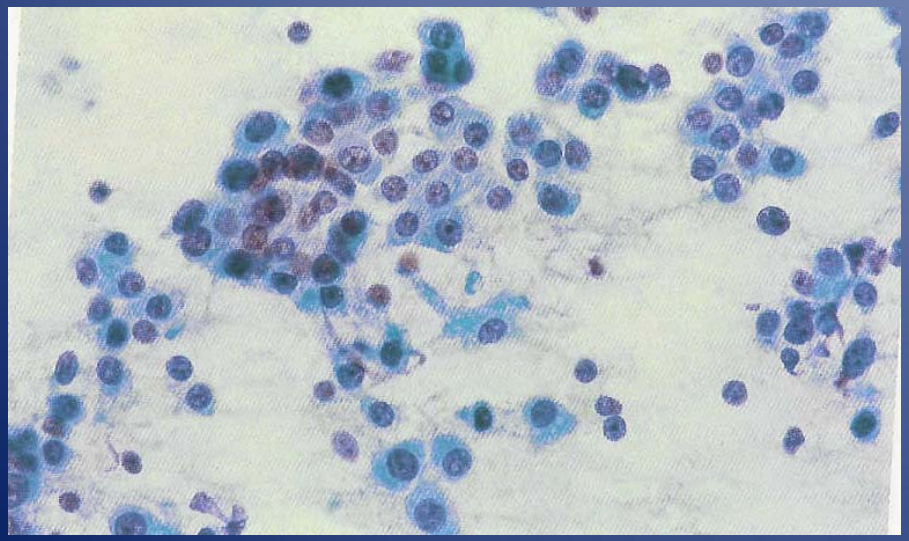

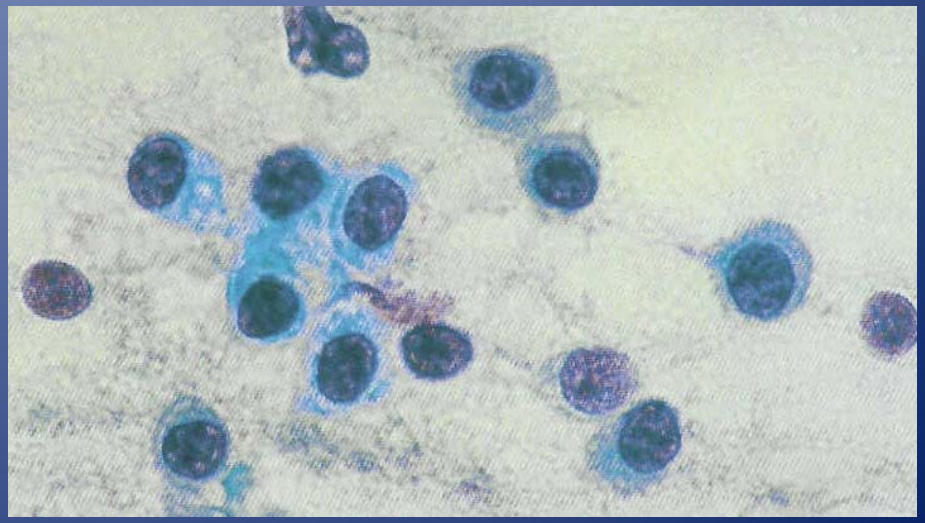

PANCREATIC ENDOCRINE TUMORS

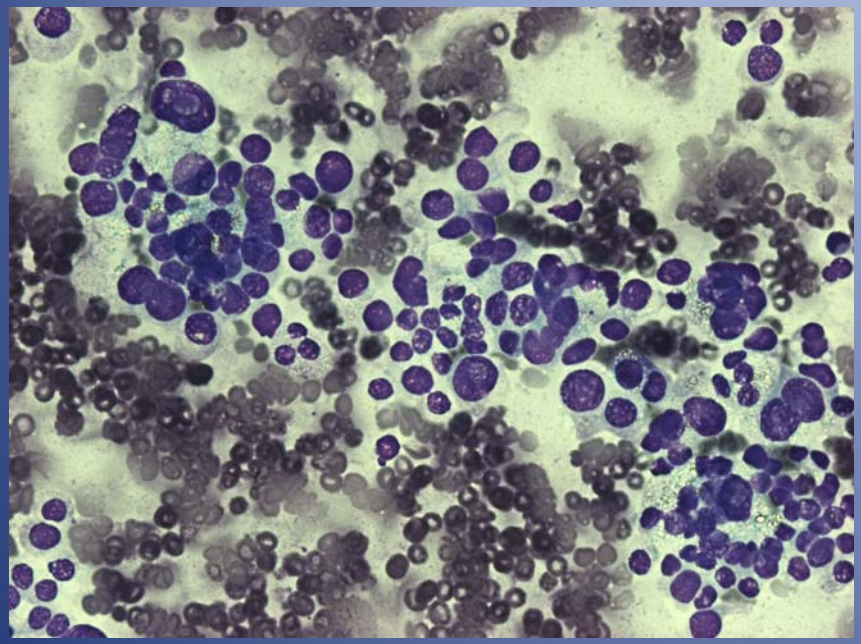

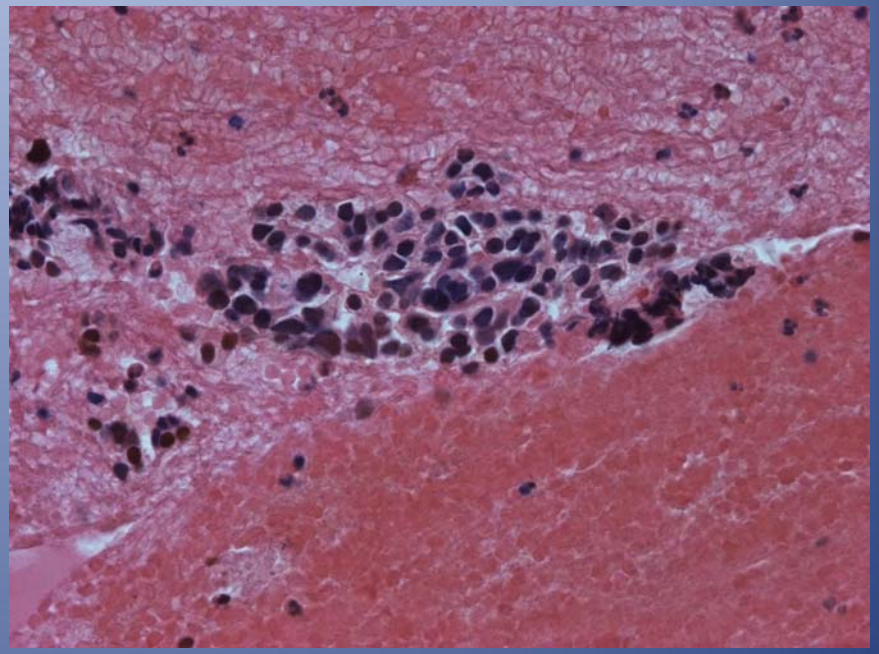

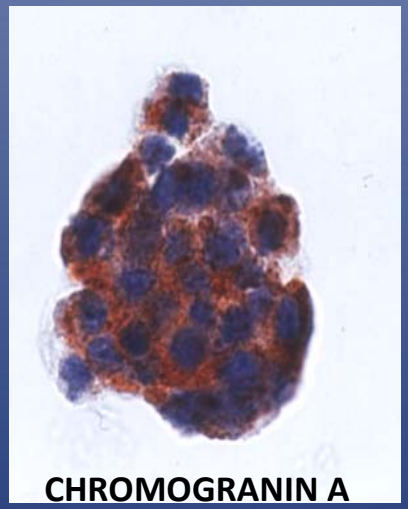

CHROMOGRANIN A

PANCREATIC ENDOCRINE TUMORS

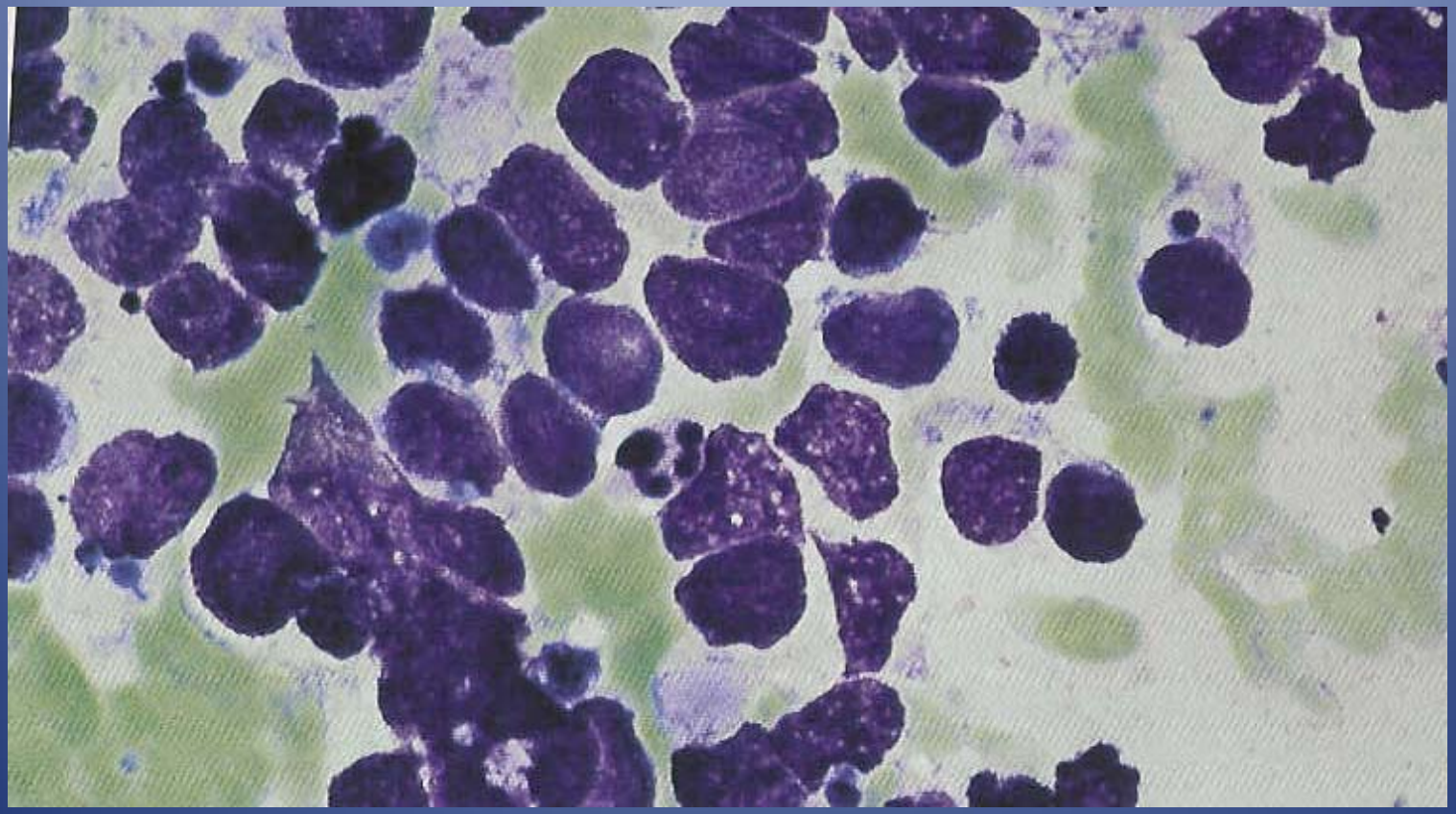

PANCREATIC ENDOCRINE TUMORS

- **Ancillary testing**
- For diagnosis
  - Chromogranin A
  - Synaptophysin
  - Mib 1
- For differential diagnoses
  - Cytokeratin
  - MUC 1
  - CD 45…

PANCREATIC ENDOCRINE TUMORS

- **Less frequent cytological features**
  - Predominantly single cells
  - Diff-quick: Fine red cytoplasmic granules
  -
  - Bi and multinucleation ≠ malignancy
  - Nuclear pleomorphism ≠ malignancy
  - Mitotic figures = suggests aggressive course
  - Naked nuclei
  - Necrotic debris = suggests aggressive course
  - Calcification
  - Amyloid deposition
  - Thin capillaries

II CYSTIC LESIONS OF THE PANCREAS

PSEUDOCYST

↕

CYSTIC MUCUS-PRODUCING NEOPLASIA

CYSTIC LESIONS OF THE PANCREAS

- **Congenital cyst**
  - Simple or solitary true cyst
  - Polycystic diseases
  - Cystic fibrosis
  - Enteric duplication cysts
  - Biliary and pancreatic duct anomalies
  - Dermoid cyst
  - Lympho epithelial cysts
- **Miscellaneous cyst**
  - Nutritional (tropical) fibrocalcic pancreatitis
  - Extra pancreatic cysts
- **Retention cyst**
  - Post obstructive
    - < pancreatic cancer
    - < pancreatic lithiasis
    - < cholelithiasis, cholecystitis
    - < parasitic infections
      - < amebic, clonorchis *sinensis, Ascaris lumbricoides*
- **Infectious cyst**
  - Secondary pancreatic infection
  - Hydatid cyst
  - Giardia

CYSTIC LESIONS OF THE PANCREAS

- **Pseudocyst**
  - Postinflammatory
  - Post-traumatic
  - Postchirurgical
  - Congenital

- **Cystic neoplasms**
  - **Serous**
    - Serous cystadenoma
  - **Mucinous**
    - Mucinous cystadenoma
    - Mucinous cystadenocarcinoma
    - Intraductal papillary mucinous neoplasm
  - **Vascular**
    - Lymphangioma
    - Hemangioma
  - Solid pseudopapillary tumour
  - Cystic pancreatic endocrine tumour
  - Ductal carcinoma with cystic degeneration
  - Acinar cell cystadenoma carcinoma

PRAGMATIC APPROACH

- Imaging data
- Identification of mucus < right clinical context
- **Chemical analysis of pancreatic cyst fluid**
  - **Amylase <250U/L**
    - Serous cystadenoma and mucinous neoplasm
  - **CEA< 250ng/mL**
    - Serous cystadenoma and pseudocyst
  - **CEA>800ng/mL**
    - Mucinous neoplasm
  - **Ca19-9<36U/mL**
    - Serous cysadenoma and pseudocyst

PSEUDOCYST

- Most common cystic lesion (75-90%)
- Cavities
  - < lysis tissue after leakage of pancreatic enzyme
  - DD retention cyst < dilatation of the pancreatic duct system
- Often known histories of chronic pancreatitis
  - < alcoholism
  - < biliary lithiasis
- Intra-extrapancreatic
- Unique/multiple
- Unilocular
  - May connect with the pancreatic duct
- Cyst fluid
  - CEA< 250ng/mL
  - Ca19-9<36U/mL

PSEUDOCYST

- **Cytological features**
  - Red brown fluid
  - Variable inflammatory cells
  - Hemosiderin-laden macrophages
  - Background
    - Blood, granular debris
    - Occasionally bile pigment
  - No cyst lining-epithelium
  - Normal pancreatic components and fibroblasts

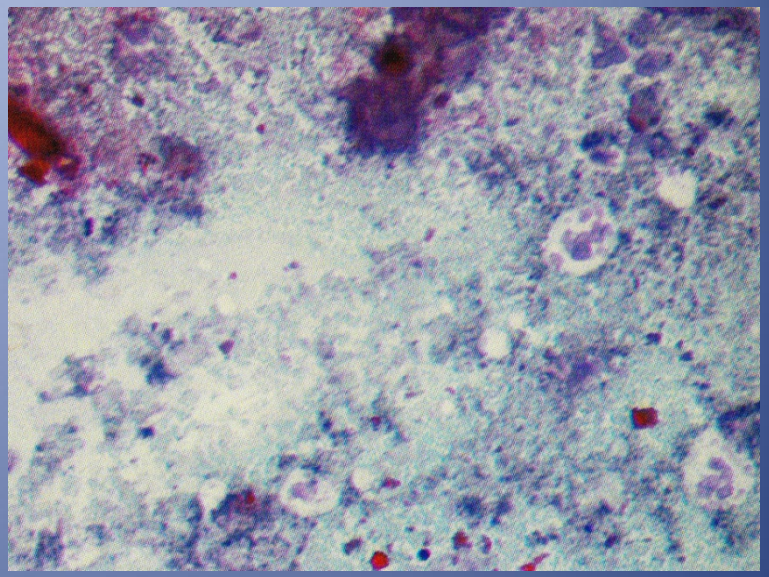

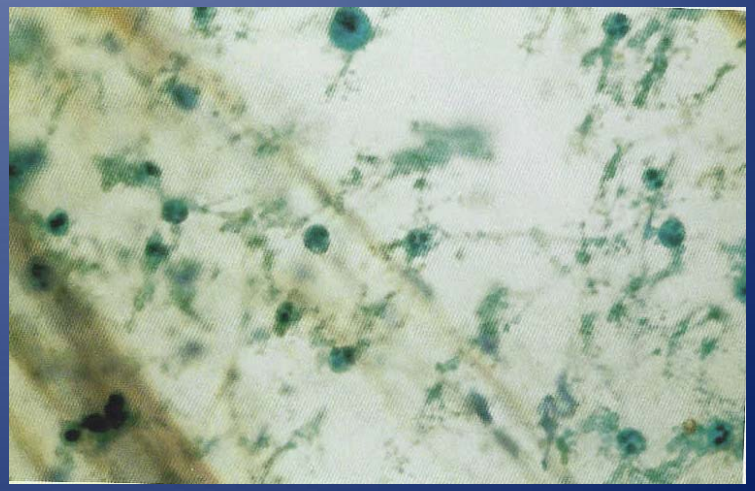

PSEUDOCYST

- Epithelial cells
  - < Chronic pancreatitis
  - < Contaminant

Mucinous epithelium ≠ contaminant
Background mucin
Mucin-containing histiocytes

⇓

Excludes the diagnosis

CYSTIC MUCUS-PRODUCING NEOPLASIA

- **Diagnostic approach**
  - 10% EUS-FNA < 10% cystic lesion of the pancreas < 1% malignancy
  - Presence of thick, extracellular mucus strongly favour the diagnosis
    - < gelatinous and sticky material often difficult to smear
    - Mucus < mucus producing neoplasia thicker < gastrointestinal epithelium
  - Amylase < 250 U/L
  - CEA > 800ng/mL
  - The accurate sub classification may not be always possible

⇨ **Descriptive interpretation**

CYSTIC MUCUS-PRODUCING NEOPLASIA

- **MUCUS**
  - < gelatinous and sticky material often difficult to smear
  - Mucus < mucus producing neoplasia thicker < gastrointestinal epithelium
  - **Diff-Quick**: purple or metachromatic
  - Papanicolaou: more variable from greenish-blue to orangophilic

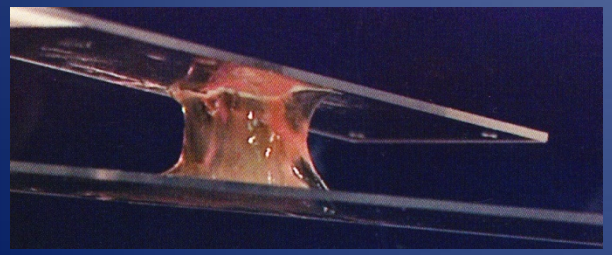

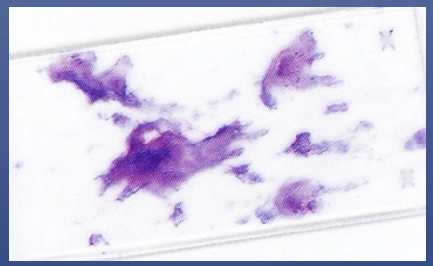

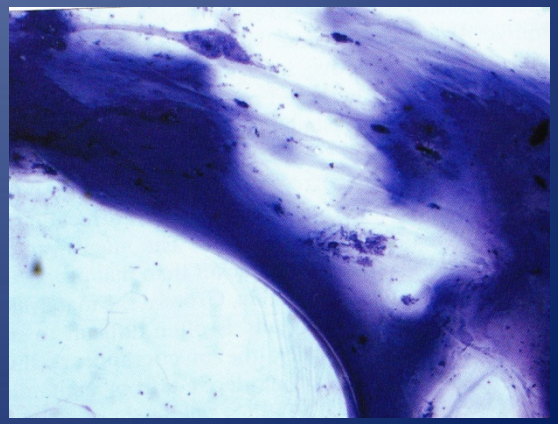

INTRADUCTAL PAPILLARY MUCINOUS NEOPLASMS

- Both sexes

- Elderly patients <main duct type
  - Younger < branch duct type

- History of recurrent acute pancreatitis
- History of chronic obstructive pancreatitis

- Clear connection between the cyst and the pancreatic duct system

- Throughout the pancreas
  - Mostly head < main duct type
  - uncinate process < branch duct type

- FNA ⇨ Smaller lesions < branch duct type
- FNA < Sendai consensus guidelines

INTRADUCTAL PAPILLARY MUCINOUS NEOPLASMS

- **Cytological features**
  - « As varied as the histological findings »
  - Overlapping mucinous cystic neoplasm

INTRADUCTAL PAPILLARY MUCINOUS NEOPLASMS

- **Cytological features**
  - Extracellular material
    - Thick, viscous mucus
    - Entrapped inflammatory cells
    - Necrotic debris (higher grade lesion)
  - Cellularity
    - Variable raised in high grade and invasive lesions
  - Variable degrees of cytological atypia
    - Sheets of epithelium < low grade lesions
    - Three-dimensional clusters < high grade lesions
  - Papillary groups
  - Gastric or pancreatobillary differentiation < low grade lesions
  - Intestinal differentiation < high grade lesions

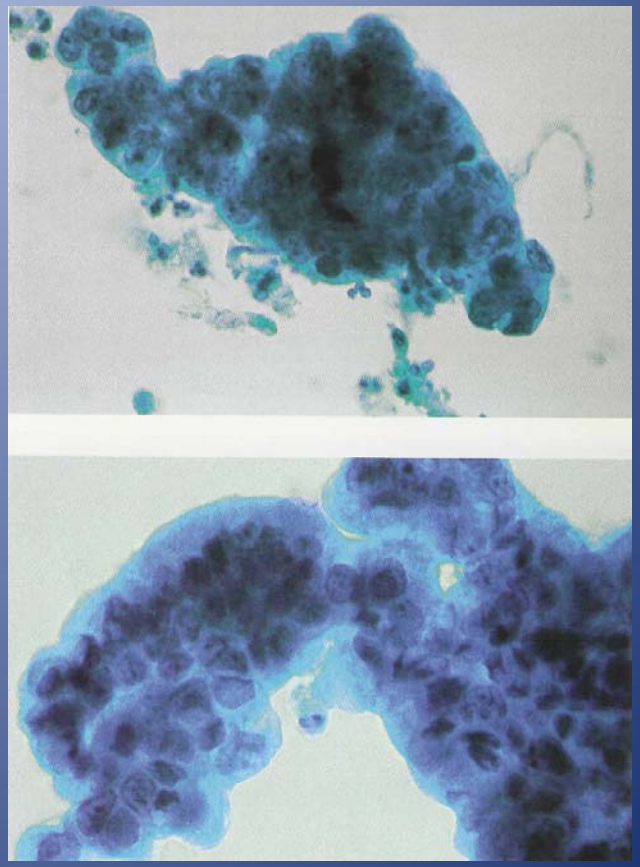

INTRADUCTAL PAPILLARY MUCINOUS NEOPLASMS

- Ancillary

MUCINOUS CYSTIC NEOPLASMS

- Less common than IPMN
- Middle-aged woman
- Body and tail of the pancreas
- Multioculated cysts
- No connection with the pancreatic duct system
- Ovarian-type stroma

MUCINOUS CYSTIC NEOPLASMS

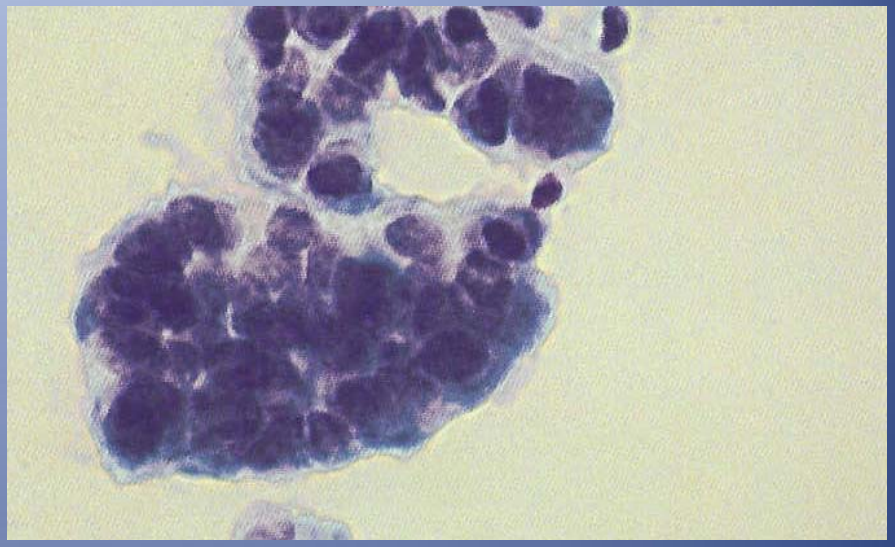

- **Cytological features**
  - Extracellular material
    - Thick, viscous mucus
    - Entrapped inflammatory cells
    - Necrotic debris (higher grade lesion)
  - Cellularity
    - Variable raised in high grade and invasive lesions
  - Variable degrees of cytological atypia
    - Sheets of epithelium < low grade lesions
    - Three-dimensional clusters < high grade lesions

DIFFERENTIAL DIAGNOSIS AND PITFALLS

- **MCN-IPMN**

- **Mucus**
  - Thick
  - Metachromatic
  - Entrapped inflammatory cells
  - Necrotic debris
  - Individual or groups of tumour cells

- **BENIGN GASTRIC AND INTESTINAL CONTAMINANT**

- **Mucus**
  - Thin
  - Few inflammatory cells
  - Occasional entrapped groups of benign gastric or intestinal epithelium

- Cytomorphology
  - « honeycomb »pattern

SEROUS CYSTADENOMA

- Almost universally benign
- Tail
- Micro or macrocystic
  - < according the size of their cysts
  - Similar cytological findings
- Woman > man
- Classic radiologic features
  - Central scar
  - Multiloculated cyst
- Cyst fluid
  - Amylase <250U/L
  - CEA< 250ng/mL
  - Ca19-9<36U/mL

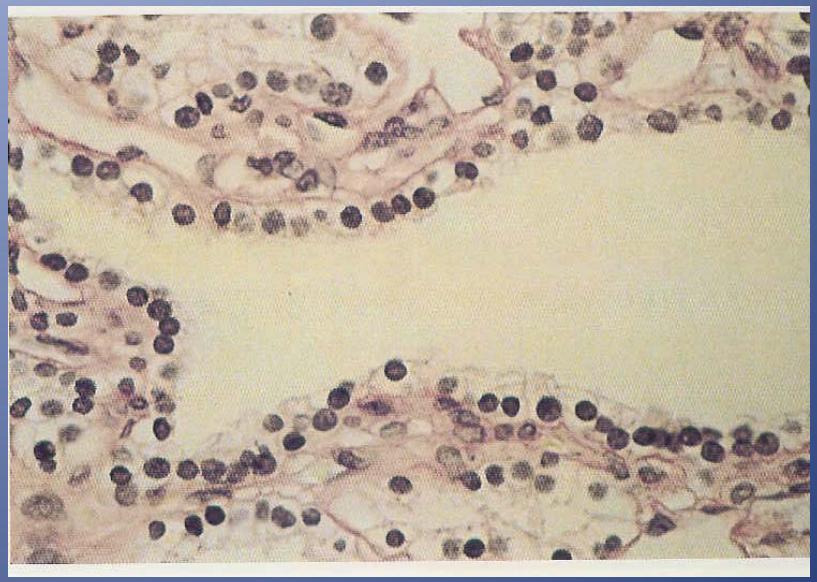

SEROUS CYSTADENOMA

- **Cytological features**
  - Scant cellularity
    - Non diagnostic interpretation
  - Watery fluid
  - Proteinaceous or bloody background
  - Monolayered sheets
  - Small, flat clusters
  - Homogeneous, bland, round nuclei
  - Clear cytoplasm with well-defined borders
  - Cytoplasmic glycogen (PAS-PASD)

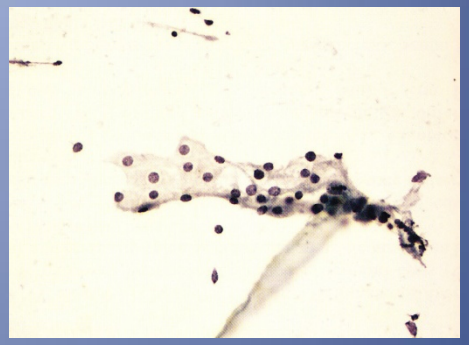

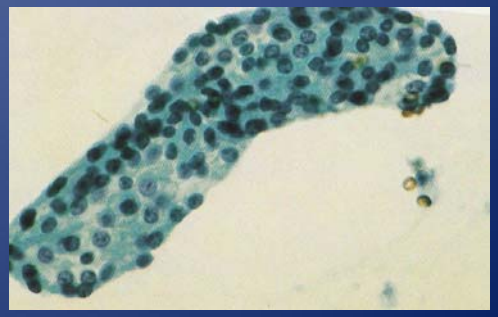

SEROUS CYSTADENOMA

- **Differential diagnosis**
  - Benign pancreatic ductal and acinar epithelium
  - Mesothelial cells
  - Cystic pancreatic endocrine tumour
  - Endothelium neoplasm (hemangioma)
  - Mucinous cystic neoplasm